

**PATIENT**

Cooper Bleaney

**SPECIES**

Canine

**BREED**

Springer Spaniel

**SEX**

MN

**AGE**

7 Years, 2 Months

**INTERPRETED BY**Nele Eley, DVM  
Dr. med. Vet. DipECVDI**HOSPITAL NAME**Westview Veterinary  
Hospital**REFERRING VET**

Dr Brian Barnes

**INVOICE**

56317

**DATE**

1-23-23

**PRESENTING CLINICAL SIGNS**

Resubmit images as would not up load. History on original submission Had TTA s on Sept 13, 2022 left knee, the CCL had a partial tear with about 3/4 of he ligament still intact The damage portion of the Cranial cruciate ligament was debrided. The bulk of the CCL was left in situ The meniscus appeared normal at the time of surgery with no folding or tears that were noted. Also a pre sx U/S of the left knee showed that the lateral and medial meniscus appeared normal in situ with a smoothly delineated surface and with normal uniform internal echoarchitecture Dog slipped and fell and injured the left knee around Oct 19, 2022. Was very lame and was xrayed at that time and the implants were all intact. The dog was rested and placed ion Nsaids and Tramadol

Abnormal PE/Chem/CBC/UA Results: Revision Sx on TTA , Left medial meniscal removal. Joint effusion, mild DJD/OA, Thickened joint capsule, Cr drawer , no CTT

**ULTRASONOGRAPHIC FINDINGS****Left Stifle**

The patient has a history of cruciate ligament injury and TTA in September 2022 with recurring lameness.

Severe effusion is seen within the supra- and infra-patellar recesses of the left stifle joint. Regularly sized echogenic debris is seen within the joint fluid. Severe swelling of the synovium with synovial proliferations is noted. Concave surface irregularity of the caudal horn of the medial meniscus is noted as well as a vertical hypoechoic line intersecting the heterogeneous meniscal tissue.

**ULTRASONOGRAPHIC DIAGNOSIS**

- Suspect medial meniscal injury with severe synovitis and effusion of the left stifle joint.

**INTERPRETATION OF THE FINDINGS & FURTHER RECOMMENDATIONS**

The ultrasonographic findings strongly support the presence of injury of the caudal horn of the medial meniscus in the left stifle which appears to be concurred by severe inflammation with synovitis and effusion within the left stifle joint.



**PATIENT**

Cooper Bleaney

**SPECIES**

Canine

**BREED**

Springer Spaniel

**SEX**

MN

**AGE**

7 Years, 2 Months

**INTERPRETED BY**

Nele Eley, DVM  
Dr. med. Vet. DipECVDI

**HOSPITAL NAME**

Westview Veterinary  
Hospital

**REFERRING VET**

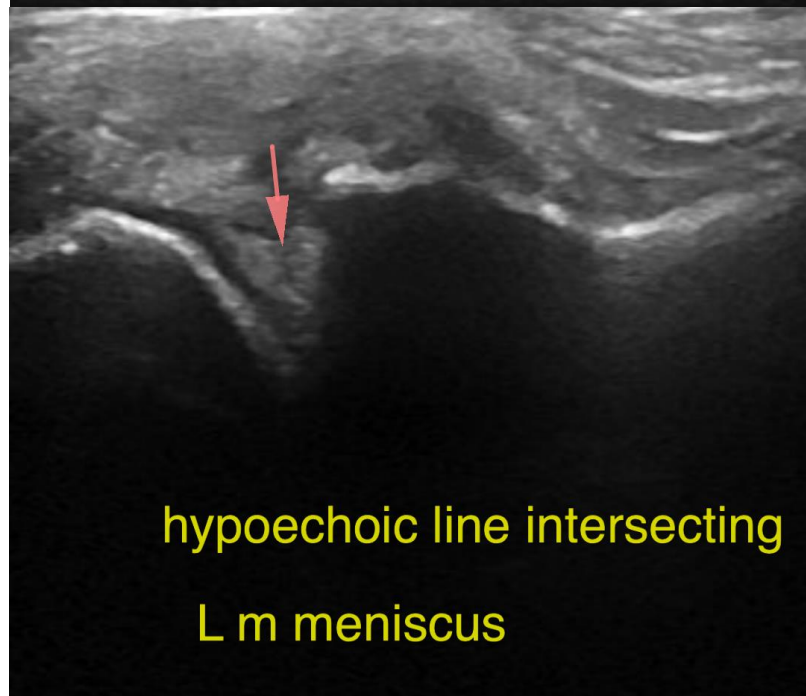
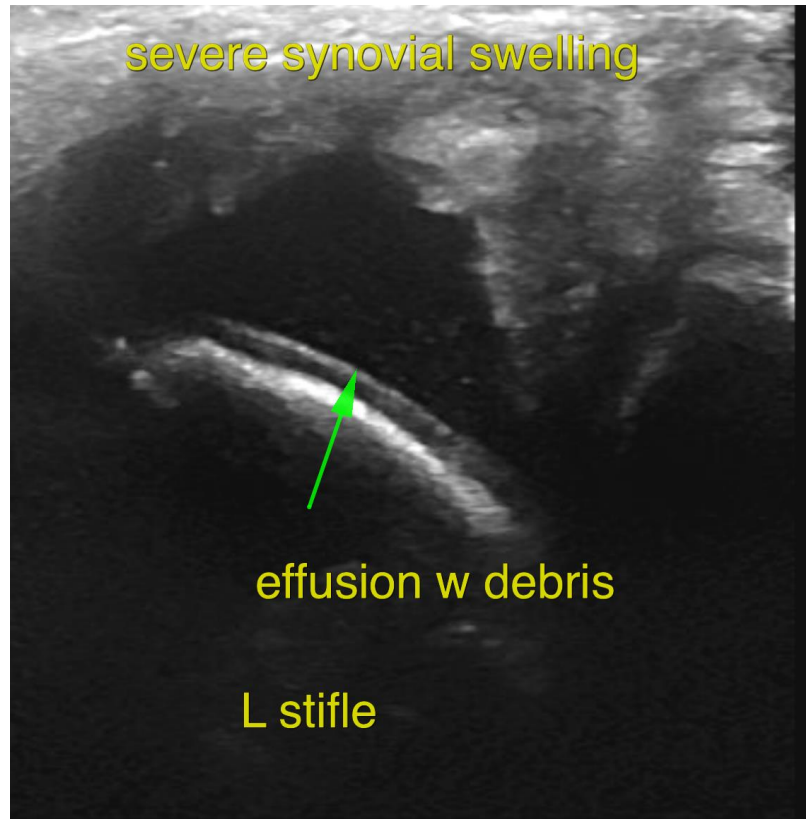
Dr Brian Barnes

**INVOICE**

56317

**DATE**

1-23-23





**PATIENT**

Cooper Bleaney

**SPECIES**

Canine

**BREED**

Springer Spaniel

**SEX**

MN

**AGE**

7 Years, 2 Months

**INTERPRETED BY**

Nele Eley, DVM  
Dr. med. Vet. DipECVDI

**HOSPITAL NAME**

Westview Veterinary  
Hospital

**REFERRING VET**

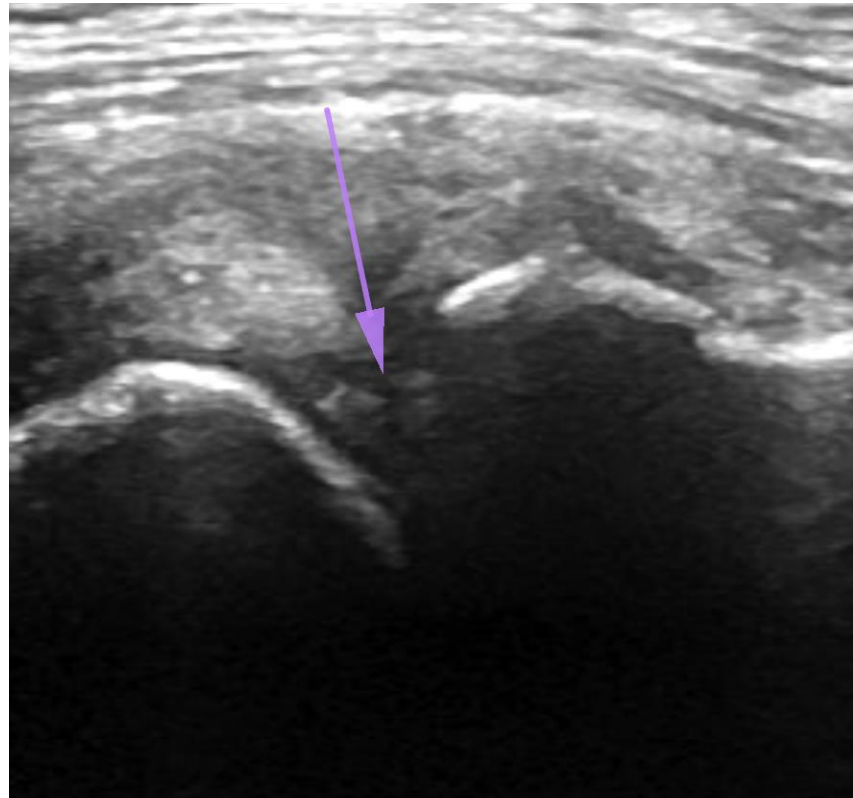
Dr Brian Barnes

**INVOICE**

56317

**DATE**

1-23-23



The information and recommendations provided are based on the images presented by the referring veterinarian/sonographer. No evaluation can be communicated regarding pathology that was not visible in the image/video clips provided.

Thank you for this referral. If the clinical or image interpretation does not parallel your findings or if I can be of any further assistance please contact me.

**Nele Eley**, DVM, Dr. med. vet., DipECVDI  
European Specialist in Veterinary Diagnostic Imaging, Cert. Radiology,  
Senior lecturer University of Giessen, Germany, Veterinary Faculty, Department of Radiology  
Nele.Eley@sonopath.com