



PATIENT

Juve Vito

PRESENTING CLINICAL SIGNS

severe swelling in submandibular LN L prescapular LN enlarged inguinal LN- L enlarged gr 1 heart murmur
 Abnormal PE/Chem/CBC/UA Results: elevation of liver enzymes and cytology confirmed lymphoma

SPECIES

Canine

RADIOGRAPHIC STUDY OF THE THORAX & ABDOMEN

Right/left lateral and ventrodorsal views of the thorax and lateral and ventrodorsal views of the abdomen totaling 6 images available for review.

BREED

Coton De Tuleur

RADIOGRAPHIC FINDINGS

Thorax

SEX

Male

Extensive retropharyngeal soft tissue swelling pushing the larynx and trachea ventrally is seen. Course and width of the trachea are otherwise considered within normal limits.

There is no evidence of cardiomegaly. The vertebral heart score is 9.2.

AGE

15 Years

No evidence of pulmonary metastatic disease is seen.

There is no evidence of pathologic mediastinal widening.

INTERPRETED BY

Nele Eley, DVM
 Dr. med. Vet. DipECVDI

Abdomen

Mild generalized enlargement of the liver is seen as well as splenomegaly.

There also is the subjective impression of generalized small intestinal wall thickening which, however, cannot be ascertained based on radiographs.

Multiple small round calculi superimpose onto the liver in the position of the gallbladder.

HOSPITAL NAME

Truscott Animal
 Hospital

RADIOGRAPHIC DIAGNOSIS

REFERRING VET

Dr. Erini Abraham

- Suspect severe retropharyngeal lymphadenomegaly.
- Radiographically normal thorax.
- Suspect biliary lithiasis associated with the gallbladder.
- Hepatosplenomegaly.
- Suspect generalized small intestinal wall thickening.

INVOICE

49764

INTERPRETATION OF THE FINDINGS & FURTHER RECOMMENDATIONS

The radiographic findings parallel the history of lymphoma. Based on the radiographs, the retropharyngeal lymph nodes, liver, and spleen appear to be involved. Consider also the potential of a diffuse small intestinal wall infiltrate and correlate with the ultrasonographic findings.

DATE

1-22-22



PATIENT

Juve Vito

SPECIES

Canine

BREED

Coton De Tuleur

SEX

Male

AGE

15 Years

INTERPRETED BY

Nele Eley, DVM
Dr. med. Vet. DipECVDI

HOSPITAL NAME

Truscott Animal
Hospital

REFERRING VET

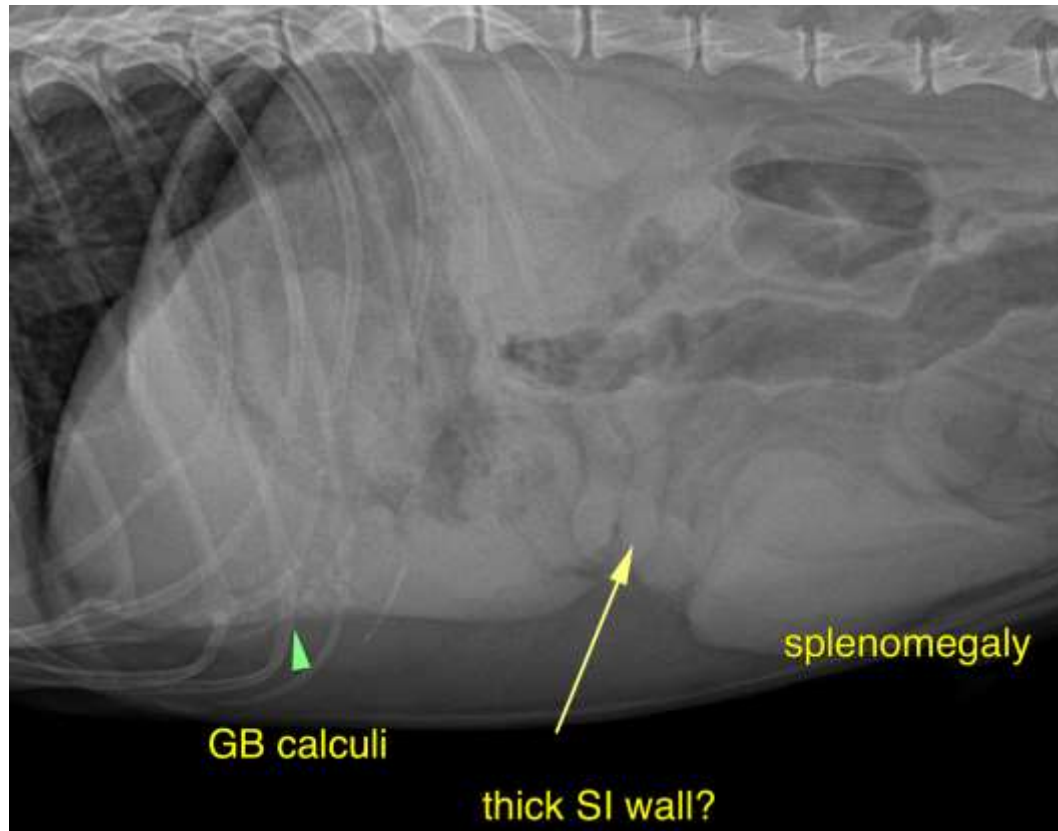
Dr. Erini Abraham

INVOICE

49764

DATE

1-22-22



The information and recommendations provided are based on the images presented by the referring veterinarian/sonographer. No evaluation can be communicated regarding pathology that was not visible in the image/video clips provided.

Thank you for this referral. If the clinical or image interpretation does not parallel your findings or if I can be of any further assistance please contact me.

Nele Eley, DVM, Dr. med. vet., DipECVDI
European Specialist in Veterinary Diagnostic Imaging, Cert. Radiology,
Senior lecturer University of Giessen, Germany, Veterinary Faculty, Department of Radiology
Nele.Eley@sonopath.com