



PATIENT

Sarimo Valinote

PRESENTING CLINICAL SIGNS

Coughing Currently on Lasix, Enalapril, Plavix and Methamizole
Abnormal PE/Chem/CBC/UA Results: WNL

SPECIES

Feline

RADIOGRAPHIC STUDY OF THE THORAX

Single right lateral view of the thorax available for review.

BREED

American Shorthair

RADIOGRAPHIC FINDINGS

The patient is in thin body condition.

The degree of pulmonary inflation is deep. The ribcage is expanded. The lumbodiaphragmatic angles are wide. The diaphragmatic cupola is flat.

SEX

Male Neutered

The lung field is hyperlucent with a mild generalized bronchial lung pattern and bronchial wall mineralization. No evidence of a vascular lung pattern and no cardiogenic pulmonary edema is seen.

AGE

20 Years

There is moderate generalized enlargement of the cardiac silhouette with a vertebral heart score of 9.8, reference range up to 8.5.

RADIOGRAPHIC DIAGNOSIS

- Moderate cardiomegaly
- Generalized bronchial lung pattern with air trapping.

INTERPRETED BY

Nele Eley, DVM
Dr. med. Vet. DipECVDI

INTERPRETATION OF THE FINDINGS & FURTHER RECOMMENDATIONS

HOSPITAL NAME

New Bridge
Veterinary Practice

The radiographic study confirms presence of cardiac pathology with cardiomegaly. The cardiac size exceeds the reference range of 8.5 with a vertebral heart score of 9.8. At this time, however, there is no radiographic evidence of congestive heart failure under the medication mentioned in the patient history.

The bronchial lung pattern may be age related. However, underlying chronic lower airway disease such as allergic lower airway syndrome (feline asthma) or less likely infectious bronchitis including viral, bacterial, or parasitic cannot be ruled out to be present concurrently.

REFERRING VET

Dr. Abina Glennon

A cardiac echo and a clinical trial of treatment for feline asthma could be considered.

INVOICE

56302

DATE

1-21-23



PATIENT

Sarimo Valinote

SPECIES

Feline

BREED

American Shorthair

SEX

Male Neutered

AGE

20 Years

INTERPRETED BY

Nele Eley, DVM
Dr. med. Vet. DipECVDI

HOSPITAL NAME

New Bridge
Veterinary Practice

REFERRING VET

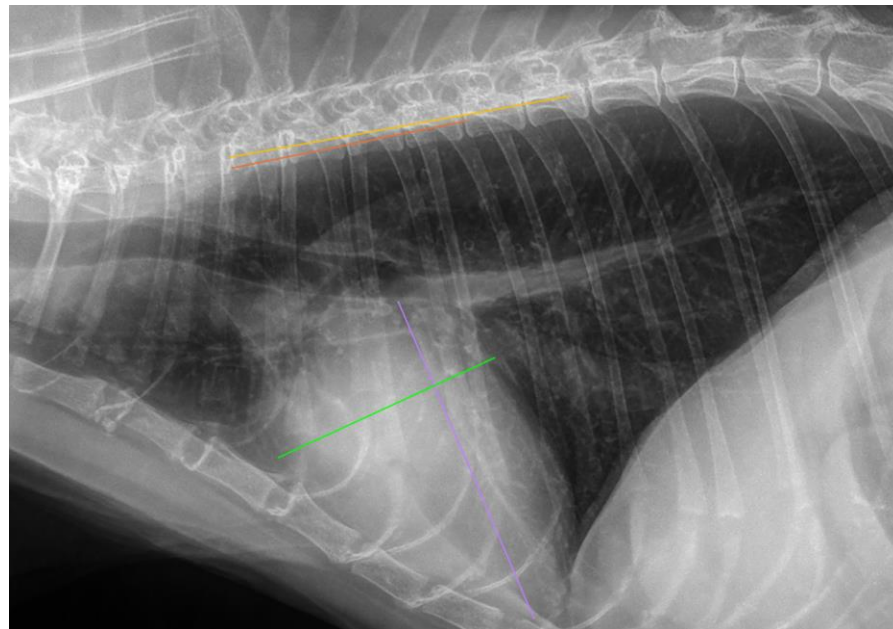
Dr. Abina Glennon

INVOICE

56302

DATE

1-21-23



The information and recommendations provided are based on the images presented by the referring veterinarian/sonographer. No evaluation can be communicated regarding pathology that was not visible in the image/video clips provided.

Thank you for this referral. If the clinical or image interpretation does not parallel your findings or if I can be of any further assistance please contact me.

Nele Eley, DVM, Dr. med. vet., DipECVDI
European Specialist in Veterinary Diagnostic Imaging, Cert. Radiology,
Senior lecturer University of Giessen, Germany, Veterinary Faculty, Department of Radiology
Nele.Eley@sonopath.com