


PATIENT PRESENTING CLINICAL SIGNS

Kyle Dean Heavy and abdominal breathing started 4 days ago, getting worse today. No V/D/C Still eating OK Lethargic. No heart murmur detected. Tachycardia.
 Abnormal PE/Chem/CBC/UA Results: Blood work indicate mild decrease in K 3.2, otherwise unremarkable / normal. Normal T4 41.0 CBC normal

SPECIES

Feline

RADIOGRAPHIC STUDY OF THE THORAX & ABDOMEN

Right/left lateral and ventrodorsal whole body views totaling 3 images available for review.

BREED

DSH

RADIOGRAPHIC FINDINGS
Thorax

The ribcage is expanded. The intercostal spaces are diverging ventrally. Lumbodiaphragmatic angles are wide. Diaphragmatic cupola is flat.

SEX

Neutered Male

A moderate ventral alveolar infiltrate is seen with multifocal distribution accentuating the caudal subsegment of the left cranial lobe.

AGE

13 Years

There is no evidence of esophageal dilation. Mild esophageal aerophagia is noted.

Mild vascular engorgement is seen in the perihilar region. Course and width of the trachea are considered within normal limits. Mild perihilar and peribronchial cuffing is noted. There is no evidence of pleural effusion.

INTERPRETED BY

 Nele Eley (Ondreka),
 DVM Dr. med. vet.,
 DipECVDI

Assessment of the cardiac silhouette is obscured owing to the pulmonary infiltrate. However, no obvious atrial enlargement can be seen.

Abdomen

The surrounding bony structures are within normal limits.

HOSPITAL NAME

St. Catharine's AH

No abnormalities of the extra-abdominal soft tissues are noted. The abdominal wall is smooth and thin.

The serosal detail is maintained throughout the peritoneal and retroperitoneal space.

REFERRING VET

Dr. Bekhit

The liver is appropriate in position and size and presents uniform opacity.

The splenic head is in the anticipated position and within normal limits for size and opacity. The splenic tail is not seen.

INVOICE

34948

Both kidneys are seen and present with normal size, shape, delineation, and opacity. The urinary bladder is in its anticipated position. No radiopaque calculi are noted throughout the upper and lower urinary tract.

The stomach is post-prandial

DATE

1/20/22

The small intestinal loops are of even diameter and non-dilated. A small amount of gas is seen within the small intestinal loops and considered within normal limits.



PATIENT The colon is seen in the expected position and presents with appropriate content.

Kyle Dean **RADIOGRAPHIC DIAGNOSIS**

SPECIES

Feline

- Moderate ventral alveolar infiltrate of the lung
- No obvious cardiomegaly
- No evidence of pleural effusion
- Radiographically normal abdomen

INTERPRETATION OF FINDINGS & FURTHER RECOMMENDATIONS

BREED

DSH

SEX

Neutered Male

AGE

13 Years

INTERPRETED BY

Nele Eley (Ondreka),
DVM Dr. med. vet.,
DipECVDI

HOSPITAL NAME

St. Catharine's AH

REFERRING VET

Dr. Bekhit

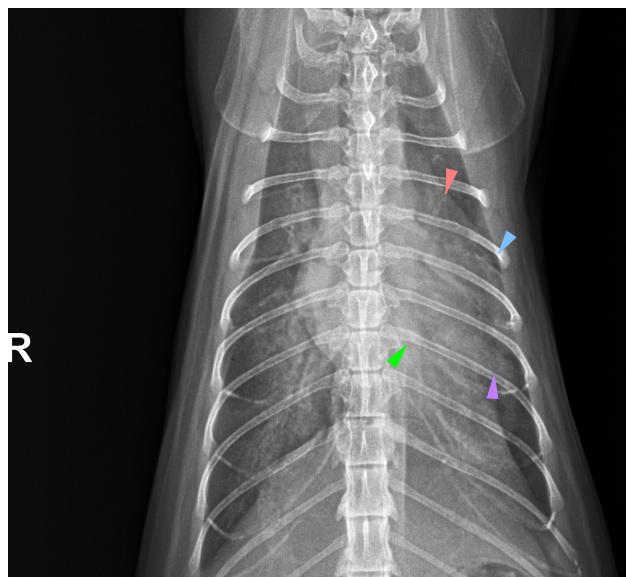
INVOICE

34948

DATE

1/20/22

The radiographic study reveals a moderate multifocal alveolar infiltrate of the lung with ventral accentuation. The changes are most pronounced in the caudal subsegment of the left cranial lung lobe. The main differential diagnosis is infectious pneumonia/bronchopneumonia. There is no discreet mass or mass effect seen. However, lobar neoplasia cannot be ruled out entirely. Atypical presentation of non-cardiogenic pulmonary edema/acute respiratory distress is a moderate potential differential diagnosis, which seems less likely owing to the patient history of longstanding clinical signs. Based on the radiographs, there is no direct evidence of underlying cardiac disease.



The information and recommendations provided are based on the images presented by the referring veterinarian. No evaluation can be communicated regarding pathology that was not visible in the image/video clips provided.

Thank you for this referral. If the clinical or image interpretation does not parallel your findings or if I can be of any further assistance please contact me.

Nele Eley (Ondreka), DVM, Dr. med. vet., DipECVDI
European Specialist in Veterinary Diagnostic Imaging, Cert. Radiology,
Senior lecturer University of Giessen/Germany, Veterinary Faculty, Department of Radiology.
Nele.Eley@sonopath.com