


**PATIENT PRESENTING CLINICAL SIGNS**

Ivy Watchorn Rescued in August 2021 w/ LF angular limb deformity. Prev medical hx unknown.

**COMPUTED TOMOGRAPHIC STUDY OF THE FOREARMS**
**SPECIES**

Plain study in bone and soft tissue windows available for review.

Canine

According to the history, the changes are on the left. I will refer to the labeling of the images with the right limb being the diseased limb.

**BREED**
**COMPUTED TOMOGRAPHIC FINDINGS**

Lab X

Compression and collapse of the distal ulnar physis is seen in what is labeled as the right front forearm. The flaring of the right distal ulna metaphysis, which has significant overlap with the distal epiphysis. The right ulna is 1.5 cm shorter than the left one. The right radius is 1.0 cm shorter than the left radius. Irregular narrowing of the distal right radial growth plate is seen. There is moderate and acute dorsal and medial curvature of the distal right radius level with its distal metaphysis, resulting in a valgus position of the right carpus. Center of rotation is the transition between the distal diaphysis and distal metaphysis of the right radius. The dorsal curvature is approximately 50 degrees, and medial curvature is 35 degrees.

**SEX**

Spayed Female

**AGE**

8 Months

**COMPUTED TOMOGRAPHIC DIAGNOSIS**

- Angular limb deformity with moderate carpus valgus and radius corpus secondary to premature closure of the distal right ulnar growth plate.
- Reduced longitudinal growth of the right ulna and right radius

**INTERPRETED BY**

Nele Eley (Ondreka),  
 DVM Dr. med. vet.,  
 DipECVDI

**INTERPRETATION OF FINDINGS & FURTHER RECOMMENDATIONS**

The CT study reveals angular limb deformity in the distal right forearm with moderate radius corpus and carpus valgus secondary to premature closure of the distal right ulnar growth plate. Trauma, in terms of Salter Harris Type 1 fracture, is considered the most likely underlying cause of the angular limb deformity. Type 1 injury of the distal right ulna and radial growth plates is considered likely. However, compression of the physis in terms of Type 5 injury, which tends to be rare, cannot be ruled out.

**HOSPITAL NAME**

Animal Health  
 Partners

**REFERRING VET**

Dr. Debbie Reynolds

**INVOICE**

34952

**DATE**

1/20/22



**PATIENT**

Ivy Watchorn

**SPECIES**

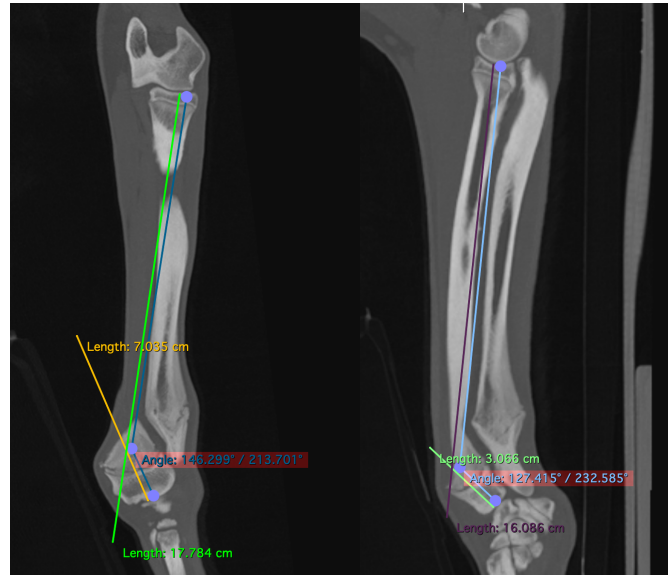
Canine

**BREED**

Lab X

**SEX**

Spayed Female



**AGE**

8 Months

The information and recommendations provided are based on the images presented by the referring veterinarian. No evaluation can be communicated regarding pathology that was not visible in the image/video clips provided.

Thank you for this referral. If the clinical or image interpretation does not parallel your findings or if I can be of any further assistance please contact me.

**INTERPRETED BY**

Nele Eley (Ondreka),  
DVM Dr. med. vet.,  
DipECVDI

**Nele Eley (Ondreka)**, DVM, Dr. med. vet., DipECVDI  
European Specialist in Veterinary Diagnostic Imaging, Cert. Radiology,  
Senior lecturer University of Giessen/Germany, Veterinary Faculty, Department of Radiology.  
Nele.Eley@sonopath.com

**HOSPITAL NAME**

Animal Health  
Partners

**REFERRING VET**

Dr. Debbie Reynolds

**INVOICE**

34952

**DATE**

1/20/22