



PATIENT

Putty Craviolo

PRESENTING CLINICAL SIGNS

hepatic mass 5.1 X 5.2 cm with splenic nodules on U/S concern for metastasis to lungs
 Abnormal PE/Chem/CBC/UA Results: recent ultrasound performed by Sonopath reveals hepatic mass, follow up chest rads concern for metastasis. elevated liver values on recent bloodwork

SPECIES

Feline

RADIOGRAPHIC STUDY OF THE THORAX

Right/left lateral and ventrodorsal views totaling 3 images available for review in jpeg format.

BREED

DSH

RADIOGRAPHIC FINDINGS

Patient has a history of hepatic mass and splenic nodules.

SEX

Male Neutered

An ill-defined soft tissue opaque mass effect is seen in the cranioventral abdomen border effacing with the liver. Caudodorsal deviation of the stomach is noted.

The degree of pulmonary inflation is moderate. Minimal bronchial wall enhancement and occasional peribronchial cuffing are seen. There is no evidence of interstitial nodules or masses.

AGE

9

Course and width of the trachea are considered within normal limits.

The cardiovascular structures are considered within normal limits. Mild cranial rotation of the cardiac silhouette and aortic arch are seen and considered within age related normal limits.

INTERPRETED BY

Nele Eley, DVM
 Dr. med. Vet. DipECVDI

There is no evidence of mediastinal lymphadenomegaly.

Focal subcutaneous soft tissue swelling is seen caudodorsal to the scapulae. See arrow in image below.

HOSPITAL NAME

Ramapo Valley
 Animal Hospital

RADIOGRAPHIC DIAGNOSIS

- Normal age related findings of the thorax with no evidence of pulmonary metastases.
- Subcutaneous soft tissue mass effect caudodorsal to the scapulae.
- Hepatic mass effect correlating with the history of hepatic mass on ultrasound.

REFERRING VET

Dr. Manohar Katara

INTERPRETATION OF THE FINDINGS & FURTHER RECOMMENDATIONS

The radiographic screening is negative for pulmonary metastatic disease. The thoracic structures are considered within age related normal limits.

INVOICE

55934

Presence of a subcutaneous soft tissue mass in the caudal neck area should be ruled out. This may also represent a prior injection site.

DATE

1-2-23



PATIENT

Putty Craviolo

SPECIES

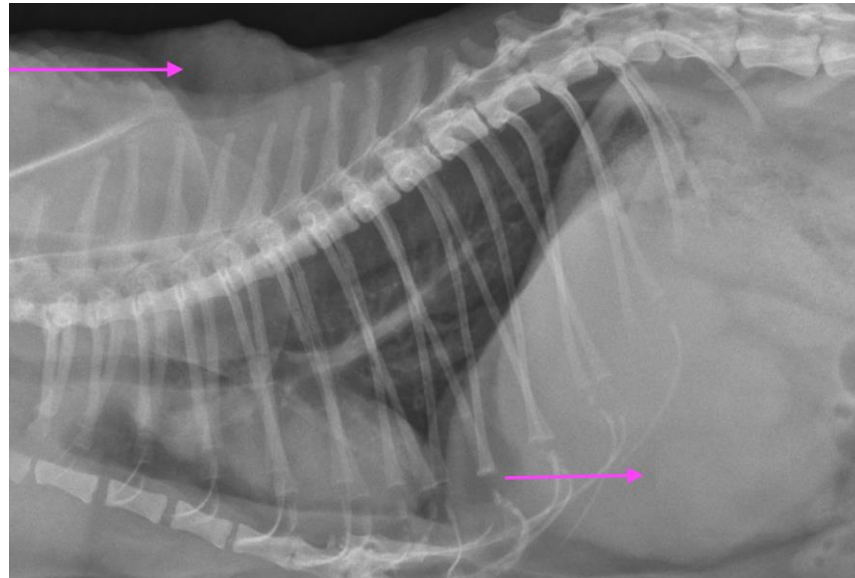
Feline

BREED

DSH

SEX

Male Neutered



AGE

9

The information and recommendations provided are based on the images presented by the referring veterinarian/sonographer. No evaluation can be communicated regarding pathology that was not visible in the image/video clips provided.

INTERPRETED BY

Nele Eley, DVM
Dr. med. Vet. DipECVDI

Thank you for this referral. If the clinical or image interpretation does not parallel your findings or if I can be of any further assistance please contact me.

Nele Eley, DVM, Dr. med. vet., DipECVDI
European Specialist in Veterinary Diagnostic Imaging, Cert. Radiology,
Senior lecturer University of Giessen, Germany, Veterinary Faculty, Department of Radiology
Nele.Eley@sonopath.com

HOSPITAL NAME

Ramapo Valley
Animal Hospital

REFERRING VET

Dr. Manohar Katara

INVOICE

55934

DATE

1-2-23