

**PATIENT**

Lightening Melendez

**PRESENTING CLINICAL SIGNS**

Came in from outside limping on left hind last night. Non-weight bearing.  
Abnormal PE/Chem/CBC/UA Results: Hesitant on palpation but no specific area of pain on palpation of left hind

**SPECIES**

Canine

**RADIOGRAPHIC STUDY OF THE STIFLES**

Mediolateral views of both stifles and ventrodorsal hip extended view of the pelvis with craniocaudal projection of the stifles totaling 3 images available for review.

**BREED**

Shihtzu Mix

**RADIOGRAPHIC FINDINGS**

Mild atrophy of the left hind limb musculature is noted.

**SEX**

Spayed Female

There is moderate articular swelling of the left stifle joint. A moderate amount of periarticular osteophytes accentuating the distal pole of the patella, femoral trochlea, and cranial and caudal margins of the tibial plateau are seen. The patella appears to be in situ on both orthogonal views.

The right stifle joint presents within age related normal limits.

**AGE**

7 Years

**RADIOGRAPHIC DIAGNOSIS**

- Moderate osteoarthropathy of the left stifle joint with articular swelling and osteophytosis.
- Mild disuse atrophy of the left hind limb musculature.

**INTERPRETED BY**

Nele Eley, DVM  
Dr. med. Vet. DipECVDI

**INTERPRETATION OF THE FINDINGS & FURTHER RECOMMENDATIONS**

The radiographic study reveals chronic degenerative joint disease with articular swelling of the left stifle joint. Differential diagnosis includes degenerative joint disease with cruciate ligament pathology, meniscopathy, patella luxation, and less likely other arthropathy including immune mediated arthritis or post-traumatic degenerative joint disease. Correlation with the clinical palpation required. Aspiration and analysis of synovia could be considered should the clinical palpation be inconclusive in order to rule out arthritis other than DJD. An MRI of the stifle joint could be considered to further define for the potential presence of cruciate ligament pathology and/or meniscopathy.

**HOSPITAL NAME**

The Pet Hospital of  
Stratford

**REFERRING VET**

Dr. Claudia Giuliani,  
DVM

**INVOICE**

55933

**DATE**

1-2-23



**PATIENT**

Lightening Melendez

**SPECIES**

Canine

**BREED**

Shihtzu Mix

**SEX**

Spayed Female

**AGE**

7 Years

**INTERPRETED BY**

Nele Eley, DVM  
Dr. med. Vet. DipECVDI

**HOSPITAL NAME**

The Pet Hospital of  
Stratford

**REFERRING VET**

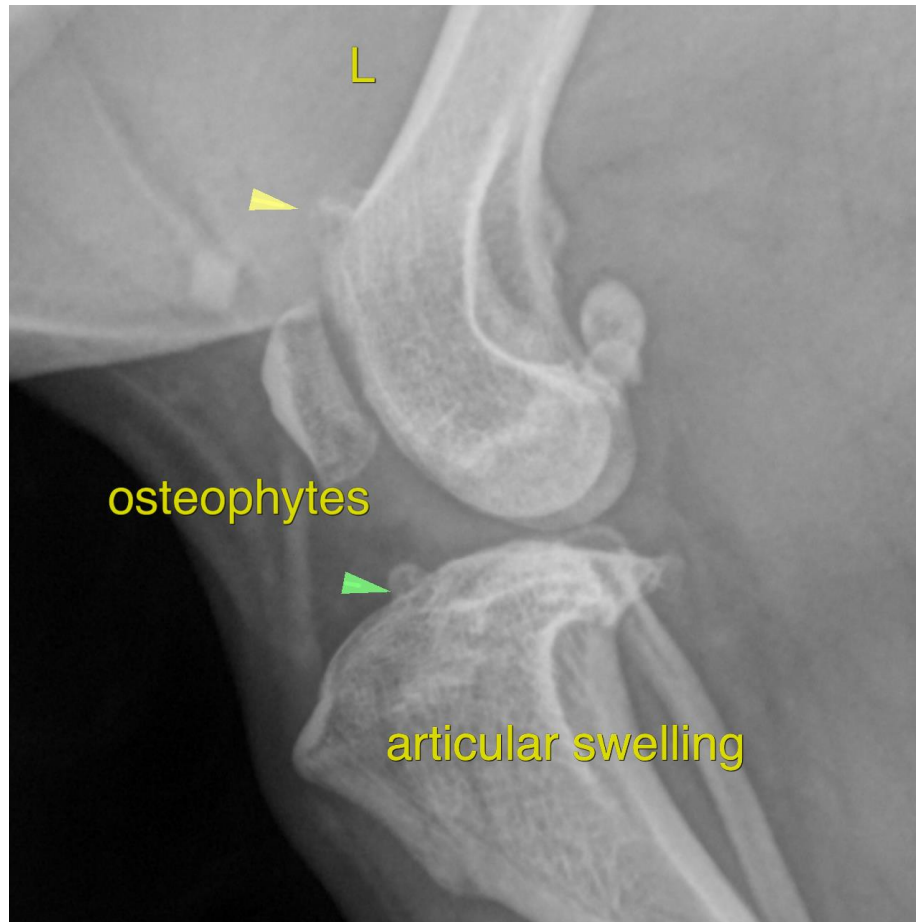
Dr. Claudia Giuliani,  
DVM

**INVOICE**

55933

**DATE**

1-2-23



**The information and recommendations provided are based on the images presented by the referring veterinarian/sonographer. No evaluation can be communicated regarding pathology that was not visible in the image/video clips provided.**

Thank you for this referral. If the clinical or image interpretation does not parallel your findings or if I can be of any further assistance please contact me.

**Nele Eley, DVM, Dr. med. vet., DipECVDI**  
European Specialist in Veterinary Diagnostic Imaging, Cert. Radiology,  
Senior lecturer University of Giessen, Germany, Veterinary Faculty, Department of Radiology  
Nele.Eley@sonopath.com