



PATIENT

Pluto Yang

PRESENTING CLINICAL SIGNS

Cystine stones, found a little bit of blood in his semen, and check benign bump on left shoulder. Enlarged R testicle, skin and coat- medium size mass on L shoulder, small mass on L distal F and H limb Possible testicular neoplasia R/O prostatic disease

SPECIES

Canine

RADIOGRAPHIC STUDY OF THE THORAX & ABDOMEN

Right lateral and ventrodorsal views of the thorax and abdomen totaling 4 images available for review.

BREED

Russell Terrier

RADIOGRAPHIC FINDINGS

Thorax

SEX

Male

The patient is obese.

The surrounding bony structures are within normal limits.

The extrathoracic soft tissues present homogeneous without abnormalities.

AGE

10 Years

The heart is of normal size and shape and there is no evidence of cardiac chamber or vascular enlargement. The pulmonary vasculature is within normal limits.

The cranial mediastinum presents the expected soft tissue opacity. The mediastinal width is less than twice the width of the vertebral column at the same level.

INTERPRETED BY

Nele Eley, DVM
Dr. med. Vet. DipECVDI

Mild redundancy of the dorsal tracheal ligament of the cervical trachea is seen.

The bronchial tree presents with thin walls and tapers uniformly towards the periphery as expected.

HOSPITAL NAME

Animal Paradise
Hospital

The lung parenchyma presents the expected architecture and opacity. The intrapulmonary vascular branching is seen up to the third order lung vessels.

The diaphragm is well delineated with even surface and the expected mild cranial bulging of the diaphragmatic cupola.

REFERRING VET

Dr. Mostafa Elshafie

Abdomen

The surrounding bony structures are within normal limits.

INVOICE

49694

No abnormalities of the extraabdominal soft tissues are noted. The abdominal wall is smooth and thin.

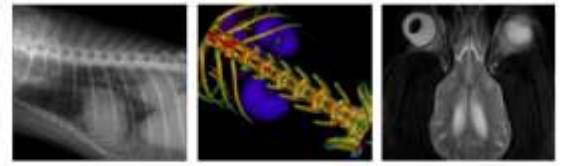
The serosal detail is maintained throughout the peritoneal and retroperitoneal space.

DATE

1-19-22

The liver is appropriate in position, size and presents uniform opacity.

The splenic head is in the anticipated position and within normal limits for size and opacity. The splenic body and tail are considered normal for position, size, shape and opacity.



PATIENT

Pluto Yang

Both kidneys are seen and present with normal size, shape, delineation and opacity.

The urinary bladder is moderate distended. No evidence of abnormal opacities is seen within the urinary bladder. However, cystine stones are nonradiopaque.

SPECIES

Canine

Moderate enlargement of the prostate is seen. The prostate is of uniform opacity. The periprostatic fat is well delineated and presents within normal limits. The prostatic height occupies approximately 50% of the pelvic inlet which is within normal limits.

BREED

Russell Terrier

No radiographic evidence of sublumbar lymphadenomegaly is seen.

The stomach is in its anticipated position and presents normal content.

SEX

Male

The small intestinal loops are of even diameter and non-dilated, a small amount of gas is seen within the small intestinal loops and considered within normal limits.

The colon is seen in the expected position and presents with appropriate content.

RADIOGRAPHIC DIAGNOSIS

- Prostatomegaly.
- Redundant dorsal tracheal ligament.

AGE

10 Years

INTERPRETATION OF THE FINDINGS & FURTHER RECOMMENDATIONS

The radiographic study reveals prostatic enlargement. The findings are within the expected limits and no direct evidence of prostatitis or prostatic neoplasia is seen. Benign prostatic hyperplasia of the non-neutered male is considered most likely; however, prostatitis and early neoplasia cannot be ruled out entirely. Correlate with the clinical palpation and consider further definition by means of ultrasound if indicated.

INTERPRETED BY

Nele Eley, DVM
Dr. med. Vet. DipECVDI

HOSPITAL NAME

Animal Paradise
Hospital

The redundancy of the dorsal tracheal ligament is most likely an incidental finding; however, it may be associated with dynamic tracheal disease. Clinical correlation warranted.

REFERRING VET

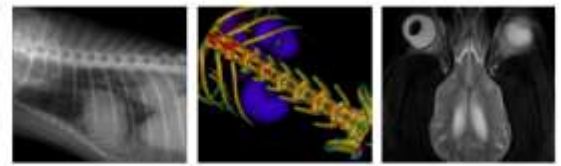
Dr. Mostafa Elshafie

INVOICE

49694

DATE

1-19-22



PATIENT

Pluto Yang

SPECIES

Canine

BREED

Russell Terrier

SEX

Male

AGE

10 Years

INTERPRETED BY

Nele Eley, DVM
Dr. med. Vet. DipECVDI

HOSPITAL NAME

Animal Paradise
Hospital

REFERRING VET

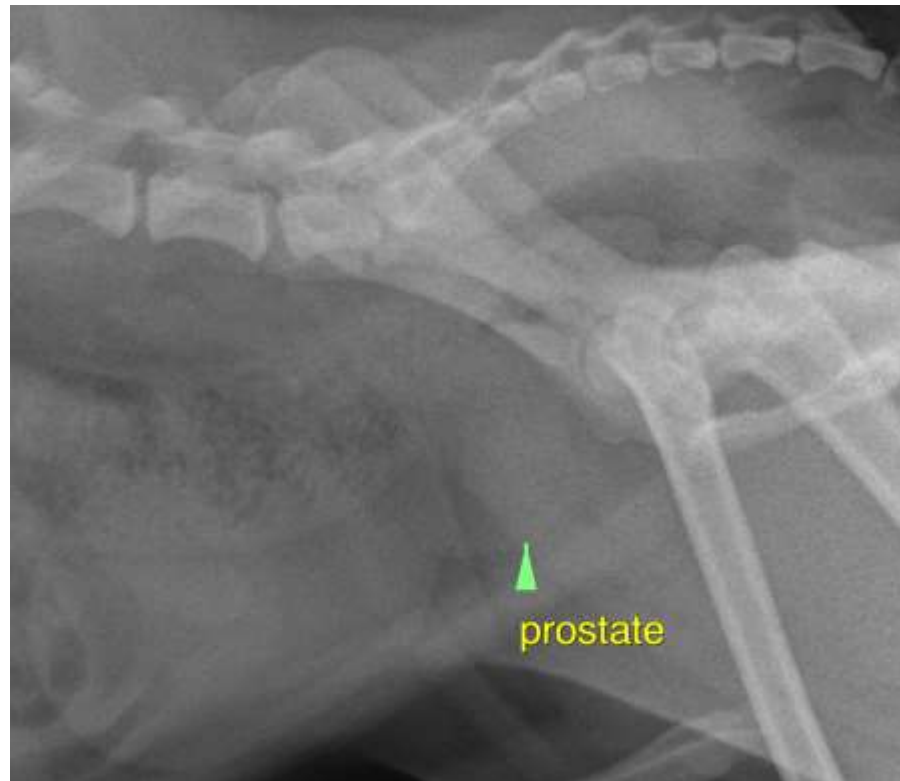
Dr. Mostafa Elshafie

INVOICE

49694

DATE

1-19-22



The information and recommendations provided are based on the images presented by the referring veterinarian. No evaluation can be communicated regarding pathology that was not visible in the image/video clips provided.

Thank you for this referral. If the clinical or image interpretation does not parallel your findings or if I can be of any further assistance please contact me.

Nele Eley, DVM, Dr. med. vet., DipECVDI
European Specialist in Veterinary Diagnostic Imaging, Cert. Radiology,
Senior lecturer University of Giessen, Germany, Veterinary Faculty, Department of Radiology
Nele.Eley@sonopath.com