



**PATIENT**

Kobe Needle

**SPECIES**

Canine

**BREED**

Boston Terrier

**SEX**

Male Neutered

**AGE**

8 Years, 2 Months

**INTERPRETED BY**

Nele Eley, DVM  
Dr. med. Vet. DipECVDI

**HOSPITAL NAME**

Northvale Veterinary  
Clinic

**REFERRING VET**

Dr. Stefanie Simon

**INVOICE**

49702

**DATE**

1-19-22

**PRESENTING CLINICAL SIGNS**

History of successful removal of 2 cystic calculi on 10/26/21. Pre-op and post-op radiographs submitted for review at that time. Dog was doing great on C/D until yesterday when he urinated on the couch once and has been PU/PD. No hematuria or stranguria noted. Otherwise doing fine at home.

Abnormal PE/Chem/CBC/UA Results: UA w/ c/s pending.

**RADIOGRAPHIC STUDY OF THE ABDOMEN**

Right/left lateral and ventrodorsal views totaling 3 images available for review.

**RADIOGRAPHIC FINDINGS**

The patient is obese.

The urinary bladder appears to be empty. No evidence of abnormal opacities is seen level with the urinary bladder or penile urethra.

The radiographic presentation of the kidneys and spleen is within normal limits.

There is moderate generalized enlargement of the liver with slightly rounded lobar margins.

The stomach is post-prandial.

The small intestinal loops are evenly distributed throughout the mid abdomen.

A moderate amount of fecal material is seen within the colon.

**RADIOGRAPHIC DIAGNOSIS**

- Moderate generalized hepatomegaly.
- No evidence of radiopaque calculi in the urinary tract.

**INTERPRETATION OF THE FINDINGS & FURTHER RECOMMENDATIONS**

The radiographic study shows moderate generalized hepatomegaly. Differential diagnosis includes metabolic/endocrine hepatopathy. A diffuse inflammatory or neoplastic infiltrate cannot be ruled out entirely. Correlate with the laboratory values and consider complete ultrasound of the abdomen with eventual parenchymal sampling as indicated.



**PATIENT**

Kobe Neadle

**SPECIES**

Canine

**BREED**

Boston Terrier

**SEX**

Male Neutered

**AGE**

8 Years, 2 Months

**INTERPRETED BY**

Nele Eley, DVM  
Dr. med. Vet. DipECVDI

**HOSPITAL NAME**

Northvale Veterinary  
Clinic

**REFERRING VET**

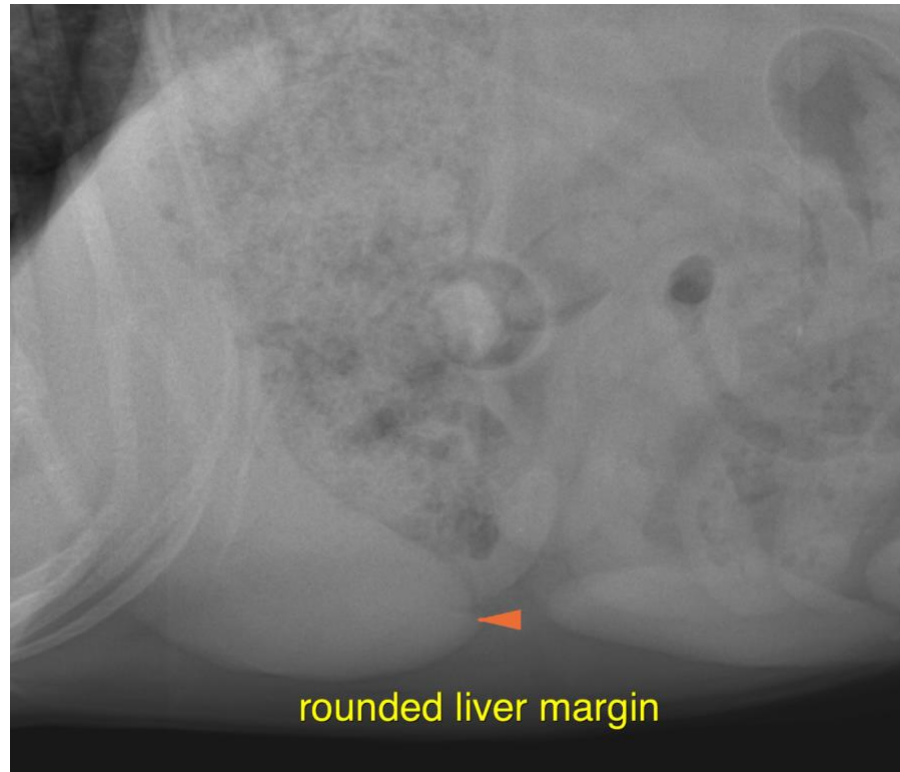
Dr. Stefanie Simon

**INVOICE**

49702

**DATE**

1-19-22



The information and recommendations provided are based on the images presented by the referring veterinarian. No evaluation can be communicated regarding pathology that was not visible in the image/video clips provided.

Thank you for this referral. If the clinical or image interpretation does not parallel your findings or if I can be of any further assistance please contact me.

**Nele Eley**, DVM, Dr. med. vet., DipECVDI  
European Specialist in Veterinary Diagnostic Imaging, Cert. Radiology,  
Senior lecturer University of Giessen, Germany, Veterinary Faculty, Department of Radiology  
Nele.Eley@sonopath.com