

**PATIENT**

Johnny Clark

PRESENTING CLINICAL SIGNS

Started coughing about a week ago. Had been at doggie day care about a week before he started coughing. Has a gag like cough. Cough is worse with excitement. Currently being treated with doxycycline and hydrocodone and O. feels that coughing is getting worse. CBC pending.

SPECIES

Canine

RADIOGRAPHIC STUDY OF THE THORAX

Right lateral and ventrodorsal views totaling 2 images available for review.

BREED

Labrador Retriever

RADIOGRAPHIC FINDINGS

Both elbows show signs of elbow dysplasia with osteoarthritis.

Course and width of the trachea are considered within normal limits.

SEX

MN

There is a mild generalized bronchial lung pattern with mild caudodorsal accentuation. Regional increase in peribronchial interstitial opacity is seen level with the right middle and right caudal lobes. This appears to be associated with mild volume decrease.

AGE

4

The vertebral heart score is 10.2. The radiographic presentation of the cardiac silhouette is within normal limits.

RADIOGRAPHIC DIAGNOSIS

- Mild bronchial lung pattern with regional peribronchial interstitial opacity in the right lung.
- Bilateral elbow osteoarthritis.

INTERPRETED BY

Nele Eley, DVM
Dr. med. Vet. DipECVDI

INTERPRETATION OF THE FINDINGS & FURTHER RECOMMENDATIONS**HOSPITAL NAME**

Healing Paws

The regional increase in pulmonary opacity with peribronchial accentuation in the right lung may suggest presence of lobar pneumonia; however, atelectasis secondary to prior positioning of the patient in right lateral recumbency cannot be ruled out as a differential diagnosis. There appears to be evidence of active lower airway disease such as infectious bronchitis including viral, bacterial, and less likely parasitic, or protozoal. Eosinophilic or irritant bronchopneumopathy cannot be ruled out as a differential diagnosis. Consider further definition by means of airway endoscopy with airway sampling.

REFERRING VET

Jennifer Levitsky

INVOICE

49688

DATE

1-19-22



PATIENT

Johnny Clark

SPECIES

Canine

BREED

Labrador Retriever

SEX

MN

AGE

4

INTERPRETED BY

Nele Eley, DVM
Dr. med. Vet. DipECVDI

HOSPITAL NAME

Healing Paws

REFERRING VET

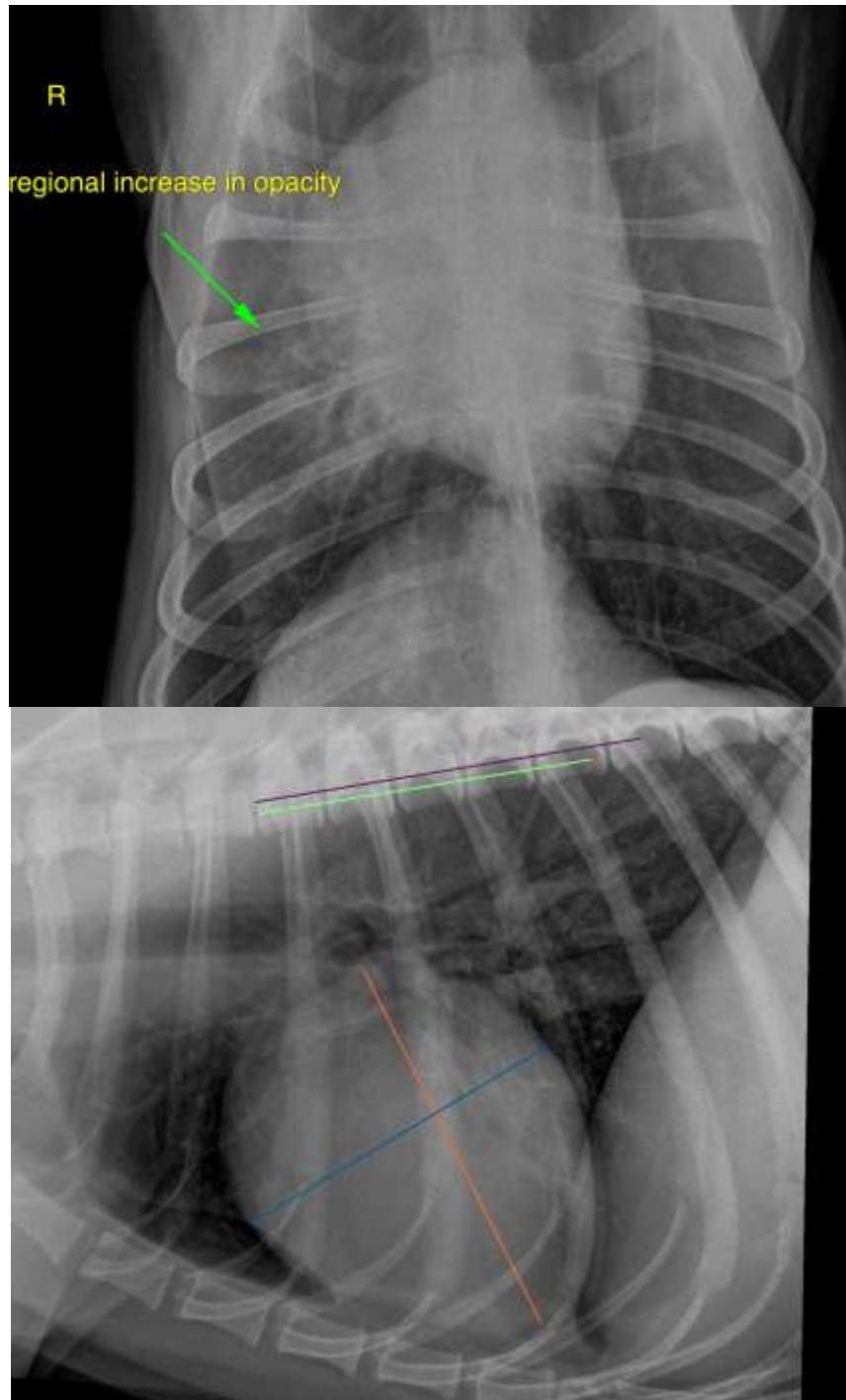
Jennifer Levitsky

INVOICE

49688

DATE

1-19-22





PATIENT

Johnny Clark

SPECIES

Canine

The information and recommendations provided are based on the images presented by the referring veterinarian. No evaluation can be communicated regarding pathology that was not visible in the image/video clips provided.

BREED

Labrador Retriever

Thank you for this referral. If the clinical or image interpretation does not parallel your findings or if I can be of any further assistance please contact me.

Nele Eley, DVM, Dr. med. vet., DipECVDI
European Specialist in Veterinary Diagnostic Imaging, Cert. Radiology,
Senior lecturer University of Giessen, Germany, Veterinary Faculty, Department of Radiology
Nele.Eley@sonopath.com

SEX

MN

AGE

4

INTERPRETED BY

Nele Eley, DVM
Dr. med. Vet. DipECVDI

HOSPITAL NAME

Healing Paws

REFERRING VET

Jennifer Levitsky

INVOICE

49688

DATE

1-19-22