

**PATIENT**

Gemi Echanove

PRESENTING CLINICAL SIGNS

Heart murmur present 6 months. No clinical problems.

SPECIES

Canine

RADIOGRAPHIC STUDY OF THE THORAX

Right/left lateral and ventrodorsal views totaling 3 images available for review.

BREED

Yorkie

RADIOGRAPHIC FINDINGS

Mild C3/4 and moderate L2/3 spondyloses are seen.

SEX

Spayed Female

Mild tracheal collapse and redundancy of the cervical tracheal are seen.

The thoracic trachea is elevated due to left sided cardiomegaly with left atrial tenting and loss of the caudal cardiac waist. The vertebral heart score is 11.9. Mild dilation of the cranial lobar pulmonary vein is seen. There is no evidence of cardiogenic pulmonary edema.

There is mild generalized hepatomegaly with no significant rounding of the lobar margins.

AGE

12

RADIOGRAPHIC DIAGNOSIS

- Moderate left sided cardiomegaly with left atrial enlargement and presumed early pulmonary venous congestion.
- Suspect dynamic tracheal disease.
- Spondyloses.

INTERPRETED BYNele Eley, DVM
Dr. med. Vet. DipECVDI**INTERPRETATION OF THE FINDINGS & FURTHER RECOMMENDATIONS**

The radiographic findings are compatible with left sided cardiomegaly with left atrial tenting. Myxomatous degeneration of the mitral valve with chronic mitral valve regurgitation is the most common and likely underlying cause. There appears to be early pulmonary venous congestion without evidence of cardiogenic pulmonary edema. A complete assessment would require a cardiac echo to further assess for the need of medication and adjust it to the disease stage.

There also appears to be potential for dynamic tracheal disease. Clinical correlation is required. Clinical significance of which is not necessarily given.

HOSPITAL NAMEPacific Avenue
Veterinary Clinic**REFERRING VET**

Sid Bruckert-Frisk

The radiographic presentation of the lung and bronchial tree was within age related normal limits.

INVOICE

49685

DATE

1-19-22



PATIENT

Gemi Echanove

SPECIES

Canine

BREED

Yorkie

SEX

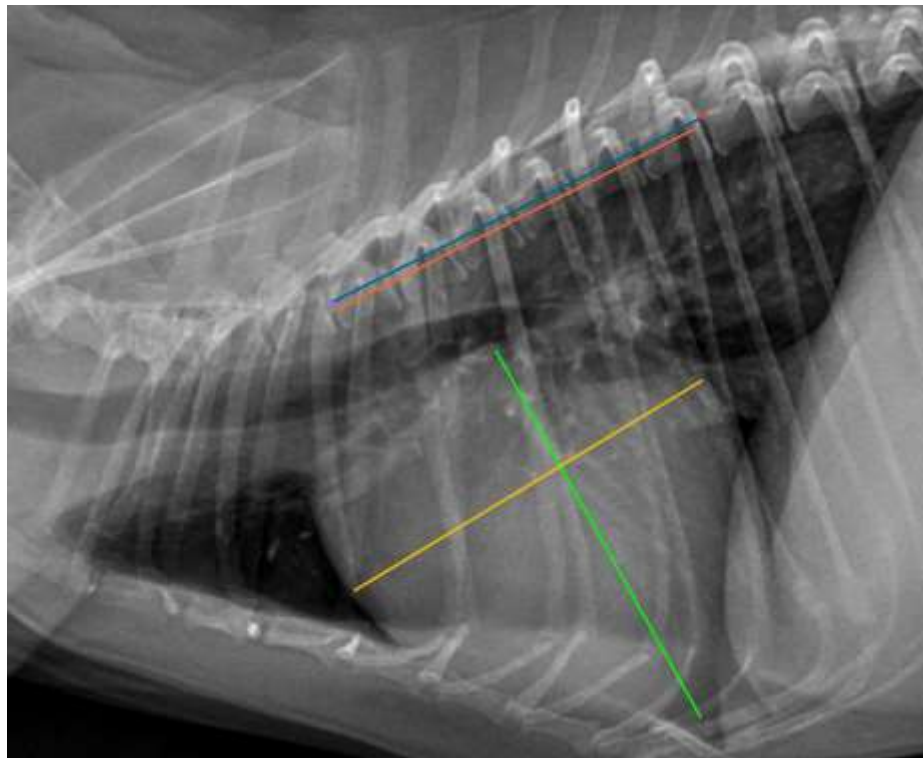
Spayed Female

AGE

12

INTERPRETED BY

Nele Eley, DVM
Dr. med. Vet. DipECVDI



HOSPITAL NAME

Pacific Avenue
Veterinary Clinic

REFERRING VET

Sid Bruckert-Frisk

INVOICE

49685

DATE

1-19-22

The information and recommendations provided are based on the images presented by the referring veterinarian. No evaluation can be communicated regarding pathology that was not visible in the image/video clips provided.

Thank you for this referral. If the clinical or image interpretation does not parallel your findings or if I can be of any further assistance please contact me.

Nele Eley, DVM, Dr. med. vet., DipECVDI
European Specialist in Veterinary Diagnostic Imaging, Cert. Radiology,
Senior lecturer University of Giessen, Germany, Veterinary Faculty, Department of Radiology
Nele.Eley@sonopath.com