



PATIENT PRESENTING CLINICAL SIGNS

Cody Shears History: 12y old MN Yorkie presents for abnormal bm, producing small bm for <1 week. O tried pumpkin - pet wouldn't eat. Yesterday p vomited white foam thick mucus multiple x. Offered chicken and rice yesterday - ate well. O interested in x-rays but requests sedation.

SPECIES Abnormal PE/Chem/CBC/UA Results: CV/Respiratory: Normal heart rate and rhythm, no murmur, pulses strong and synchronous, normal bronchovesicular sounds. EENT: Clear AU. OS: mature cataract. OD: immature cataract. No nasal discharge. No cough on tracheal palpation. Oral cavity: Moderate dental tartar Musculoskeletal: BCS = 6/9. Ambulatory x 4. Grade 3/4 MPL bilateral Uro/Perineum: No significant lesions Abd/GI: Soft, non-painful. No obvious masses or fluid wave palpated Lymph Nodes: No peripheral lymphadenopathy Neurological: Alert and appropriate. No significant abnormalities Skin: Thinning hair coat around neck region.

Canine Hyperpigmentation on ventral abdomen. Good hair coat. No ectoparasites seen Mentation: BAR Hydration: N

BREED Yorkie

SEX RADIOGRAPHIC STUDY OF THE ABDOMEN

NM Right lateral and ventrodorsal views totaling 2 images available for review.

RADIOGRAPHIC FINDINGS

AGE The abdominal cavity appears voluminous.

12 Years, 1 Month The urinary bladder is not seen.

INTERPRETED BY Multiple mineral opacities superimpose onto the renal diverticuli of both kidneys.

Nele Eley, DVM
Dr. med. Vet. DipECVDI There is moderate generalized enlargement of the liver with slightly rounded lobar margins. A round soft tissue opaque mass effect is superimposed onto the liver in the right lateral view (see image below).

HOSPITAL NAME The stomach is post-prandial.

DPC Veterinary Hospital Mild generalized dilation of the small intestine with elementary and gas patterns is seen.

The colon contains a moderate amount of fecal material.

REFERRING VET There appears to be a relatively large amount of inspissated fecal material within the rectum.

Dr. Rivera Dorsal deviation of the sacrum is seen.

INVOICE One patella is luxated in the lateral view.

49696 Bilateral stifle osteoarthritis is noted.

There appears to be mild generalized osteopenia.

DATE

1-19-22



PATIENT

Cody Shears

RADIOGRAPHIC DIAGNOSIS

- Suspect functional ileus.
- Constipation of the rectum.
- Moderate hepatomegaly with soft tissue opaque mass effect in the cranial abdomen.
- Bilateral hypercalcemic nephropathy.

SPECIES

Canine

INTERPRETATION OF THE FINDINGS & FURTHER RECOMMENDATIONS

The radiographic study suggests functional ileus of the small intestine. Part of the gas opaque content may be due to swallowing of air; however, functional ileus or subileus cannot be ruled out entirely.

BREED

Yorkie

The moderate generalized hepatomegaly may be due to metabolic/endocrine hepatopathy. Diffuse infiltrate disease cannot be ruled out entirely. The origin of the soft tissue opaque mass effect in the cranial abdomen superimposed onto the liver remains unclear. This may represent lobar enlargement of the liver versus dilated gallbladder. Further definition by means of ultrasound is strongly recommended in this patient if not performed already.

SEX

NM

AGE

12 Years, 1 Month

INTERPRETED BY

Nele Eley, DVM
Dr. med. Vet. DipECVDI

HOSPITAL NAME

DPC Veterinary
Hospital

REFERRING VET

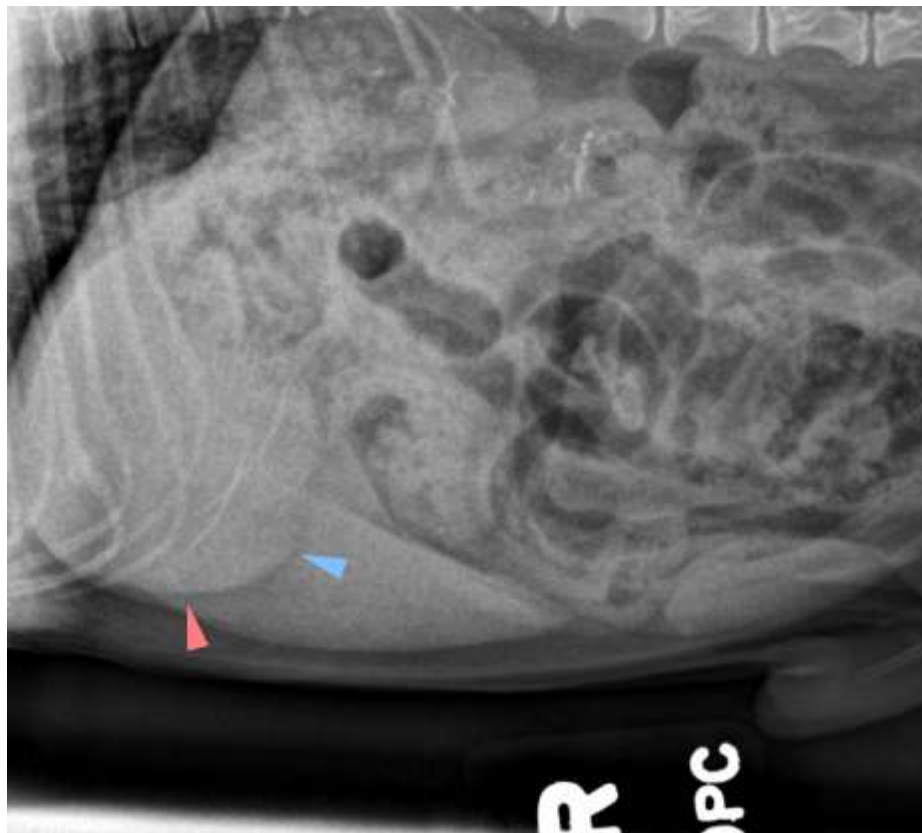
Dr. Rivera

INVOICE

49696

DATE

1-19-22





PATIENT

Cody Shears

SPECIES

Canine

The information and recommendations provided are based on the images presented by the referring veterinarian. No evaluation can be communicated regarding pathology that was not visible in the image/video clips provided.

BREED

Yorkie

Thank you for this referral. If the clinical or image interpretation does not parallel your findings or if I can be of any further assistance please contact me.

Nele Eley, DVM, Dr. med. vet., DipECVDI
European Specialist in Veterinary Diagnostic Imaging, Cert. Radiology,
Senior lecturer University of Giessen, Germany, Veterinary Faculty, Department of Radiology
Nele.Eley@sonopath.com

SEX

NM

AGE

12 Years, 1 Month

INTERPRETED BY

Nele Eley, DVM
Dr. med. Vet. DipECVDI

HOSPITAL NAME

DPC Veterinary
Hospital

REFERRING VET

Dr. Rivera

INVOICE

49696

DATE

1-19-22