

**PATIENT**

Coco Ostrander

PRESENTING CLINICAL SIGNS

Pet presented for evaluation of mass growing on the right side of the muzzle, first noticed a few weeks ago and has steadily grown since then.

Abnormal PE/Chem/CBC/UA Results: In house cytology of mass FNA the day of CT scan revealed primarily degenerate neutrophils.

SPECIES

Canine

COMPUTED TOMOGRAPHIC STUDY OF THE DENTAL ARCADES

Plain and post contrast studies available for review.

BREED

Pitbull Terrier

COMPUTED TOMOGRAPHIC FINDINGS

The dentition is incomplete. Triadan 304 is absent.

SEX

FS

There is a complicated crown fracture with open pulpal cavity at the triadan 104. Severe apical periodontal space widening with loss of the lamina dura, expansion of the apical portion of the dental alveolus, peripheral sclerosis, and periosteal new bone formation at the lateral margin of the right maxilla are seen.

AGE

4 Years

There is moderate regional soft tissue swelling with heterogeneous contrast enhancement accentuating the periphery.

COMPUTED TOMOGRAPHIC DIAGNOSIS

- Complicated crown fracture of the triadan 104 with apical periodontitis, osteitis, and peripheral cellulitis.

INTERPRETED BY

Nele Eley, DVM
Dr. med. Vet. DipECVDI

INTERPRETATION OF THE FINDINGS & FURTHER RECOMMENDATIONS

The CT findings are compatible with apical tooth root abscessation, peripheral osteitis, and cellulitis of the triadan 104 after complicated crown fracture. Dental extraction is recommended.

HOSPITAL NAME

Wilson Veterinary
Hospital

REFERRING VET

Dr. Keith Burge

INVOICE

49683

DATE

1-19-22



PATIENT

Coco Ostrander

SPECIES

Canine

BREED

Pitbull Terrier

SEX

FS

AGE

4 Years

INTERPRETED BY

Nele Eley, DVM
Dr. med. Vet. DipECVDI

HOSPITAL NAME

Wilson Veterinary
Hospital

REFERRING VET

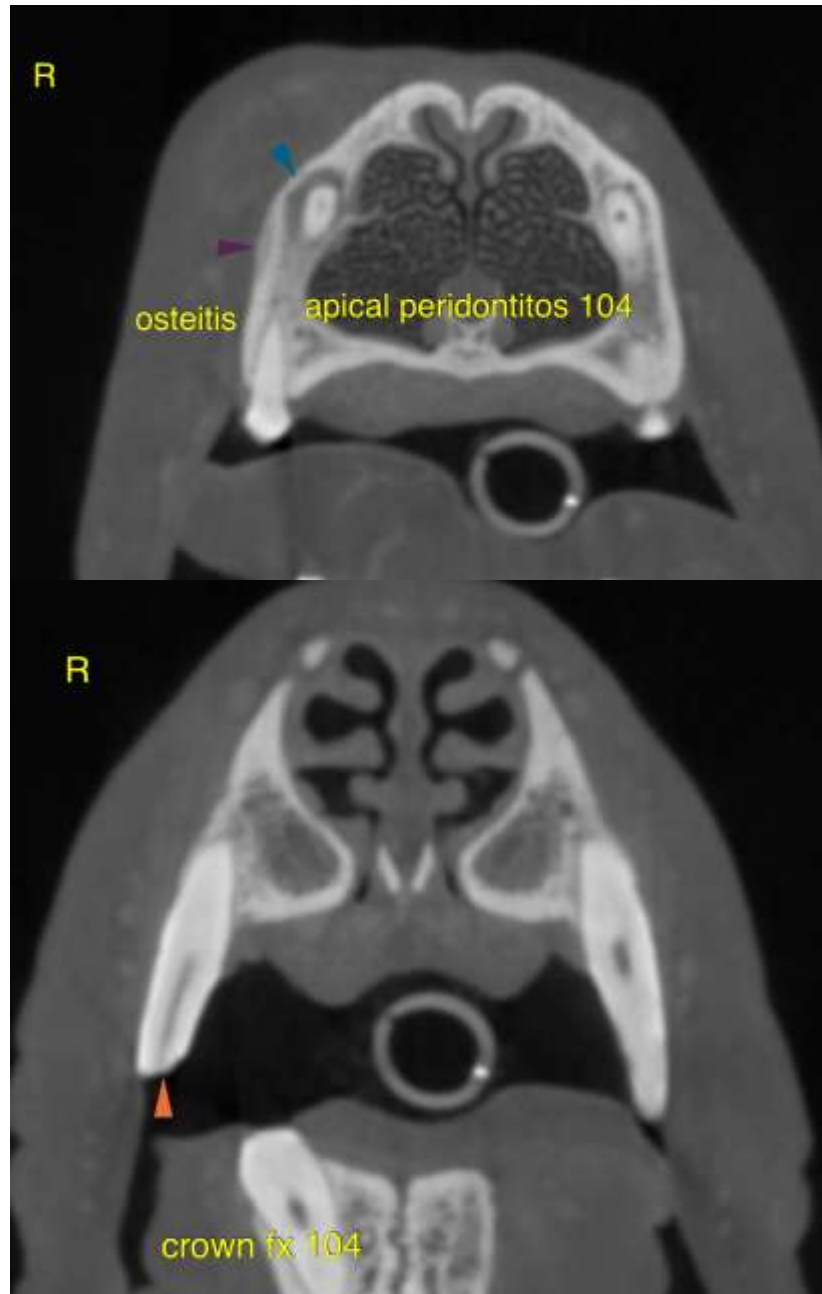
Dr. Keith Burge

INVOICE

49683

DATE

1-19-22





PATIENT

Coco Ostrander

The information and recommendations provided are based on the images presented by the referring veterinarian. No evaluation can be communicated regarding pathology that was not visible in the image/video clips provided.

Thank you for this referral. If the clinical or image interpretation does not parallel your findings or if I can be of any further assistance please contact me.

SPECIES

Canine

Nele Eley, DVM, Dr. med. vet., DipECVDI
European Specialist in Veterinary Diagnostic Imaging, Cert. Radiology,
Senior lecturer University of Giessen, Germany, Veterinary Faculty, Department of Radiology
Nele.Eley@sonopath.com

BREED

Pitbull Terrier

SEX

FS

AGE

4 Years

INTERPRETED BY

Nele Eley, DVM
Dr. med. Vet. DipECVDI

HOSPITAL NAME

Wilson Veterinary
Hospital

REFERRING VET

Dr. Keith Burge

INVOICE

49683

DATE

1-19-22