



**PATIENT**

Smokey Andrew

**PRESENTING CLINICAL SIGNS**

Presented for 2 day history of tachypnoea and dyspnoea. Otherwise well, EDDU normally. Large intra-thoracic mass on single lateral thoracic radiograph.

**SPECIES**

Feline

**COMPUTED TOMOGRAPHIC STUDY OF THE THORAX**

Plain and post contrast studies available for review.

**BREED**

DMH

**COMPUTED TOMOGRAPHIC FINDINGS**

A large mediastinal mass is occupying most of the thoracic cavity. The mass measures 14 cm in length, 5 cm in height, and 4.5 cm in width. The lesion margins are ill-defined and undulating. Moderate nonuniform contrast enhancement is seen within the mass. Severe dorsal and rightward deviation of the trachea, esophagus, and heart are seen. There is severe caudodorsal deviation of the bronchial bifurcation and lung. Significant collapse of the lung is noted. No additional nodules or masses can be identified in the tracheobronchial lymph node region or within the lung.

**SEX**

FN

There is no evidence of concurrent mediastinal or pleural effusion.

**AGE**

15

**COMPUTED TOMOGRAPHIC DIAGNOSIS**

- Large ventral mediastinal soft tissue mass meeting neoplastic criteria and causing significant pulmonary collapse.

**INTERPRETED BY**

Nele Eley, DVM  
Dr. med. Vet. DipECVDI

**INTERPRETATION OF THE FINDINGS & FURTHER RECOMMENDATIONS**

The CT study reveals a large mediastinal soft tissue mass meeting neoplastic criteria. Most of the thoracic cavity is occupied by the large volume of the mass and partial pulmonary collapse is caused due to the mass effect. Differential diagnosis includes mediastinal lymphoma, thymic lymphoma, and less likely thymoma, ectopic thyroid neoplasia, or other including soft tissue sarcoma. Final diagnosis will require sampling which could be obtained under ultrasonographic guidance using a cranial or lateral parasternal intercostal approach.

**HOSPITAL NAME**

Colyton Veterinary  
Hospital

**REFERRING VET**

Daisy Fung

**INVOICE**

56241

**DATE**

1-18-23



**PATIENT**

Smokey Andrew

**SPECIES**

Feline

**BREED**

DMH

**SEX**

FN

**AGE**

15

**INTERPRETED BY**

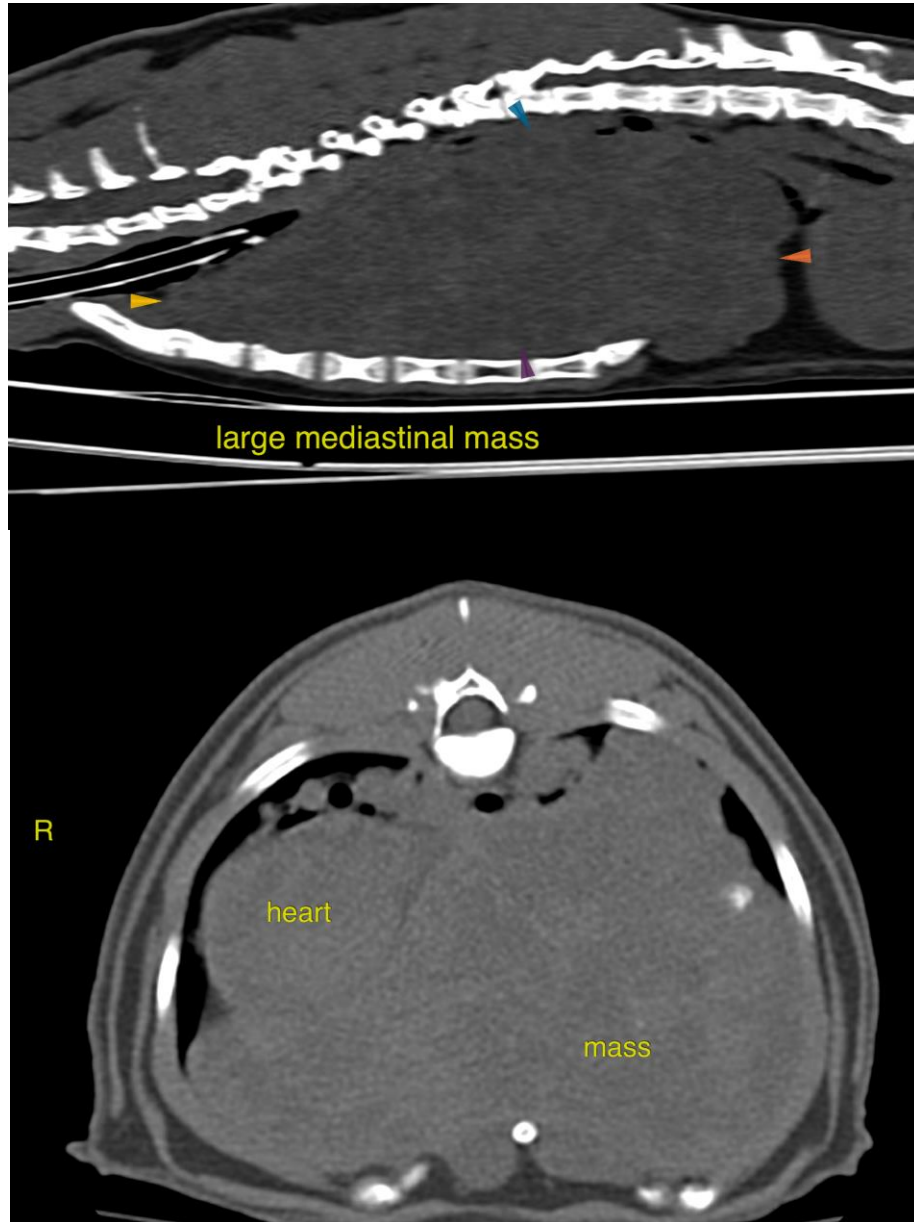
Nele Eley, DVM  
Dr. med. Vet. DipECVDI

**HOSPITAL NAME**

Colyton Veterinary  
Hospital

**REFERRING VET**

Daisy Fung



**INVOICE**

56241

**DATE**

1-18-23

The information and recommendations provided are based on the images presented by the referring veterinarian/sonographer. No evaluation can be communicated regarding pathology that was not visible in the image/video clips provided.

Thank you for this referral. If the clinical or image interpretation does not parallel your findings or if I can be of any further assistance please contact me.

**Nele Eley**, DVM, Dr. med. vet., DipECVDI  
European Specialist in Veterinary Diagnostic Imaging, Cert. Radiology,  
Senior lecturer University of Giessen, Germany, Veterinary Faculty, Department of Radiology



**PATIENT**

Nele.Eley@sonopath.com

Smokey Andrew

**SPECIES**

Feline

**BREED**

DMH

**SEX**

FN

**AGE**

15

**INTERPRETED BY**

Nele Eley, DVM  
Dr. med. Vet. DipECVDI

**HOSPITAL NAME**

Colyton Veterinary  
Hospital

**REFERRING VET**

Daisy Fung

**INVOICE**

56241

**DATE**

1-18-23