

PATIENT

Mimi Buchanan

PRESENTING CLINICAL SIGNS

Cough with gag going on for 2 weeks on and off, no vomiting while gagging or coughing. Eating and drinking nml No Vomiting, Diarrhea, Sneezing

SPECIES

Canine

RADIOGRAPHIC STUDY OF THE THORAX

Right/left lateral and dorsoventral views of the thorax totaling 3 images available for review.

BREED

Poodle Mix

RADIOGRAPHIC FINDINGS

There is moderate left sided cardiomegaly with loss of the caudal cardiac waist and left atrial tenting. Basico-apical enlargement of the cardiac silhouette leads to lifting of the trachea. Bronchial splitting is seen secondary to the left atrial enlargement. The vertebral heart score is 12.2. Pulmonary venous congestion and cardiogenic pulmonary edema are seen accentuating the perihilar and caudal lung.

SEX

FS

Mild generalized enlargement of the liver appears to be present. However, the degree of pulmonary inflation is deep and may contribute to the caudal position of the liver.

AGE

10 Years

Mild gastric aerophagia is noted.

There is no evidence of dynamic tracheal disease or mediastinal widening.

Mild spondyloses are noted between T5/6 and T3/4.

INTERPRETED BY

Nele Eley, DVM
Dr. med. Vet. DipECVDI

RADIOGRAPHIC DIAGNOSIS

- Moderate left sided cardiomegaly with volume overload and congestive heart failure/cardiogenic pulmonary edema.

HOSPITAL NAME

Golden Isles Animal Hospital

INTERPRETATION OF THE FINDINGS & FURTHER RECOMMENDATIONS

The radiographic findings are compatible with cardiogenic pulmonary edema. Significant left sided cardiomegaly is seen with left atrial enlargement. Chronic mitral valve regurgitation secondary to endocardiosis is considered the most likely cause of the cardiac failure. Further definition by means of a full cardiac echo could be considered.

REFERRING VET

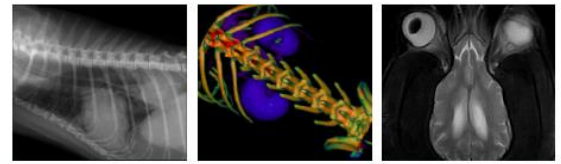
James Hornbuckle

INVOICE

56224

DATE

1-18-23



PATIENT

Mimi Buchanan

SPECIES

Canine

BREED

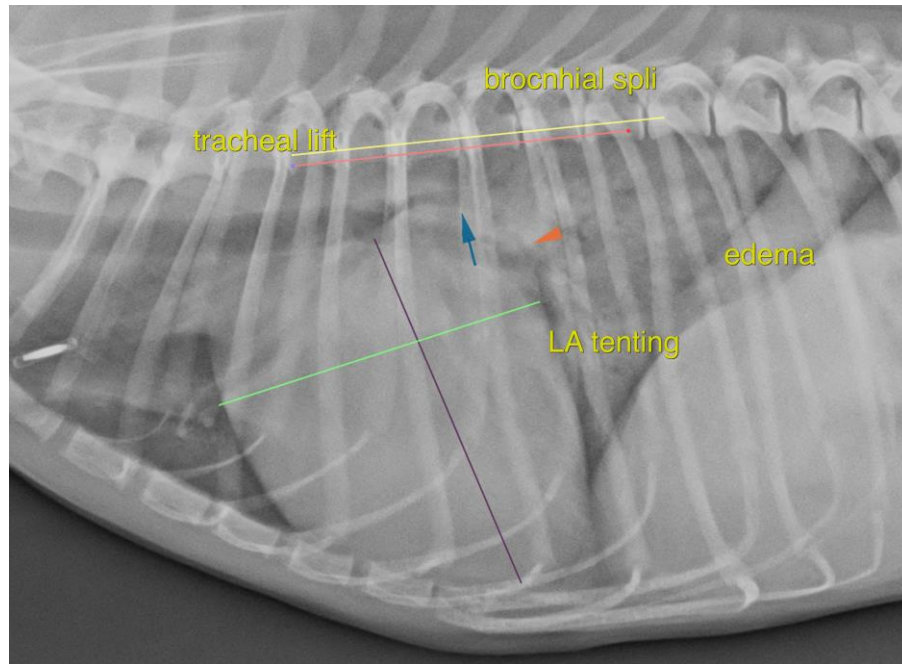
Poodle Mix

SEX

FS

AGE

10 Years



INTERPRETED BY

Nele Eley, DVM
Dr. med. Vet. DipECVDI

The information and recommendations provided are based on the images presented by the referring veterinarian/sonographer. No evaluation can be communicated regarding pathology that was not visible in the image/video clips provided.

HOSPITAL NAME

Golden Isles Animal
Hospital

Thank you for this referral. If the clinical or image interpretation does not parallel your findings or if I can be of any further assistance please contact me.

Nele Eley, DVM, Dr. med. vet., DipECVDI
European Specialist in Veterinary Diagnostic Imaging, Cert. Radiology,
Senior lecturer University of Giessen, Germany, Veterinary Faculty, Department of Radiology
Nele.Eley@sonopath.com

REFERRING VET

James Hornbuckle

INVOICE

56224

DATE

1-18-23