

**PATIENT PRESENTING CLINICAL SIGNS**

Liezel Letson Rule out intracranial Dz. Owner reports at least 2 episodes of head tremors.

COMPUTED TOMOGRAPHIC STUDY OF THE HEAD**SPECIES**

Plain and post contrast studies available for review.

Canine

COMPUTED TOMOGRAPHIC FINDINGS**BREED**

The patient has a brachycephalic head conformation with shortened facial bones, rounded dome shaped neurocranium, and a small open fontanelle.

Pomeranian

The atlantoaxial and atlantooccipital junctions present within the expected limits for a brachycephalic dog.

SEX

Female

Mild bilateral lateral ventriculomegaly without evidence of active distension of the ventricular system is seen. The third and fourth ventricles present within normal limits. No significant supracollicular fluid accumulation is seen. The neuroparenchyma's attenuation and enhancement as well as the meningeal enhancement present within the expected limits.

AGE

10 Months

COMPUTED TOMOGRAPHIC DIAGNOSIS

- Mild lateral ventriculomegaly; otherwise, normal CT findings of the brain.

INTERPRETATION OF FINDINGS & FURTHER RECOMMENDATIONS**INTERPRETED BY**

Nele Eley (Ondreka),
DVM Dr. med. vet.,
DipECVDI

The enlargement of the lateral ventricles is mild and considered within the expected limits for a brachycephalic dog. No obvious signs of hydrocephalous or active distension of the ventricular system are seen. Primary epilepsy appears to be a potential differential diagnosis. However, complementary csf analysis should be considered in order to rule out infectious or inflammatory brain disease as underlying cause of the head tremors/seizural activity.

HOSPITAL NAME

Mobile Pet Imaging

REFERRING VET

Meaux

INVOICE

56240

DATE

1-18-23



PATIENT

Liezel Letson

SPECIES

Canine

BREED

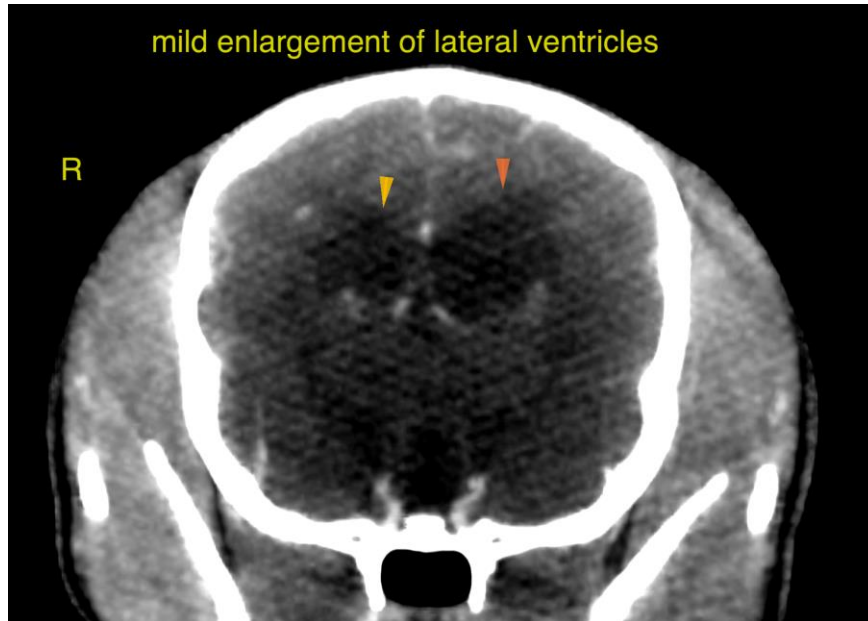
Pomeranian

SEX

Female

AGE

10 Months



The information and recommendations provided are based on the images presented by the referring veterinarian. No evaluation can be communicated regarding pathology that was not visible in the image/video clips provided.

INTERPRETED BY

Nele Eley (Ondreka),
DVM Dr. med. vet.,
DipECVDI

Thank you for this referral. If the clinical or image interpretation does not parallel your findings or if I can be of any further assistance please contact me.

Nele Eley (Ondreka), DVM, Dr. med. vet., DipECVDI
European Specialist in Veterinary Diagnostic Imaging, Cert. Radiology,
Senior lecturer University of Giessen/Germany, Veterinary Faculty, Department of Radiology.
Nele.Eley@sonopath.com

HOSPITAL NAME

Mobile Pet Imaging

REFERRING VET

Meaux

INVOICE

56240

DATE

1-18-23