

**PATIENT**

Pumpkin Pazik

PRESENTING CLINICAL SIGNS

Excessive vomiting the last few days. Need to rule out foreign body.

SPECIES

Feline

RADIOGRAPHIC STUDY OF THE ABDOMEN

Right/left lateral and ventrodorsal views totaling 4 images available for review.

BREED

Tabby

The surrounding bony structures are within normal limits.

SEX

Female Spayed

The serosal detail is maintained throughout the peritoneal and retroperitoneal space.

AGE

2 Years

The liver is appropriate in position, size and presents uniform opacity.

The splenic head is in the anticipated position and within normal limits for size and opacity. The splenic tail is not seen.

Both kidneys are seen and present with normal size, shape, delineation and opacity. The urinary bladder is in its anticipated position. No radiopaque calculi are noted throughout the upper and lower urinary tract.

INTERPRETED BYNele Eley, DVM
Dr. med. Vet. DipECVDI

The stomach is empty.

The small intestinal loops are evenly distributed throughout the mid abdomen. No evidence of plication, abnormal dilation, or radiopaque foreign material is seen. Small amounts of gas are seen within the small intestine.

HOSPITAL NAMETruscott Animal
Hospital

The colon contains a mild to moderate amount of fecal material.

RADIOGRAPHIC DIAGNOSIS

- No radiographic evidence of mechanical ileus.

REFERRING VET

Medhat Meawad

INTERPRETATION OF THE FINDINGS & FURTHER RECOMMENDATIONS

The radiographic study reveals no evidence of mechanical ileus. Functional ileus and subileus remain a potential and their potential presence could be verified by means of abdominal ultrasound in case of persistent clinical signs.

INVOICE

49658

DATE

1-18-22



PATIENT

Pumpkin Pazik

SPECIES

Feline

BREED

Tabby

SEX

Female Spayed

AGE

2 Years

INTERPRETED BY

Nele Eley, DVM
Dr. med. Vet. DipECVDI

HOSPITAL NAME

Truscott Animal
Hospital

REFERRING VET

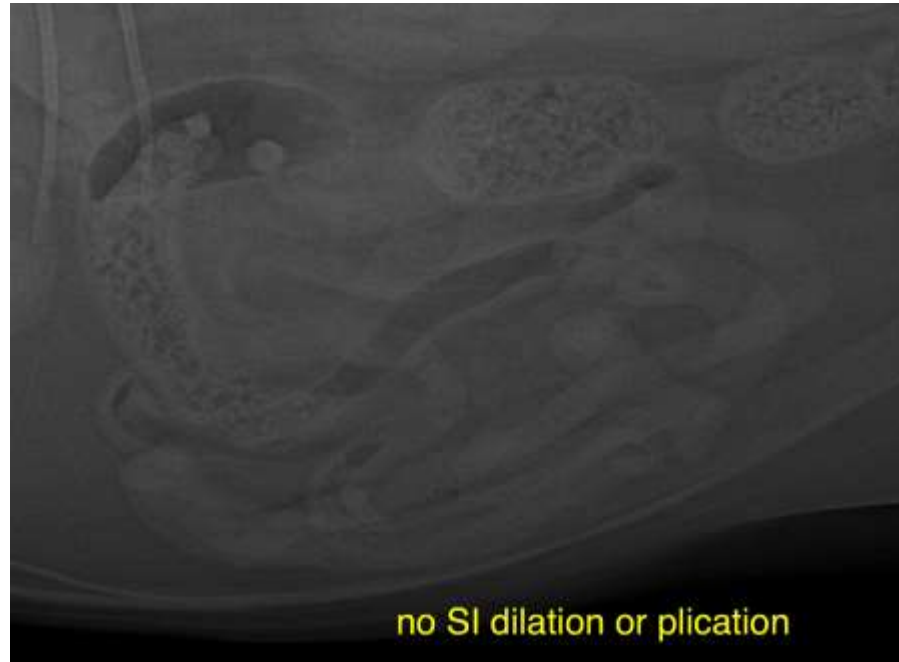
Medhat Meawad

INVOICE

49658

DATE

1-18-22



The information and recommendations provided are based on the images presented by the referring veterinarian. No evaluation can be communicated regarding pathology that was not visible in the image/video clips provided.

Thank you for this referral. If the clinical or image interpretation does not parallel your findings or if I can be of any further assistance please contact me.

Nele Eley, DVM, Dr. med. vet., DipECVDI
European Specialist in Veterinary Diagnostic Imaging, Cert. Radiology,
Senior lecturer University of Giessen, Germany, Veterinary Faculty, Department of Radiology
Nele.Eley@sonopath.com