



PATIENT

Leah Bachart

PRESENTING CLINICAL SIGNS

Pet has been limping on right front leg for several months but last 2 weeks has become much worse.

SPECIES

Canine

Abnormal PE/Chem/CBC/UA Results: Right carpus is thickened vs left. P has greater carpal valgus on R vs L as well. Initial pain reaction R carpus when first palpated, the no reaction. Heart murmur found during exam. O was not aware but it was recorded as grade II last year. Grade III to IV now. Would like heart assessed for enlargement or changes and lungs, rest of thorax.

BREED

Basset Hound

RADIOGRAPHIC STUDY OF THE THORAX

Right lateral and ventrodorsal views totaling 3 images available for review.

RADIOGRAPHIC FINDINGS

SEX

SF

A small intramuscular lipoma appears to be present ventral of the caudal sternum.

AGE

13 Years, 5 Months

The degree of pulmonary inflation is fair. A moderate generalized bronchial lung pattern is seen. Occasional peribronchial cuffing is noted. There are several age related incidental pulmonary osteomas accentuating the cranioventral lung field. No evidence of interstitial nodules or masses is seen.

There is no evidence of abnormal mediastinal widening.

Course and width of the trachea are considered within normal limits.

INTERPRETED BY

Nele Eley, DVM
Dr. med. Vet. DipECVDI

The cardiac silhouette reveals no overall enlargement and no specific chamber enlargement. The vertebral heart score is 10.4. No evidence of congestive heart failure is seen.

The stomach is post-prandial.

HOSPITAL NAME

Grove Veterinary
Clinic

RADIOGRAPHIC DIAGNOSIS

- Normal radiographic presentation of the cardiac silhouette.
- Bronchial lung pattern.
- No evidence of pulmonary metastatic disease.

REFERRING VET

Dr. Luna

INTERPRETATION OF THE FINDINGS & FURTHER RECOMMENDATIONS

The radiographic presentation of the cardiac silhouette is within normal limits. Most early stages of cardiac pathology are radiographically occult. Assessment of the cause of the heart murmur by means of a full cardiac echo could be considered. However, at this time, there is no evidence of congestive heart failure or cardiomegaly.

INVOICE

49652

The radiographic presentation of the lung may be within age related normal limits. However, low grade chronic lower airway disease such as eosinophilic or irritant bronchopneumopathy or infectious bronchitis cannot be ruled out entirely. Correlate with the clinical examination to determine the need for further definition.

DATE

1-18-22



PATIENT

Leah Bachart

SPECIES

Canine

BREED

Basset Hound

SEX

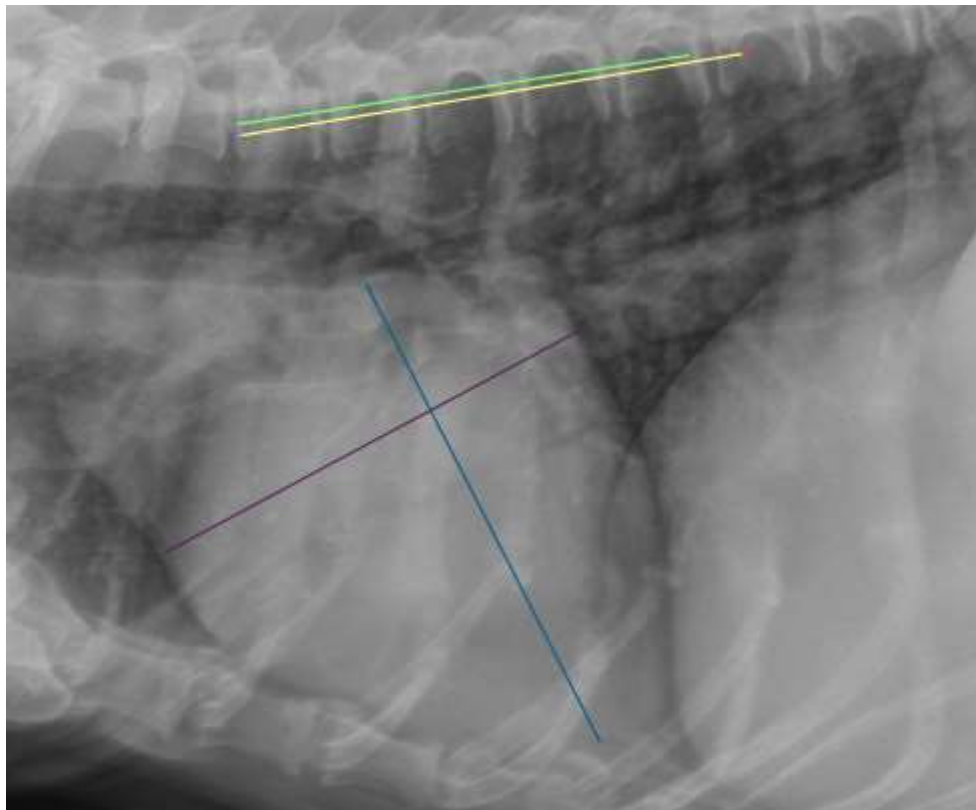
SF

AGE

13 Years, 5 Months

INTERPRETED BY

Nele Eley, DVM
Dr. med. Vet. DipECVDI



HOSPITAL NAME

Grove Veterinary
Clinic

REFERRING VET

Dr. Luna

INVOICE

49652

DATE

1-18-22

The information and recommendations provided are based on the images presented by the referring veterinarian. No evaluation can be communicated regarding pathology that was not visible in the image/video clips provided.

Thank you for this referral. If the clinical or image interpretation does not parallel your findings or if I can be of any further assistance please contact me.

Nele Eley, DVM, Dr. med. vet., DipECVDI
European Specialist in Veterinary Diagnostic Imaging, Cert. Radiology,
Senior lecturer University of Giessen, Germany, Veterinary Faculty, Department of Radiology
Nele.Eley@sonopath.com