

PATIENT

Harley Ruggiero

PRESENTING CLINICAL SIGNS

Vomiting daily for 3-4 days. History of chewing up toys.

SPECIES

Canine

RADIOGRAPHIC STUDY OF THE ABDOMEN

Right/left lateral and ventrodorsal views totaling 3 images available for review.

BREED

German Shepherd

RADIOGRAPHIC FINDINGS

The surrounding bony structures are within normal limits.

SEX

Male

No abnormalities of the extraabdominal soft tissues are noted. The abdominal wall is smooth and thin.

The serosal detail is maintained throughout the peritoneal and retroperitoneal space.

The liver is appropriate in position, size and presents uniform opacity.

AGE

7 Months

The splenic head is in the anticipated position and within normal limits for size and opacity. The splenic body and tail are considered normal for position, size, shape and opacity.

Both kidneys are seen and present with normal size, shape, delineation and opacity. The urinary bladder is in its anticipated position. No radiopaque calculi are noted throughout the upper and lower urinary tract.

INTERPRETED BY

Nele Eley, DVM
Dr. med. Vet. DipECVDI

The stomach presents mild aerophagia with no evidence of malpositioning or dilation.

There appears to be mild segmental dilation of the small intestine with a nondilated population of small intestinal loops being further caudal in the abdomen and containing gas.

HOSPITAL NAME

Four Corners
Veterinary Practice

The colon contains a moderate amount of fecal matter.

RADIOGRAPHIC DIAGNOSIS

- Small intestinal maldigestion pattern with suspect mild segmental dilation.

REFERRING VET

Melina Maritato

INTERPRETATION OF THE FINDINGS & FURTHER RECOMMENDATIONS

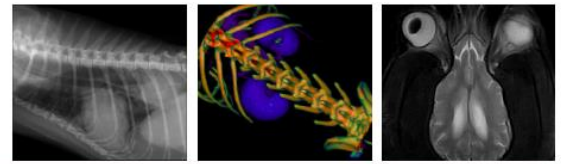
Differential diagnosis for the mild segmental dilation of the small intestine includes functional ileus versus mechanical subileus. Foreign material or plication is not directly seen. Further definition by means of abdominal ultrasound is strongly recommended if not performed already in case of persisting clinical signs.

INVOICE

56207

DATE

1-17-23



PATIENT

Harley Ruggiero

SPECIES

Canine

BREED

German Shepherd

SEX

Male

AGE

7 Months

INTERPRETED BY

Nele Eley, DVM
Dr. med. Vet. DipECVDI

HOSPITAL NAME

Four Corners
Veterinary Practice

REFERRING VET

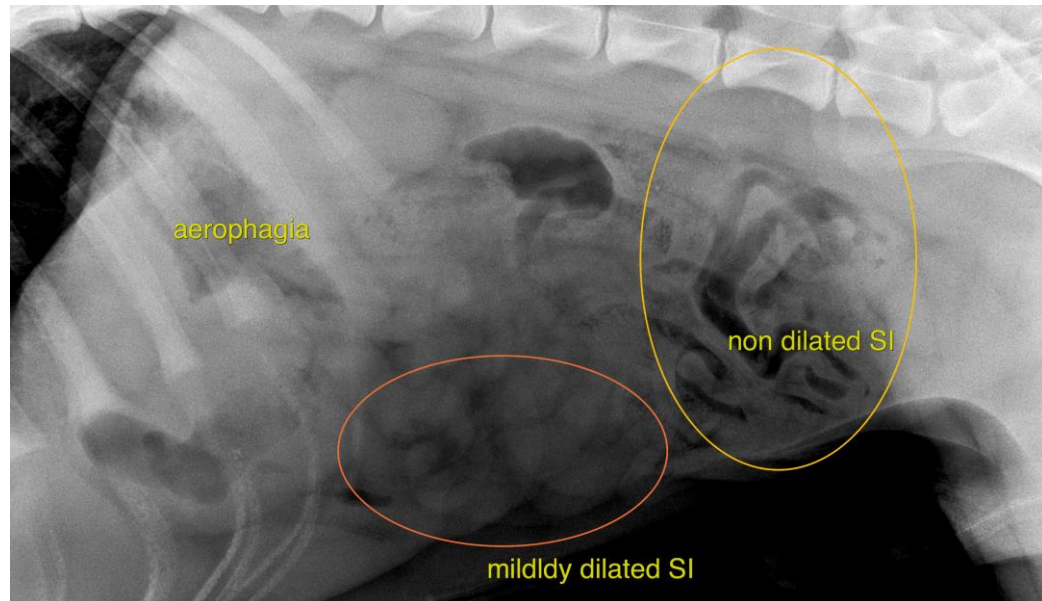
Melina Maritato

INVOICE

56207

DATE

1-17-23



The information and recommendations provided are based on the images presented by the referring veterinarian/sonographer. No evaluation can be communicated regarding pathology that was not visible in the image/video clips provided.

Thank you for this referral. If the clinical or image interpretation does not parallel your findings or if I can be of any further assistance please contact me.

Nele Eley, DVM, Dr. med. vet., DipECVDI
European Specialist in Veterinary Diagnostic Imaging, Cert. Radiology,
Senior lecturer University of Giessen, Germany, Veterinary Faculty, Department of Radiology
Nele.Eley@sonopath.com