



PATIENT

Typhoon House

PRESENTING CLINICAL SIGNS

sent ultrasound in with images

SPECIES

Canine

RADIOGRAPHIC STUDY OF THE ABDOMEN

Right/left lateral and ventrodorsal views totaling 3 images available for review.

BREED

Pitbull

RADIOGRAPHIC FINDINGS

Mild L3/4 spondylosis deformans and vertebral end plate sclerosis is seen.

SEX

MN

The abdominal cavity is voluminous.

There is moderate and presumably generalized splenomegaly with a mass effect in the cranial and mid abdomen.

The regional serosal detail appears to be reduced.

Mild dorsal deviation of the stomach is seen. There is mild gastric aerophagia.

AGE

7 Years

The small intestinal loops present aerophagia but are evenly distributed throughout the mid abdomen without evidence of abnormal dilation, plication, or radiopaque foreign material.

The colon contains a mild amount of fecal matter only and the ascending and transverse colon contains gas.

INTERPRETED BY

Nele Eley, DVM
Dr. med. Vet. DipECVDI

RADIOGRAPHIC DIAGNOSIS

- Splenomegaly.
- Focally reduced serosal detail.
- Gastrointestinal aerophagia.

HOSPITAL NAME

Yorkville Animal
Hospital

INTERPRETATION OF THE FINDINGS & FURTHER RECOMMENDATIONS

The radiographic study reveals no evidence of mechanical ileus. The gastrointestinal aerophagia is an unspecific sign which may be associated with gastroenteropathy; however, can also be caused by pain, general excitement, and dyspnea.

REFERRING VET

Dr. Oedwaldt

The main finding appears to be the generalized enlargement of the spleen. Differential diagnosis includes idiopathic hypersplenism, congestion, diffuse infiltrative disease, extramedullary hematopoiesis, splenitis, and other. Consider further definition by means of ultrasound with eventual parenchymal sampling if not performed already.

INVOICE

49601

The reduced serosal detail can be attributed to the mass effect of the spleen within the cranial and mid abdomen. However, small amounts of effusion or regional peritonitis cannot be ruled out entirely.

DATE

1-17-22



PATIENT

Typhoon House

SPECIES

Canine

BREED

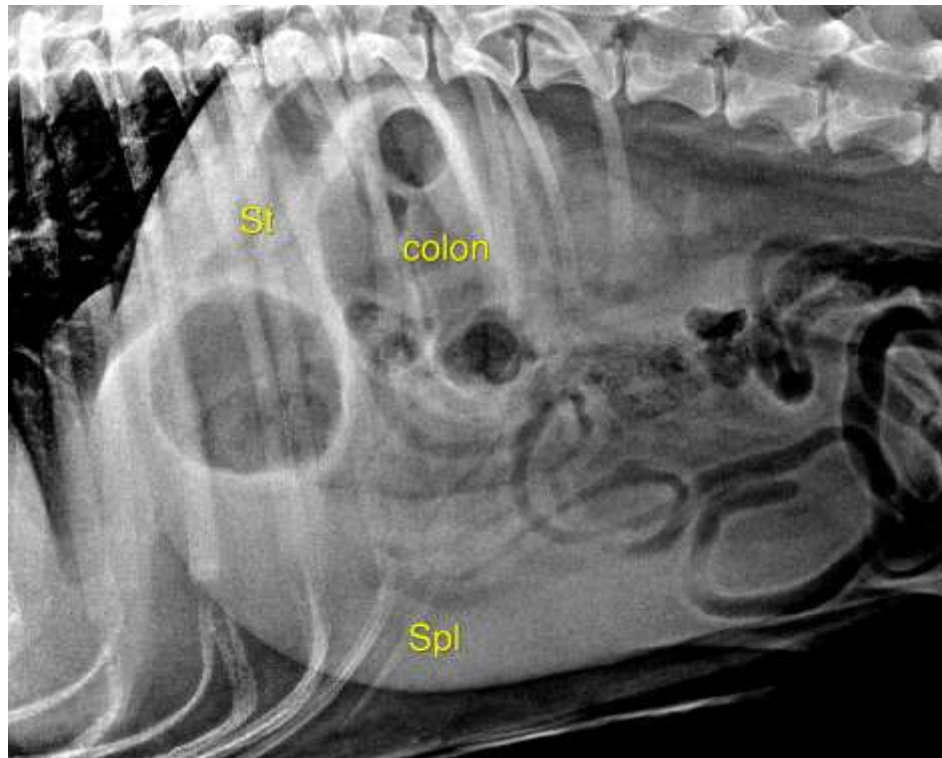
Pitbull

SEX

MN

AGE

7 Years



INTERPRETED BY

Nele Eley, DVM
Dr. med. Vet. DipECVDI

The information and recommendations provided are based on the images presented by the referring veterinarian. No evaluation can be communicated regarding pathology that was not visible in the image/video clips provided.

HOSPITAL NAME

Yorkville Animal
Hospital

Thank you for this referral. If the clinical or image interpretation does not parallel your findings or if I can be of any further assistance please contact me.

Nele Eley, DVM, Dr. med. vet., DipECVDI
European Specialist in Veterinary Diagnostic Imaging, Cert. Radiology,
Senior lecturer University of Giessen, Germany, Veterinary Faculty, Department of Radiology
Nele.Eley@sonopath.com

REFERRING VET

Dr. Oedwaldt

INVOICE

49601

DATE

1-17-22