

**PATIENT**

Kiko Campos-Torres

PRESENTING CLINICAL SIGNS

Kiko ate a magnet Tuesday of last week. Ashley gave him some hydrogen peroxide to try to make him throw up after eating a magnet. It was the size of the nickel and Kiko did not throw up.

SPECIES

Canine

RADIOGRAPHIC STUDY OF THE ABDOMEN

Right/left lateral and ventrodorsal views totaling 4 images available for review.

BREED

Akita

RADIOGRAPHIC FINDINGS

The radiographic study shows a circular 2.5 cm sized structure within varying positions within the gastric body and pyloric antrum of the stomach. A mild amount of food is present within the stomach as well.

SEX

Male

The descending duodenum contains a mild amount of gas and is rigid in appearance. The small intestinal loops present gas content without evidence of abnormal dilation or plication.

The colon presents within normal limits.

AGE

1 Year, 2 Months

RADIOGRAPHIC DIAGNOSIS

- Presence of radiopaque foreign material within the stomach compatible with the history of ingestion of a magnet.

INTERPRETED BY

Nele Eley, DVM
Dr. med. Vet. DipECVDI

INTERPRETATION OF THE FINDINGS & FURTHER RECOMMENDATIONS

The radiographic study reveals the ingested magnet in varying positions within the stomach. Based on the radiographic appearance, it should be possible to remove the magnet by inducing vomiting. However, since the patient may pass this foreign object through the pylorus at any time, recheck radiographs should be obtained immediately prior to inducing vomiting if that has not been performed already.

HOSPITAL NAME

Elizabeth Animal
Hospital

REFERRING VET

Sareena Enloe, DVM

INVOICE

49619

DATE

1-17-22



PATIENT

Kiko Campos-Torres

SPECIES

Canine

BREED

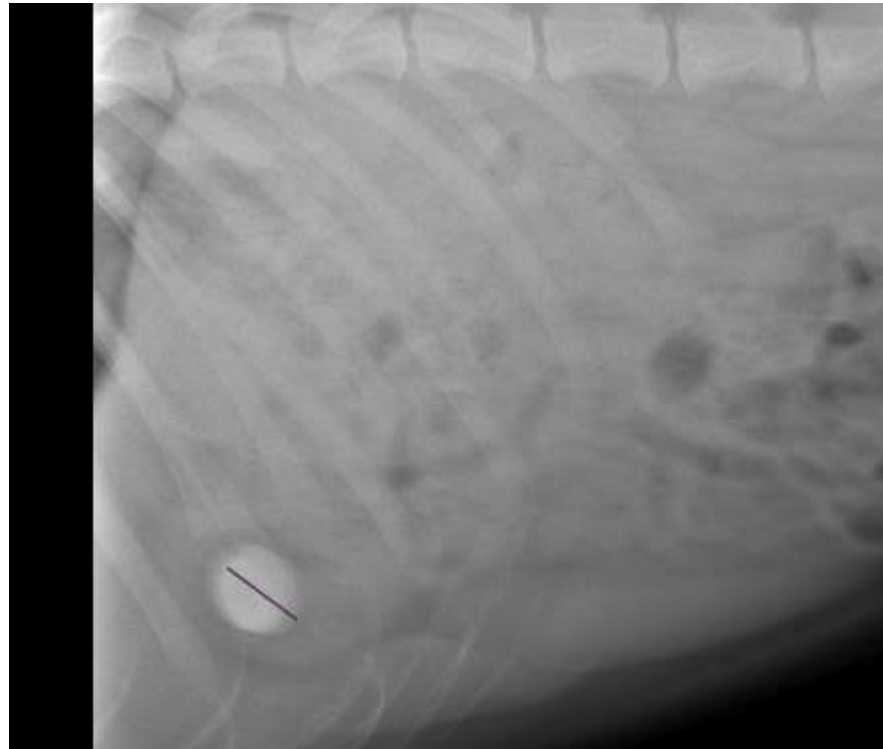
Akita

SEX

Male

AGE

1 Year, 2 Months



INTERPRETED BY

Nele Eley, DVM
Dr. med. Vet. DipECVDI

The information and recommendations provided are based on the images presented by the referring veterinarian. No evaluation can be communicated regarding pathology that was not visible in the image/video clips provided.

HOSPITAL NAME

Elizabeth Animal
Hospital

Thank you for this referral. If the clinical or image interpretation does not parallel your findings or if I can be of any further assistance please contact me.

Nele Eley, DVM, Dr. med. vet., DipECVDI
European Specialist in Veterinary Diagnostic Imaging, Cert. Radiology,
Senior lecturer University of Giessen, Germany, Veterinary Faculty, Department of Radiology
Nele.Eley@sonopath.com

REFERRING VET

Sareena Enloe, DVM

INVOICE

49619

DATE

1-17-22