



PATIENT

MacDunne

PRESENTING CLINICAL SIGNS

Coughing once per day for approximately 2 weeks. No other clinical symptoms. O describes a dry, non-productive cough.

SPECIES

Feline

RADIOGRAPHIC STUDY OF THE THORAX

Right/left lateral and ventrodorsal views of the thorax totaling 3 images available for review.

BREED

DSH

RADIOGRAPHIC FINDINGS

The degree of pulmonary inflation is moderate. A moderate generalized bronchial lung pattern with mild caudodorsal accentuation and peribronchial cuffing is noted.

Course and width of the trachea are considered within normal limits.

SEX

MN

The cardiac silhouette presents within normal limits. The vertebral heart score is 7.5. No evidence of specific chamber enlargement is noted.

There is no evidence of mediastinal widening or mediastinal lymphadenomegaly.

AGE

8 Years, 8 Months

The thoracic boundaries present within normal limits.

The stomach is postprandial and presents mild aerophagia.

INTERPRETED BY

Nele Eley, DVM
Dr. med. Vet. DipECVDI

RADIOGRAPHIC DIAGNOSIS

- Moderate caudodorsally accentuated bronchial lung pattern.
- Normal radiographic presentation of the cardiovascular structures.

HOSPITAL NAME

Heartland Pet
Hospital

INTERPRETATION OF THE FINDINGS & FURTHER RECOMMENDATIONS

The radiographic study reveals a bronchial lung pattern. Lower airway disease such as allergic lower airway syndrome or infectious bronchitis including viral, bacterial, parasitic, or protozoal are potential differential diagnoses. Airway endoscopy with airway sampling would be ideal for further definition. A clinical trial of treatment for feline asthma could be considered an alternative should endoscopy not be an option.

REFERRING VET

Dr. Nick Hellbusch

INVOICE

56185

DATE

1-16-23



PATIENT

MacDunne

SPECIES

Feline

BREED

DSH

SEX

MN

AGE

8 Years, 8 Months

INTERPRETED BY

Nele Eley, DVM
Dr. med. Vet. DipECVDI

HOSPITAL NAME

Heartland Pet
Hospital

REFERRING VET

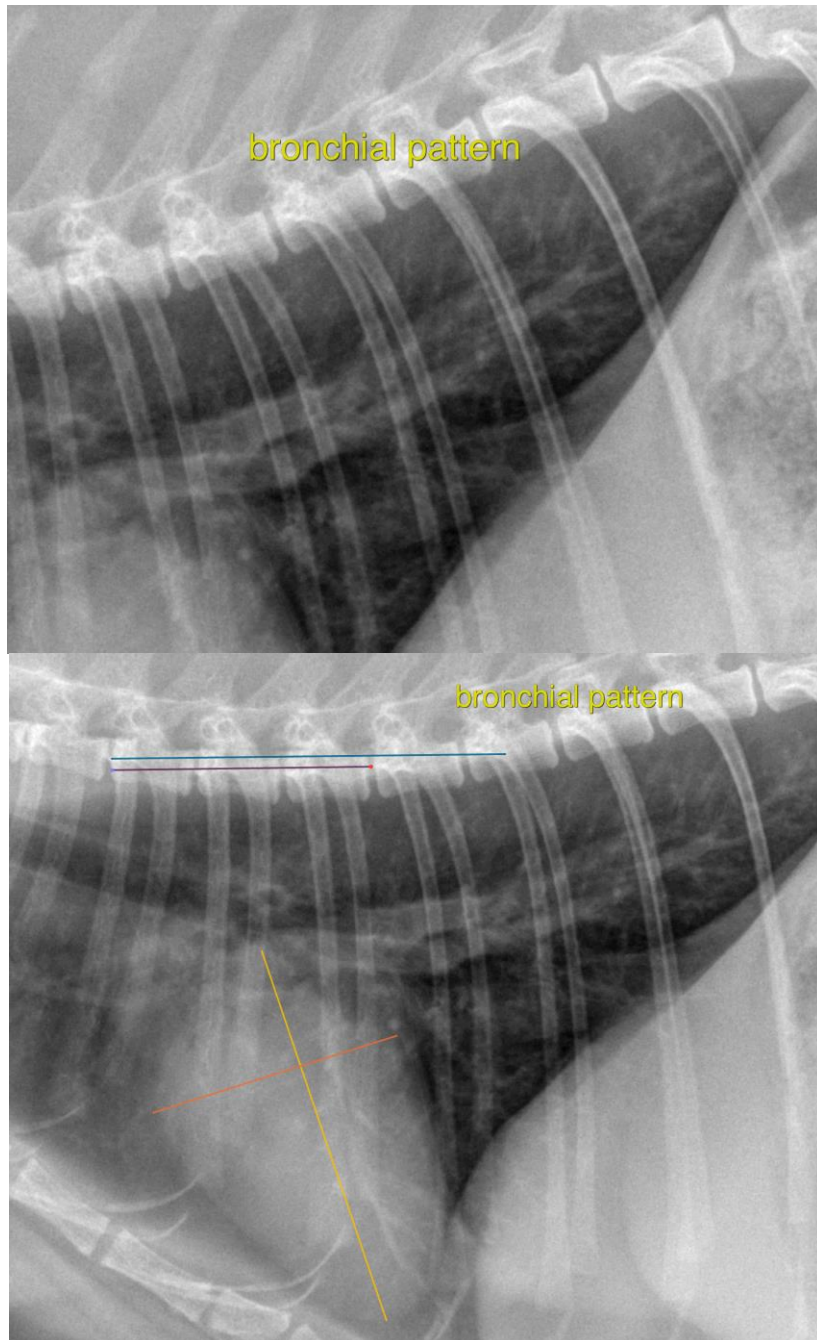
Dr. Nick Hellbusch

INVOICE

56185

DATE

1-16-23





PATIENT

Mac Dunne

The information and recommendations provided are based on the images presented by the referring veterinarian/sonographer. No evaluation can be communicated regarding pathology that was not visible in the image/video clips provided.

Thank you for this referral. If the clinical or image interpretation does not parallel your findings or if I can be of any further assistance please contact me.

SPECIES

Feline

Nele Eley, DVM, Dr. med. vet., DipECVDI
European Specialist in Veterinary Diagnostic Imaging, Cert. Radiology,
Senior lecturer University of Giessen, Germany, Veterinary Faculty, Department of Radiology
Nele.Eley@sonopath.com

BREED

DSH

SEX

MN

AGE

8 Years, 8 Months

INTERPRETED BY

Nele Eley, DVM
Dr. med. Vet. DipECVDI

HOSPITAL NAME

Heartland Pet
Hospital

REFERRING VET

Dr. Nick Hellbusch

INVOICE

56185

DATE

1-16-23