



PATIENT PRESENTING CLINICAL SIGNS

Lila McDonald please compare MRI images from January 12, 2022 (sent separate request and forgot to add to compare) to MRI performed February 7, 2020

SPECIES MAGNETIC RESONANCE IMAGING FINDINGS

Canine **Cervical Spine**

BREED

GSD

Moderate intervertebral disc protrusion, spondylosis deformans, intervertebral disc degeneration, and left sided facet joint hypertrophy are seen between C5 and C6.

Moderate to severe protrusion, intervertebral disc disease with collapse of the intervertebral disc space, and vertebral end plate sclerosis, as well as spondylosis deformans and moderate to severe bilateral facet joint hypertrophy are present between C6 and C7.

SEX

FS

Mild focal spinal cord hyperintensity is seen between C5 and C6. The left neuroforamen is narrowed.

AGE

8

Moderate regional spinal cord hyperintensity and reduced diameter of the spinal cord are present between C6 and C7 and both neuroforamina are narrowed.

Minimal intervertebral disc protrusion is present between C4 and C5.

Minimal protrusions are also seen from T2 through T7.

INTERPRETED BY

Nele Eley, DVM
Dr. med. Vet. DipECVDI

Left Brachial Plexus

The left brachial plexus presents within normal limits.

HOSPITAL NAME

Animal Health
Partners

Left Shoulder

Moderate atrophy of the left shoulder musculature is noted.

There is moderate to severe effusion of the left shoulder joint with moderate generalized thickening of the synovium. A mild amount of periarticular osteophytes are seen.

REFERRING VET

Dr. Marchal

There appears to be an isolated ossicle of the infraglenoid tubercle. Moderate bony exostosis is present within the intertubercular groove of the biceps tendon. The biceps tendon presents moderate diffuse hyperintensity. Moderate to severe synovial sheath effusion with synovial membrane swelling and synovial proliferations are noted.

INVOICE

49593

The typical trilaminar appearance of the supraspinatus tendon is maintained; however, mild internal remodeling of the supraspinatus tendon is seen. There is no evidence of biceps impingement.

DATE

1-15-22

Diffuse swelling and hyperintensity of the medial joint compartment accentuating the subscapularis tendon and medial glenohumeral ligament are noted.



PATIENT Compared with prior study dated 2-7-2020:

Lila McDonald

Cervical Spine

SPECIES

Canine

Both the left shoulder and cervical spondylomyelopathy have significantly progressed; however, the rate of progression appears to be higher in the cervical spine where the initially mild C6/7 protrusion now has progressed to a moderate to severe protrusion with progressive sclerosis of the vertebral end plates and spondylosis formation as well as reduced diameter of the spinal cord with increased signal intensity.

BREED

GSD

At C5/6, there was no protrusion evident in February 2020 and moderate protrusion with spondylosis and reduced intervertebral disc space width is seen in the current study.

The hypertrophy of the facet joints at C6/7 show slight progression as well.

SEX

FS

The left sided hypertrophy at C5/6 shows mild progression.

Left Shoulder

AGE

8

The effusion, synovial swelling, biceps tenosynovitis, and medial compartment changes all reveal mild compression compared with the prior study. A thin rim of periarticular new bone is seen now as well.

There is subcutaneous soft tissue irregularity caudolateral of the right scapula with focal swelling and heterogeneous signal.

INTERPRETED BY

Nele Eley, DVM
Dr. med. Vet. DipECVDI

MAGNETIC RESONANCE IMAGING DIAGNOSIS

- Chronic caudal cervical spondylomyelopathy with chronic intervertebral disc protrusions and facet joint hypertrophy at C6/7 and C5/6.
- Suspect spinal cord gliosis at C6/7.
- Left thoracic limb muscle atrophy.
- Moderate left chronic biceps tenosynovitis.
- Moderate chronic desmopathy of the left medial glenohumeral ligament.
- Subscapularis and supraspinatus tendinopathies.
- Mild left shoulder osteoarthritis.

HOSPITAL NAME

Animal Health
Partners

REFERRING VET

Dr. Marchal

INTERPRETATION OF THE FINDINGS & FURTHER RECOMMENDATIONS

The MRI study reveals caudal cervical spondylomyelopathy with two sites of spinal cord compression. Moderate and chronic compression appears to be present between C6 and C7 with presumed spinal cord gliosis. The bilateral facet joint hypertrophy causes additional narrowing of the vertebral canal from a dorsolateral aspect resulting in an hourglass shaped stenosis.

INVOICE

49593

Similar findings are present between C5 and C6; however, less pronounced at this point. The neuroforaminal stenosis accentuates the left side between C5 and C6. The degree of compressive myelopathy appears to be mild at this point and no spinal cord atrophy or gliosis is seen yet there appears to be mild spinal cord edema.

DATE

1-15-22

The left shoulder reveals multifocal chronic injury of the rotator cuff and biceps tendon in terms of moderate chronic biceps tenosynovitis with concurrent shoulder osteoarthritis and medial



PATIENT compartment injury, which likely is degenerative in nature.

Lila McDonald Compared with the prior study dated 2-7-2020:

SPECIES The cervical spondylomyelopathy shows moderate progression with progressive gliosis of the caudal cervical spinal cord.

Canine Mild progression of the facet hypertrophy and left rotator cuff and biceps injury is present as well.

BREED The soft tissue irregularity lateral of the left shoulder may reflect scar tissue or soft tissue nodule.

GSD

SEX

FS

AGE

8

INTERPRETED BY

Nele Eley, DVM
Dr. med. Vet. DipECVDI

HOSPITAL NAME

Animal Health
Partners

REFERRING VET

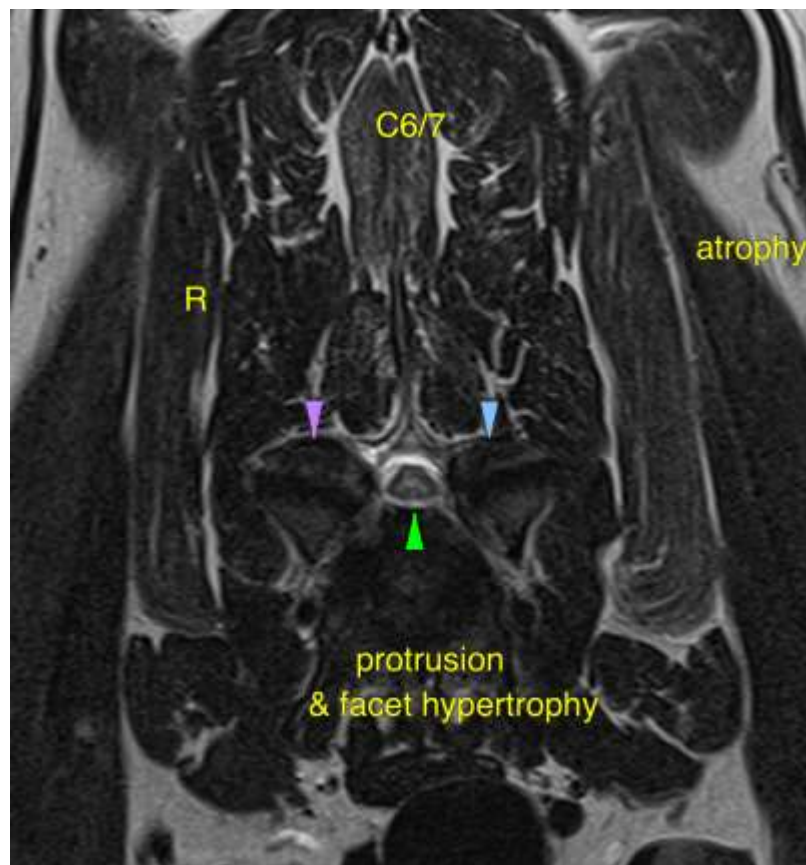
Dr. Marchal

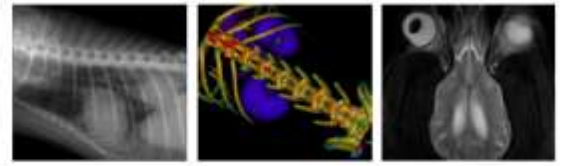
INVOICE

49593

DATE

1-15-22





PATIENT

Lila McDonald

SPECIES

Canine

BREED

GSD

SEX

FS

AGE

8

INTERPRETED BY

Nele Eley, DVM
Dr. med. Vet. DipECVDI

HOSPITAL NAME

Animal Health
Partners

REFERRING VET

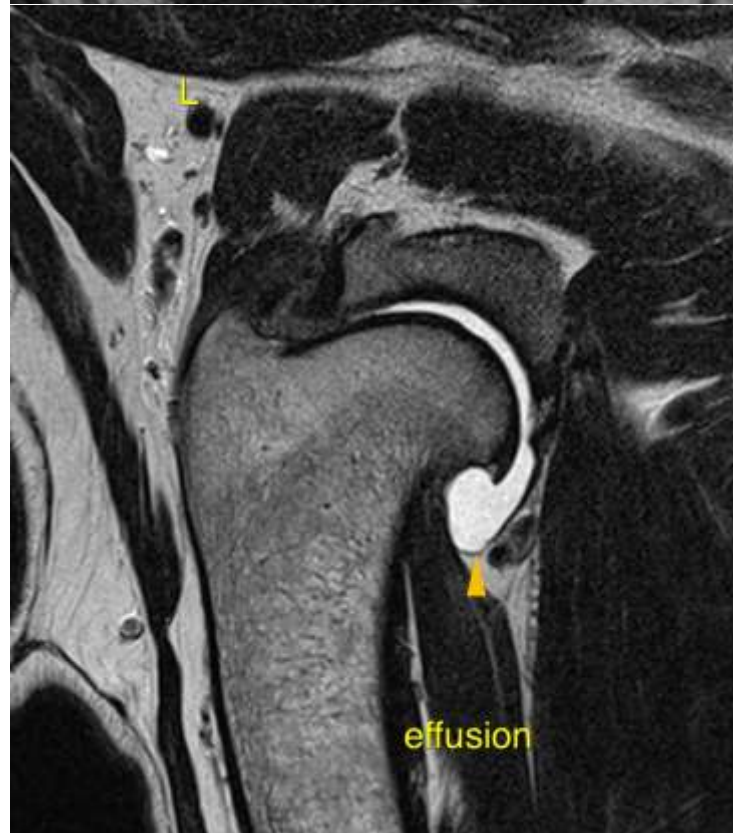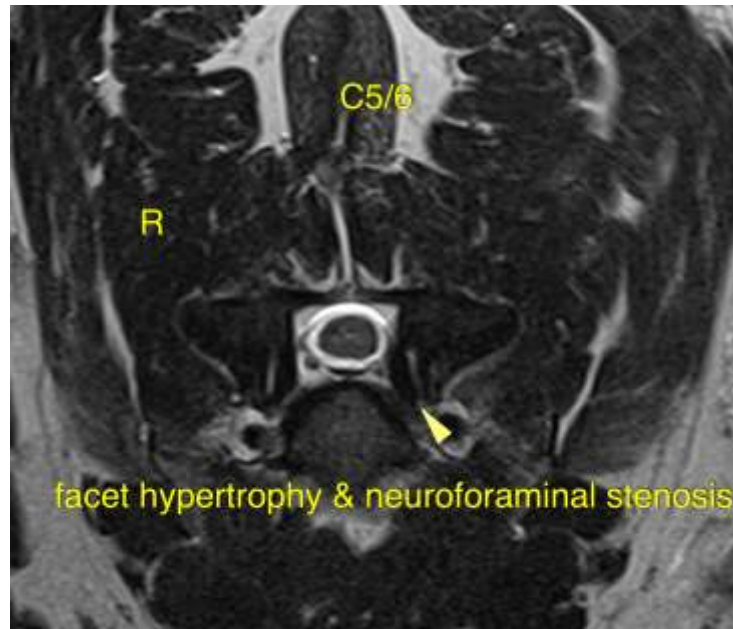
Dr. Marchal

INVOICE

49593

DATE

1-15-22





PATIENT

Lila McDonald

SPECIES

Canine

BREED

GSD

SEX

FS

AGE

8

INTERPRETED BY

Nele Eley, DVM
Dr. med. Vet. DipECVDI

HOSPITAL NAME

Animal Health
Partners

REFERRING VET

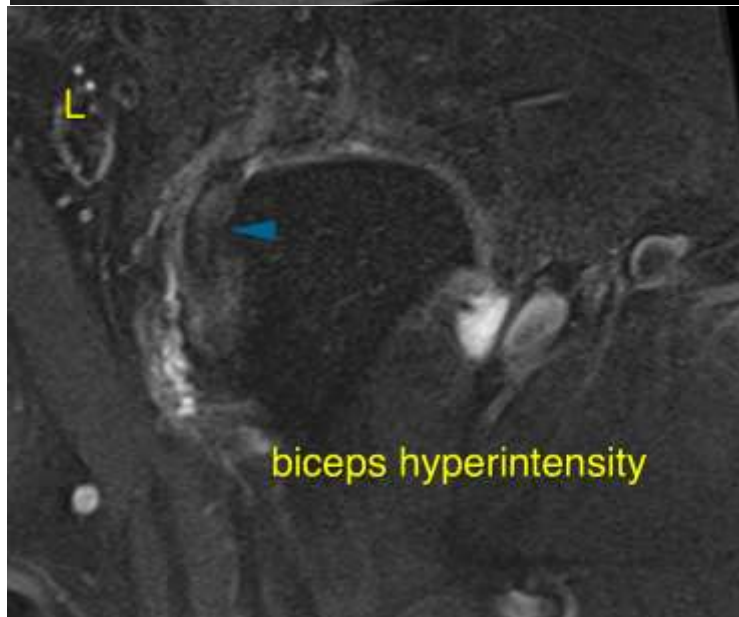
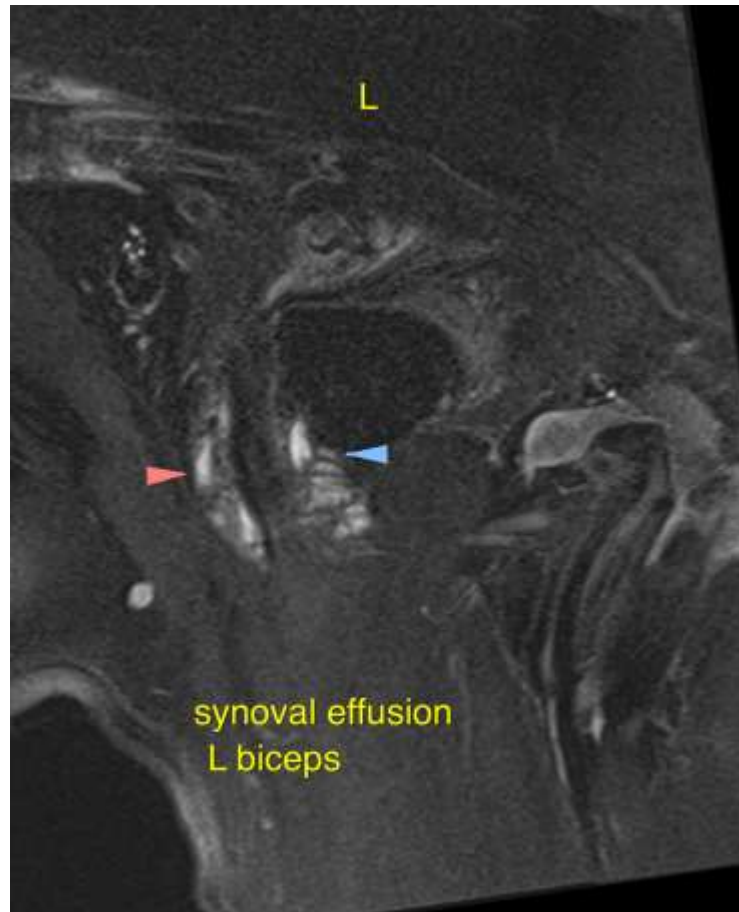Dr. Marchal

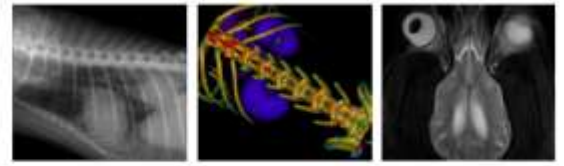
INVOICE

49593

DATE

1-15-22





PATIENT

Lila McDonald

SPECIES

Canine

BREED

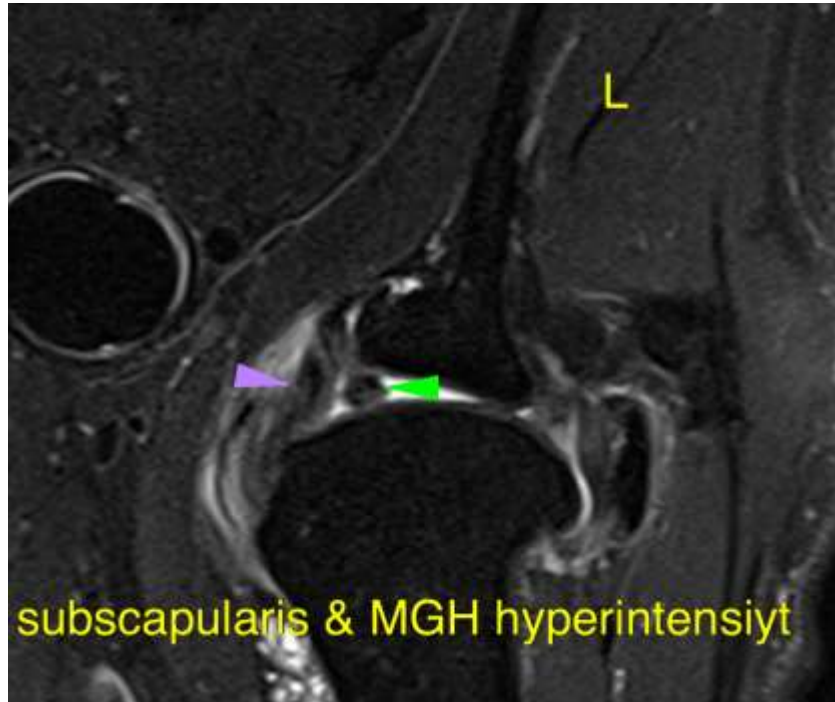
GSD

SEX

FS

AGE

8



INTERPRETED BY

Nele Eley, DVM
Dr. med. Vet. DipECVDI

HOSPITAL NAME

Animal Health
Partners

REFERRING VET

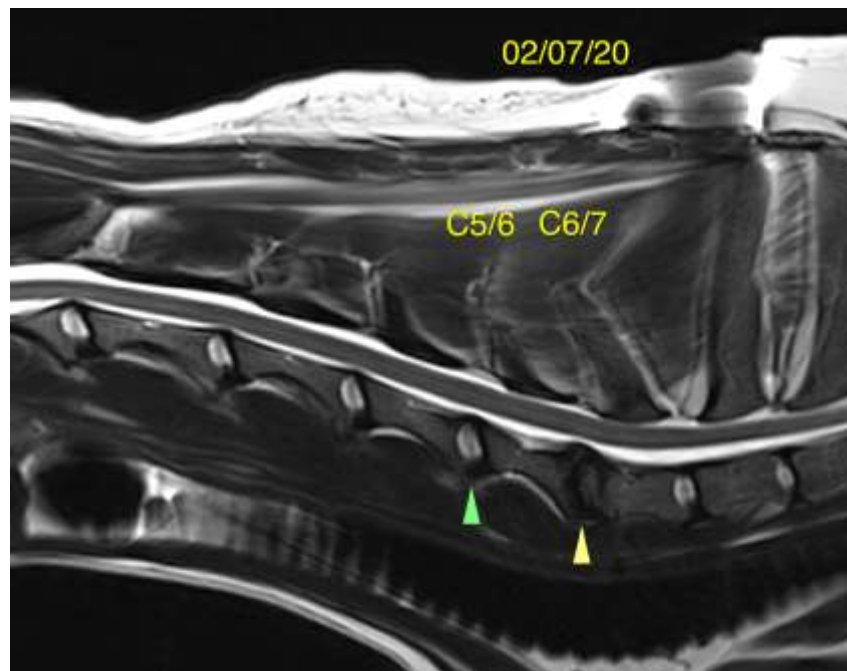
Dr. Marchal

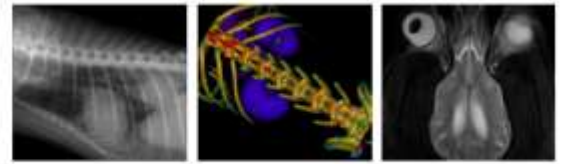
INVOICE

49593

DATE

1-15-22





PATIENT

Lila McDonald

SPECIES

Canine

BREED

GSD

SEX

FS

AGE

8

INTERPRETED BY

Nele Eley, DVM
Dr. med. Vet. DipECVDI

HOSPITAL NAME

Animal Health
Partners

REFERRING VET

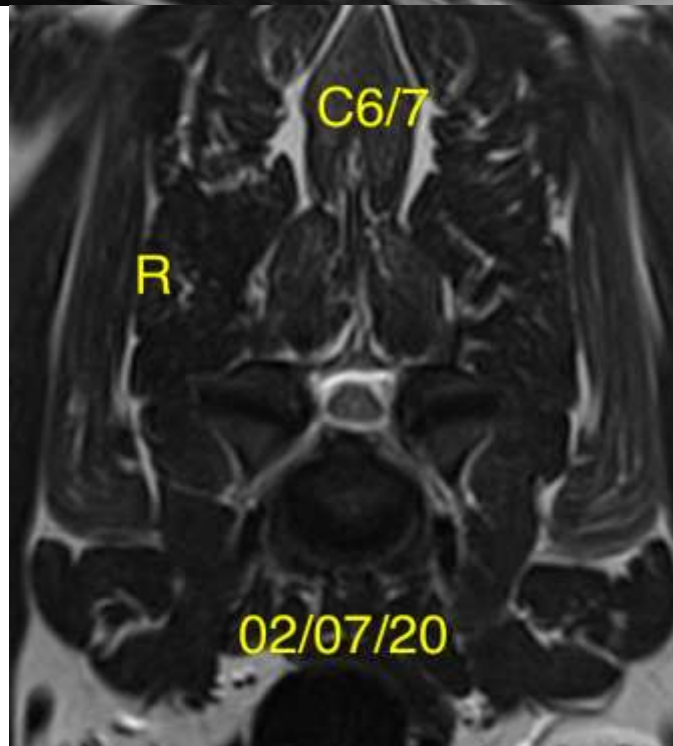
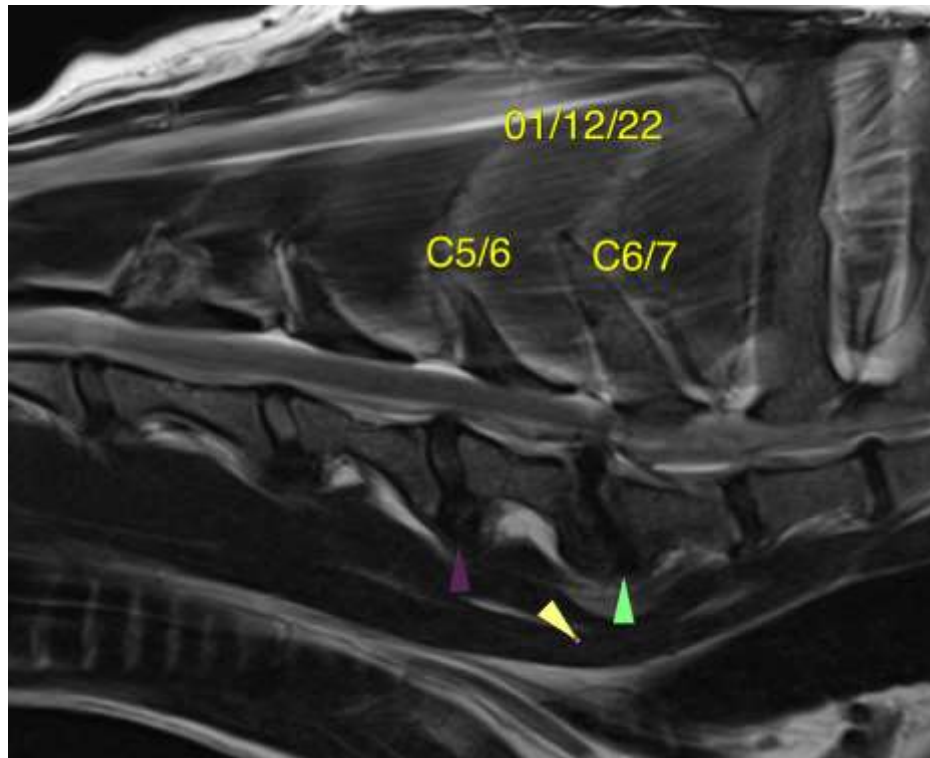
Dr. Marchal

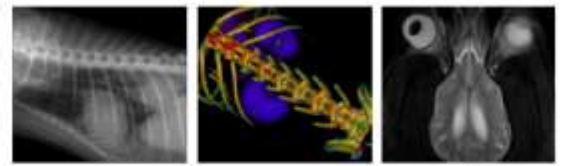
INVOICE

49593

DATE

1-15-22





PATIENT

Lila McDonald

SPECIES

Canine

BREED

GSD

SEX

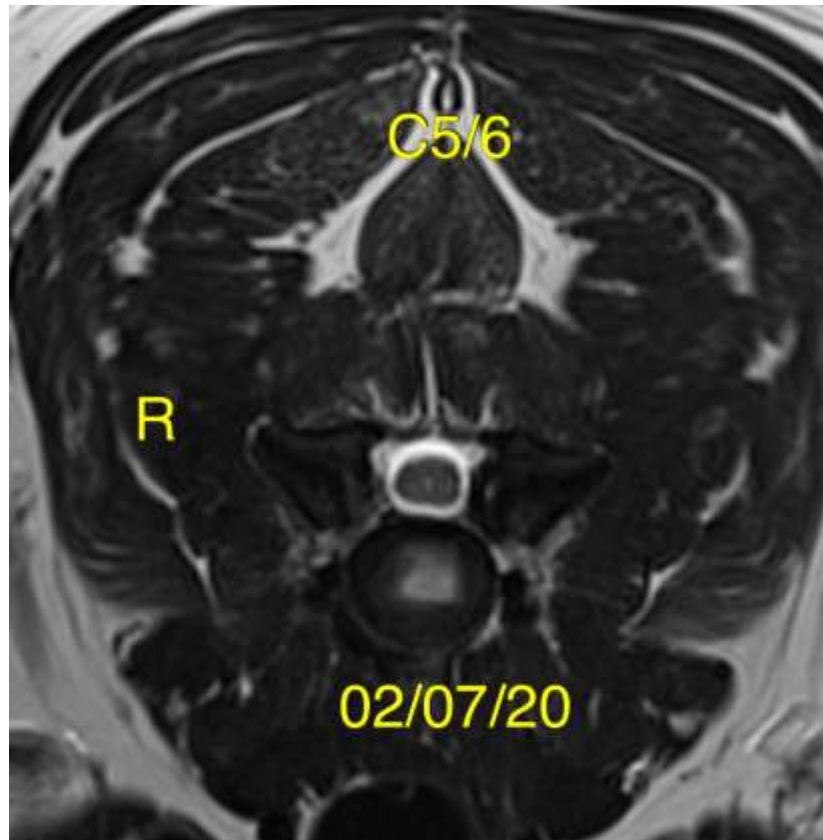
FS

AGE

8

INTERPRETED BY

Nele Eley, DVM
Dr. med. Vet. DipECVDI



HOSPITAL NAME

Animal Health
Partners

The information and recommendations provided are based on the images presented by the referring veterinarian. No evaluation can be communicated regarding pathology that was not visible in the image/video clips provided.

REFERRING VET

Dr. Marchal

Thank you for this referral. If the clinical or image interpretation does not parallel your findings or if I can be of any further assistance please contact me.

Nele Eley, DVM, Dr. med. vet., DipECVDI
European Specialist in Veterinary Diagnostic Imaging, Cert. Radiology,
Senior lecturer University of Giessen, Germany, Veterinary Faculty, Department of Radiology
Nele.Eley@sonopath.com

INVOICE

49593

DATE

1-15-22