



PATIENT PRESENTING CLINICAL SIGNS

PATIENT DingDing Li
SPECIES Canine
BREED Min. Schnauzer
SEX M
AGE 7

Admitted to ER CURRENT MEDICAL CONCERN Approximately 2 months ago started having clinical signs Assessed by RDVM first week of December Weak in the PL worse on the right with delayed pp in the right PL Radiographs taken during that visit showed narrowed disk space between L2-L3 Blood work done was unremarkable He was treated as an outpatient with gabapentin. Dec 9 Assessed by AHP Neuro service - Ambulatory with mild-moderate proprioceptive ataxia of the pelvic limb and mild spastic paraparesis, lateralizing to the right. Mild erratic paw placement and decreased flexors during steps noted in pelvic limbs during ambulation. Proprioceptive positioning and hopping were mildly delayed in right pelvic limb and normal in other limbs. No hyperesthesia elicited with palpation along the vertebral column. Recommended MRI of TL +/- Surgery - owner elected outpatient care Owner have tried accupuncture but did not see a big improvement Owners feel that he has progressed and is not using the back right Eating and drinking normally Normal urination and defecation Neurological examination: Mentation: Bright, alert and responsive. Cranial nerve exam: No deficits noted. Gait/posture: Ambulatory with moderate to severe proprioceptive ataxia on both pelvic limbs and spastic paraparesis, lateralizing to the right. Spontaneous knuckling is seen more on the right. Postural reactions: Proprioceptive positioning and hopping were moderately to severely delayed in both pelvic limbs, worse on the right Spinal reflexes: Normal patellar and withdrawal reflexes. Sensory/nociception: Screamed/yelped upon caudal thoracic palpation.

MAGNETIC RESONANCE IMAGING STUDY OF THE THORACOLUMBAR SPINE

Plain and post contrast sequences available for review in T2, T2-fat saturated, plain T1 and contrast enhanced as well as fat saturated contrast enhanced T1 weighted images in various image planes.

INTERPRETED BY

Nele Eley, DVM
 Dr. med. Vet. DipECVDI

The prostate is not fully included in the image set.

MAGNETIC RESONANCE IMAGING FINDINGS

HOSPITAL NAME

Animal Health
 Partners

Severe and well delineated extrusion of intervertebral disc material is seen within the cranial lumbar spine at L2/3. Right sided rupture of the annulus fibrosis of the intervertebral disc is seen. The extruded material is isointense in T2- and T1-weighted images and presents cranial migration. The material is situated in the right ventral epidural space of the vertebral canal level with the caudal half of the 2nd lumbar vertebra and occupies approximately 75% of the vertebral canal's cross sectional area. Severe leftward deviation and compression of the spinal cord is seen. The early contrast enhanced sequences reveal mild peripheral rim enhancement. Moderate heterogeneous enhancement is noted on the later post-contrast studies within the extruded disc material. A hyperintense rim is seen circumferential to the rounded extrusion on T2-weighted images.

REFERRING VET

Dr. Marchal

INVOICE

49602

A second site of extrusion is present within the caudal thoracic spine between T12 and T13. The extrusion presents similar signal behavior as the first extrusion. Mild contrast enhancement is noted here as well. The extrusion presents cranial migration over the length of the 12th thoracic vertebra and occupies approximately 50% of the vertebral canal's cross sectional area. The extrusion is mostly situated to the right of the midline and moderate leftward deviation and compression of the spinal cord are seen.

DATE

1-15-22

The intervertebral disc spaces T12/13 and L2/3 are reduced in width.



PATIENT

DingDing Li

Multifocal degenerative disc disease is seen throughout the thoracolumbar spine accentuating the caudal thoracic and cranial lumbar spine.

Mild intervertebral disc protrusions are present between L1/2 and L4/5 as well as T11/12.

SPECIES

Canine

Multiple T2 hypointense nodules are seen in the spleen accentuating the hilus.

A 12mm sized cyst is seen in the caudal half of the right kidney.

The urinary bladder is severely distended.

BREED

Min. Schnauzer

The prostate appears to be enlarged.

The regional lymph nodes present within normal limits.

SEX

M

- Chronic severely compressive intervertebral disc extrusion L2/3.
- Chronic moderate compressive intervertebral disc extrusion T12/13.
- Mild multifocal intervertebral disc protrusion within the thoracolumbar spine.
- Multifocal degenerative disc disease.
- Hypointense splenic nodules compatible with benign nodular hyperplasia and/or myelolipomas.
- Renal cyst of the right kidney.
- Presumed prostatomegaly with intraprostatic cyst.

AGE

7

INTERPRETED BY

Nele Eley, DVM
Dr. med. Vet. DipECVDI

INTERPRETATION OF THE FINDINGS & FURTHER RECOMMENDATIONS

The MRI findings are compatible with two sites of chronic and organized intervertebral disc extrusions. The extrusion within the cranial lumbar spine at L2/3 causes severe spinal cord compression. Moderate compressive myelopathy is present at T12/13. In both cases, the extrusion is mostly situated towards the right of the midline which appears to parallel the laterality of the neurologic deficits well. Owing to the long standing history and chronicity of the spinal cord compression, the patient may no longer benefit from surgical decompression at this time.

HOSPITAL NAME

Animal Health
Partners

REFERRING VET

Dr. Marchal

INVOICE

49602

DATE

1-15-22



PATIENT

DingDing Li

SPECIES

Canine

BREED

Min. Schnauzer

SEX

M

AGE

7

INTERPRETED BY

Nele Eley, DVM
Dr. med. Vet. DipECVDI

HOSPITAL NAME

Animal Health
Partners

REFERRING VET

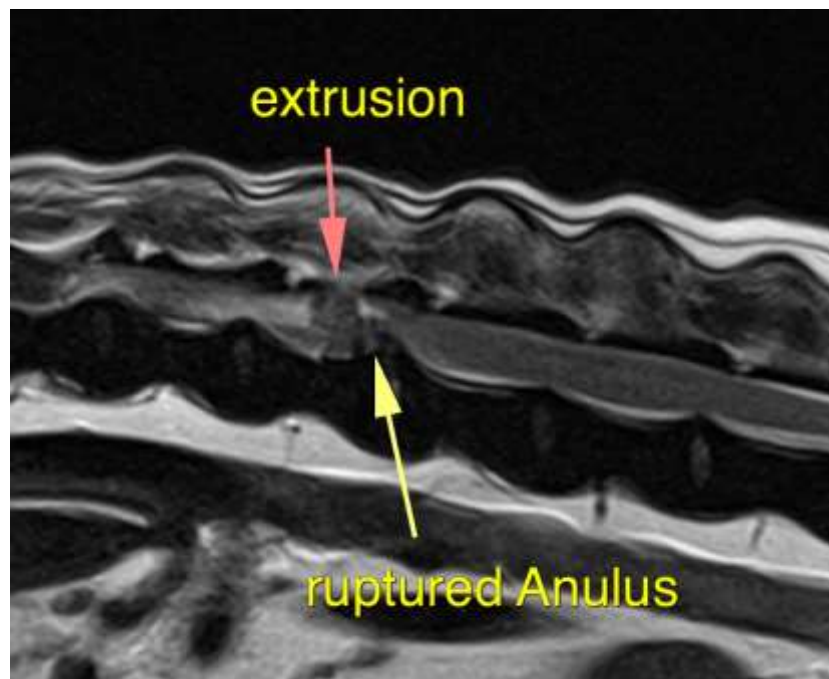
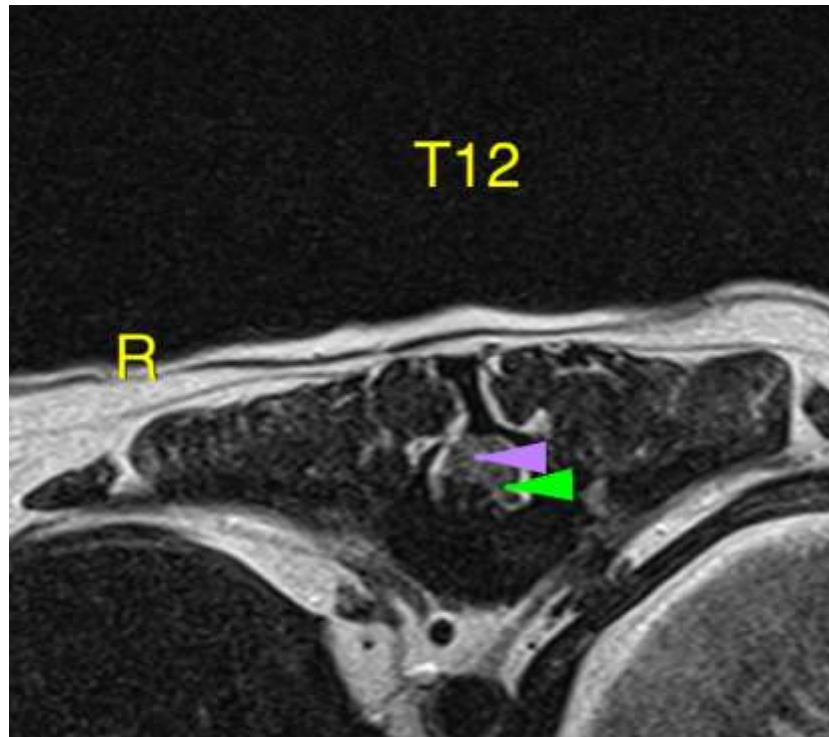
Dr. Marchal

INVOICE

49602

DATE

1-15-22





PATIENT

DingDing Li

SPECIES

Canine

BREED

Min. Schnauzer

SEX

M

AGE

7

INTERPRETED BY

Nele Eley, DVM
Dr. med. Vet. DipECVDI

HOSPITAL NAME

Animal Health
Partners

REFERRING VET

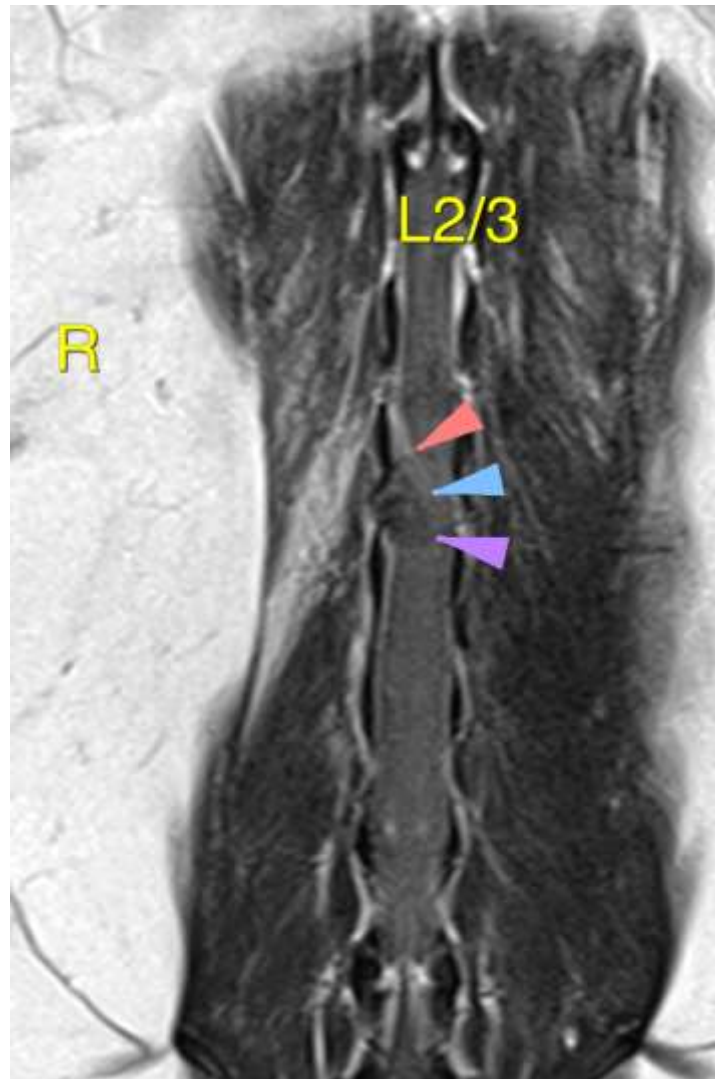
Dr. Marchal

INVOICE

49602

DATE

1-15-22



The information and recommendations provided are based on the images presented by the referring veterinarian. No evaluation can be communicated regarding pathology that was not visible in the image/video clips provided.

Thank you for this referral. If the clinical or image interpretation does not parallel your findings or if I can be of any further assistance please contact me.

Nele Eley, DVM, Dr. med. vet., DipECVDI
European Specialist in Veterinary Diagnostic Imaging, Cert. Radiology,
Senior lecturer University of Giessen, Germany, Veterinary Faculty, Department of Radiology
Nele.Eley@sonopath.com