



PATIENT

Tomas Dilts

SPECIES

Canine

BREED

Greyhound Mix

SEX

Neutered Male

AGE

12Y

WEIGHT

23lbs

INTERPRETED BY

Nele Eley (Ondreka),
DVM Dr. med. vet.,
DipECVDI

IMAGING PERFORMED BY

Sidney

HOSPITAL NAME

East Hill Animal
Hospital

REFERRING VET

Laura Hall

INVOICE

73321

DATE

1-14-26

PRESENTING CLINICAL SIGNS

Swelling right eye. Painful when opens mouth and periorbital palpation.

COMPUTED TOMOGRAPHIC STUDY OF THE HEAD

Plain and post contrast studies are available for review.

COMPUTED TOMOGRAPHIC FINDINGS

A 3.5 x 4.0 cm sized soft tissue attenuating mass with internal cavitation and strong heterogeneous contrast enhancement is seen in the right retrobulbar space. The lesion is ill-defined. Aggressive osteolysis of the adjacent bones involving the coronoid process of the right mandible and right temporal bone is seen. There is evidence of early intracranial extension through the right temporal bone with meningeal enhancement and thickening. Moderate exophthalmos of the right globe is noted.

There is an aggressive osteolytic lesion affecting the left maxilla and left zygomatic arch starting distal of tooth 206 and extending through more than half of the zygomatic arch. Associated cortical disruption, permeative lysis, and long indistinct transition zone to the unaffected bone are noted. Loosening of the left maxillary molar teeth is present.

Mild bilateral submandibular lymphadenomegaly is seen.

COMPUTED TOMOGRAPHIC DIAGNOSIS

- Right retrobulbar aggressive soft tissue mass with cavitation, bone lysis, and early intracranial extension causing exophthalmos.
- Left maxillofacial aggressive osteolytic lesion likely separate or multifocal disease.
- Mild bilateral submandibular lymphadenomegaly.

INTERPRETATION OF FINDINGS & FURTHER RECOMMENDATIONS

The CT study reveals two lesions with aggressive biological behavior: a right retrobulbar aggressive soft tissue mass with early intracranial extension and a left maxillofacial aggressive osteolytic lesion. Differential diagnosis includes primary malignant neoplasia including osteosarcoma, fibrosarcoma, undifferentiated sarcoma, melanoma, and round cell neoplasia. The findings are not supporting benign disease. Multifocal primary lesions vs metastatic spread to contralateral maxilla could be considered.

The lymph node enlargement is mild and may be reactive or early metastatic.

Biopsy of both lesions can be considered to confirm diagnosis. Cytology of the submandibular lymph nodes could be considered as well. Pain management, oncology consultation, and full staging could be considered, however, the treatment options are likely limited to palliative, and the long-term prognosis is unfortunately poor.



PATIENT

Tomas Dilts

SPECIES

Canine

BREED

Greyhound Mix

SEX

Neutered Male

AGE

12Y

WEIGHT

23lbs

INTERPRETED BY

Nele Eley (Ondreka),
DVM Dr. med. vet.,
DipECVDI

IMAGING PERFORMED BY

Sidney

HOSPITAL NAME

East Hill Animal
Hospital

REFERRING VET

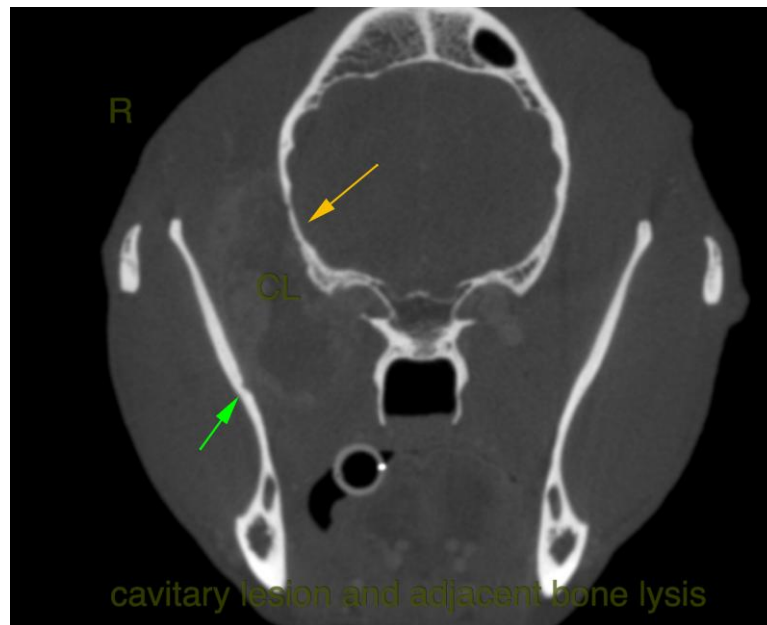
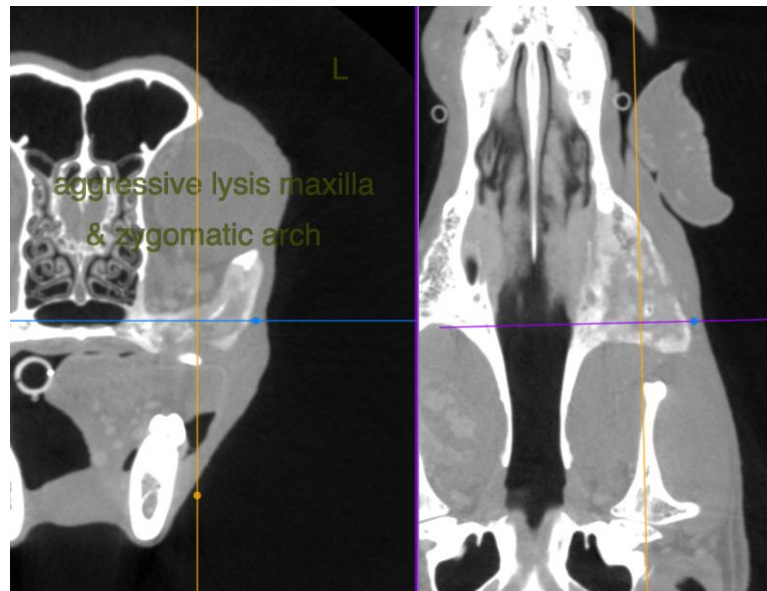
Laura Hall

INVOICE

73321

DATE

1-14-26





PATIENT

Tomas Dilts

SPECIES

Canine

BREED

Greyhound Mix

SEX

Neutered Male

AGE

12Y

WEIGHT

23lbs

INTERPRETED BY

Nele Eley (Ondreka),
DVM Dr. med. vet.,
DipECVDI

IMAGING PERFORMED BY

Sidney

HOSPITAL NAME

East Hill Animal
Hospital

REFERRING VET

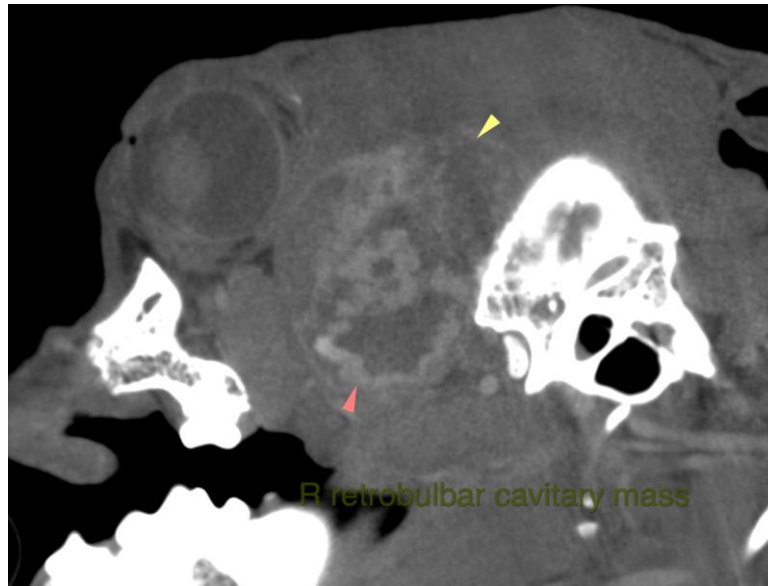Laura Hall

INVOICE

73321

DATE

1-14-26



The information and recommendations provided are based on the images presented by the referring veterinarian. No evaluation can be communicated regarding pathology that was not visible in the image/video clips provided.

Thank you for this referral. If the clinical or image interpretation does not parallel your findings or if I can be of any further assistance please contact me.

Nele Eley (Ondreka), DVM, Dr. med. vet., DipECVDI
European Specialist in Veterinary Diagnostic Imaging, Cert. Radiology,
Senior lecturer University of Giessen/Germany, Veterinary Faculty, Department of Radiology.
info@sonopath.com