



PATIENT

Sandy Pinker

SPECIES

Canine

BREED

Cockapoo

SEX

Female Spayed

AGE

12

WEIGHT

24

INTERPRETED BY

Nele Eley (Ondreka),
DVM Dr. med. vet.,
DipECVDI

IMAGING PERFORMED BY

Doug

HOSPITAL NAME

East Aurora Veterinary
Hospital

REFERRING VET

Sara Huckabone

INVOICE

73319

DATE

1-13-26

PRESENTING CLINICAL SIGNS

History of ccl tear left stifle, managed medically currently (no surgery)

RADIOGRAPHIC STUDY OF THE STIFLES

Mediolateral and craniocaudal views of both stifle joints totaling 4 images available for review.

RADIOGRAPHIC FINDINGS

The left stifle joint presents moderate articular enlargement representing effusion and/or synovial thickening. No cranial tibial thrust is appreciated radiographically. Mild periarticular osteophytes are seen most prominent along the femoral trochlea, and the popliteal sesamoid bone is slightly enlarged due to smooth new bone formation. The patella is in normal position.

Mild atrophy of the left hind limb musculature consistent with chronic disuse is seen.

The right stifle presents within normal radiographic limits with no effusion or structural abnormalities identified. There are no significant periarticular bone changes.

RADIOGRAPHIC DIAGNOSIS

- Moderate joint effusion/synovitis and early osteoarthritic changes of the left stifle joint.
- Mild disuse atrophy of the left hind limb musculature.
- Normal radiographic presentation of the right stifle joint.

INTERPRETATION OF FINDINGS & FURTHER RECOMMENDATIONS

The left stifle joint demonstrates changes compatible with a cruciate ligament tear even though the intraarticular soft tissues cannot be seen radiographically. Mild osteophytosis, effusion/synovial swelling, and mild atrophy of the surrounding musculature support the clinical diagnosis of left stifle arthropathy. The right stifle appears currently unaffected. Correlation with the clinical palpation is required. The osteoarthritic changes are very mild at present and continued medical management can be considered if patient remains functional and pain is controlled.



PATIENT

Sandy Pinker

SPECIES

Canine

BREED

Cockapoo

SEX

Female Spayed

AGE

12

WEIGHT

24

INTERPRETED BY

Nele Eley (Ondreka),
DVM Dr. med. vet.,
DipECVDI

IMAGING PERFORMED BY

Doug

HOSPITAL NAME

East Aurora Veterinary
Hospital

REFERRING VET

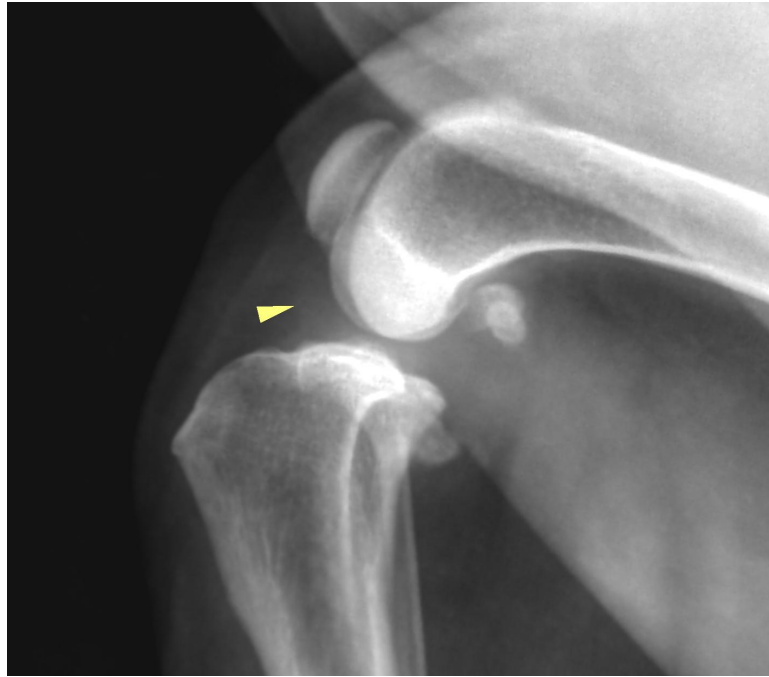
Sara Huckabone

INVOICE

73319

DATE

1-13-26



The information and recommendations provided are based on the images presented by the referring veterinarian. No evaluation can be communicated regarding pathology that was not visible in the image/video clips provided.

Thank you for this referral. If the clinical or image interpretation does not parallel your findings or if I can be of any further assistance please contact me.

Nele Eley (Ondreka), DVM, Dr. med. vet., DipECVDI
European Specialist in Veterinary Diagnostic Imaging, Cert. Radiology,
Senior lecturer University of Giessen/Germany, Veterinary Faculty, Department of Radiology.
info@sonopath.com