



## PATIENT

Donny Hiczewski

## SPECIES

Feline

## BREED

Domestic Shorthair

## SEX

Male Neutered

## AGE

9

## WEIGHT

15.3

## INTERPRETED BY

Nele Eley (Ondreka),  
DVM Dr. med. vet.,  
DipECVDF

## IMAGING PERFORMED BY

Doug, LVT

## HOSPITAL NAME

East Aurora Veterinary  
Hospital

## REFERRING VET

Sara Huckabone, DVM

## INVOICE

73320

## DATE

1-13-26

## PRESENTING CLINICAL SIGNS

Coughing got better after last visit and antibiotic but never fully went away. Cough has become worse in last week. Sounds congested. Coughs a bunch of times in a row. Does that about twice a day. Non productive cough. No eye or nasal discharge. Normal energy. Indoor only. 3 other cats in household.

## RADIOGRAPHIC STUDY OF THE THORAX

Right/left lateral and ventrodorsal views of the thorax totaling 4 images available for review.

## RADIOGRAPHIC FINDINGS

A moderate generalized bronchial lung pattern is seen throughout the right and left lung with extensive peribronchial cuffing consistent with chronic active airway inflammation. No evidence of pulmonary consolidation or alveolar pattern is seen. There is no air-trapping or hyperinflation identified.

The trachea appears normal in position and caliber.

The mediastinum and cardiovascular structures present within normal limits. VHS is 8.

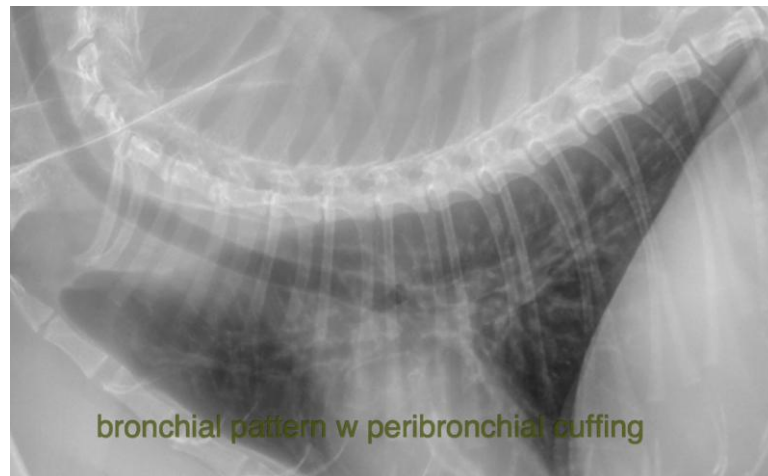
The pleural space presents normal with no evidence of effusion.

## RADIOGRAPHIC DIAGNOSIS

- Chronic active lower airway disease.
- No radiographic evidence of cardiac disease.

## INTERPRETATION OF FINDINGS & FURTHER RECOMMENDATIONS

The radiographic findings are consistent with chronic active lower airway inflammation commonly seen with feline asthma or infectious bronchitis. The radiographic findings correlate with the clinical signs of intermittent coughing. Continued medical management as clinically indicated and consider further diagnostics such as airway cytology via BAL or transtracheal wash if cough persists or worsens. Environmental management to reduce irritants is recommended as well.





## PATIENT

Donny Hiczewski

## SPECIES

Feline

## BREED

Domestic Shorthair

## SEX

Male Neutered

## AGE

9

## WEIGHT

15.3

## INTERPRETED BY

Nele Eley (Ondreka),  
DVM Dr. med. vet.,  
DipECVDI

## IMAGING PERFORMED BY

Doug, LVT

## HOSPITAL NAME

East Aurora Veterinary  
Hospital

## REFERRING VET

Sara Huckabone, DVM

## INVOICE

73320

## DATE

1-13-26

The information and recommendations provided are based on the images presented by the referring veterinarian. No evaluation can be communicated regarding pathology that was not visible in the image/video clips provided.

Thank you for this referral. If the clinical or image interpretation does not parallel your findings or if I can be of any further assistance please contact me.

**Nele Eley (Ondreka)**, DVM, Dr. med. vet., DipECVDI

European Specialist in Veterinary Diagnostic Imaging, Cert. Radiology,  
Senior lecturer University of Giessen/Germany, Veterinary Faculty, Department of Radiology.  
[info@sonopath.com](mailto:info@sonopath.com)