



PATIENT

Sam Moreira

PRESENTING CLINICAL SIGNS

not eating , vomiting for two days
Abnormal PE/Chem/CBC/UA Results: elevated CREA, hypokalemia

SPECIES

Feline

RADIOGRAPHIC STUDY OF THE ABDOMEN

Right/left lateral and ventrodorsal views totaling 3 images available for review.

BREED

Domestic Medium
Hair

RADIOGRAPHIC FINDINGS

The degree of pulmonary inflation is fair. A mild generalized increase in interstitial opacity of the lung is seen.

SEX

Male Neutered

Abdomen

Mild L6/7 spondylosis deformans is present.

The patient is obese.

The abdominal serosal detail appears to be mildly reduced caudal to the stomach.

AGE

14 Years

The liver is appropriate in position, size and presents uniform opacity.

The splenic head is in the anticipated position and within normal limits for size and opacity. The splenic tail is not seen.

INTERPRETED BY

Nele Eley, DVM
Dr. med. Vet. DipECVDI

Both kidneys are seen and present with normal size, shape, delineation and opacity. The urinary bladder is severely distended.

There is a mineralized bates body in the caudal abdomen level with the descending colon and urinary bladder.

HOSPITAL NAME

St. Catharine's Animal
Hospital

The stomach presents mild gastric aerophagia.

Mild small intestinal aerophagia and hypersegmentation are seen as well.

REFERRING VET

Dr. Boctor

The colon is seen in the expected position and presents with appropriate content.

INVOICE

49573

RADIOGRAPHIC DIAGNOSIS

- Suspect reduced serosal detail in the cranial abdomen.
- Gastrointestinal maldigestion pattern.
- Bates body - incidental finding.
- Interstitial lung pattern.

DATE

1-13-22

INTERPRETATION OF THE FINDINGS & FURTHER RECOMMENDATIONS

The radiographic findings suggest potential for reduced serosal detail in the cranial abdomen such as in pancreatopathy or other. A gastrointestinal maldigestion pattern supporting presence of a functional ileus is present as well. Consider further definition by means of abdominal



PATIENT

ultrasound and correlate with the available laboratory values.

Sam Moreira

The interstitial lung pattern may be enhanced by the abundance of subcutaneous mediastinal fat deposits; however, interstitial lung disease such as interstitial pneumonia, interstitial edema, fibrosis, or other cannot be ruled out entirely.

SPECIES

Feline

BREED

Domestic Medium
Hair

SEX

Male Neutered

AGE

14 Years

INTERPRETED BY

Nele Eley, DVM
Dr. med. Vet. DipECVDI

HOSPITAL NAME

St. Catharine's Animal
Hospital

REFERRING VET

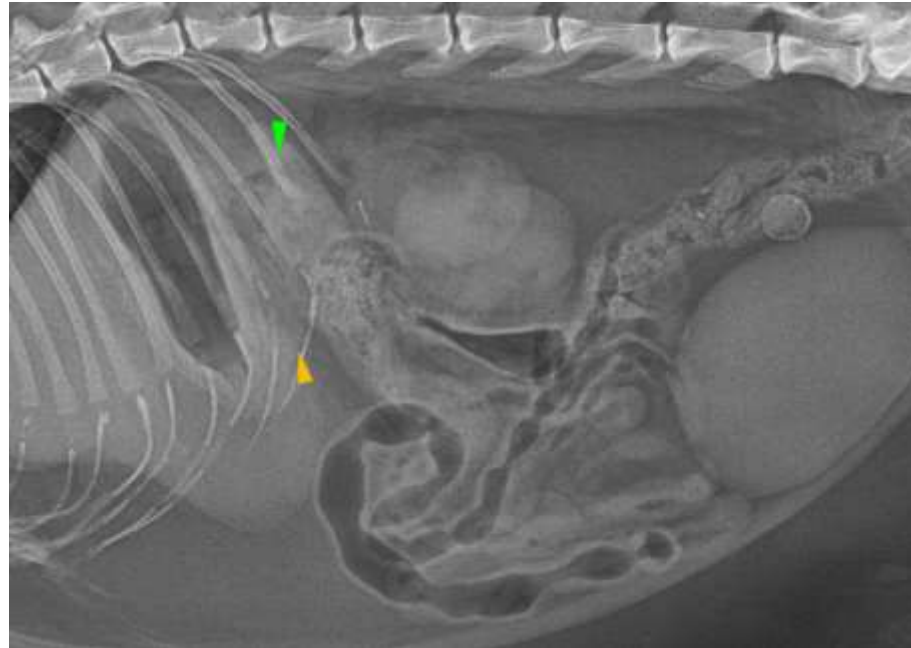
Dr. Boctor

INVOICE

49573

DATE

1-13-22



The information and recommendations provided are based on the images presented by the referring veterinarian. No evaluation can be communicated regarding pathology that was not visible in the image/video clips provided.

Thank you for this referral. If the clinical or image interpretation does not parallel your findings or if I can be of any further assistance please contact me.

Nele Eley, DVM, Dr. med. vet., DipECVDI
European Specialist in Veterinary Diagnostic Imaging, Cert. Radiology,
Senior lecturer University of Giessen, Germany, Veterinary Faculty, Department of Radiology
Nele.Eley@sonopath.com