



PATIENT

Jasper Campbell

PRESENTING CLINICAL SIGNS

Chronic vomiting

SPECIES

Canine

RADIOGRAPHIC STUDY OF THE THORAX & ABDOMEN

Right/left lateral and ventrodorsal views of the thorax and abdomen each totaling 6 images available for review.

BREED

German Shepherd

RADIOGRAPHIC FINDINGS

A subchondral bone defect is seen in at least one of the humeral heads compatible with osteochondritis.

Thorax

SEX

MN

The cardiac silhouette presents no evidence of generalized enlargement or specific chamber enlargement. No evidence of abnormal mediastinal widening is seen.

Mild redundancy of the dorsal tracheal ligament is seen in the cervical trachea.

AGE

7 Years, 1 Month

The degree of pulmonary inflation is moderate. The presentation of the lung is considered within age related normal limits.

The diaphragmatic contour is intact.

INTERPRETED BY

Nele Eley, DVM
Dr. med. Vet. DipECVDI

Abdomen

The stomach is consistently dilated with a moderate amount of gas. No evidence of malpositioning or torsion is seen. The gastric outlet and descending duodenum are highlighted by gas on the left lateral views. Acute dorsal angulation of the descending duodenum is seen and is mildly dilated. The remainder of the small intestinal loops are of even diameter, nondilated, and no evidence of plication is seen. A short thin linear mineral opacity appears to be present in one of the small intestinal loops on the left lateral view of the abdomen.

The colon contains a mild amount of fecal matter. Mild caudal descending colon spasticity is seen.

HOSPITAL NAME

Blairstown Animal Hospital

REFERRING VET

Dr. Zeliff

The kidneys, urinary bladder, and spleen present within normal limits. The spleen may be volume contracted for a German Shepherd dog since the typical hypersplenism is not seen.

RADIOGRAPHIC DIAGNOSIS

INVOICE

49575

- Normal age related thorax.
- Gastrointestinal maldigestion pattern with mild dilation of the descending duodenum.
- Shoulder osteoarthritis - unrelated to the reason of clinical presentation.

DATE

1-13-22

INTERPRETATION OF THE FINDINGS & FURTHER RECOMMENDATIONS

A gastrointestinal maldigestion pattern with mild gastroduodenal dilation is seen. There is no definitive mechanical ileus and functional ileus appears more likely based on the radiographic findings than mechanical obstruction. However, mechanical ileus or subileus high in the



PATIENT

Jasper Campbell

gastrointestinal tract cannot be ruled out entirely as per the gastroduodenal dilation. If not performed already, full abdominal ultrasound and endoscopy are potential considerations in the further workup of this patient's clinical signs.

SPECIES

Canine

BREED

German Shepherd

SEX

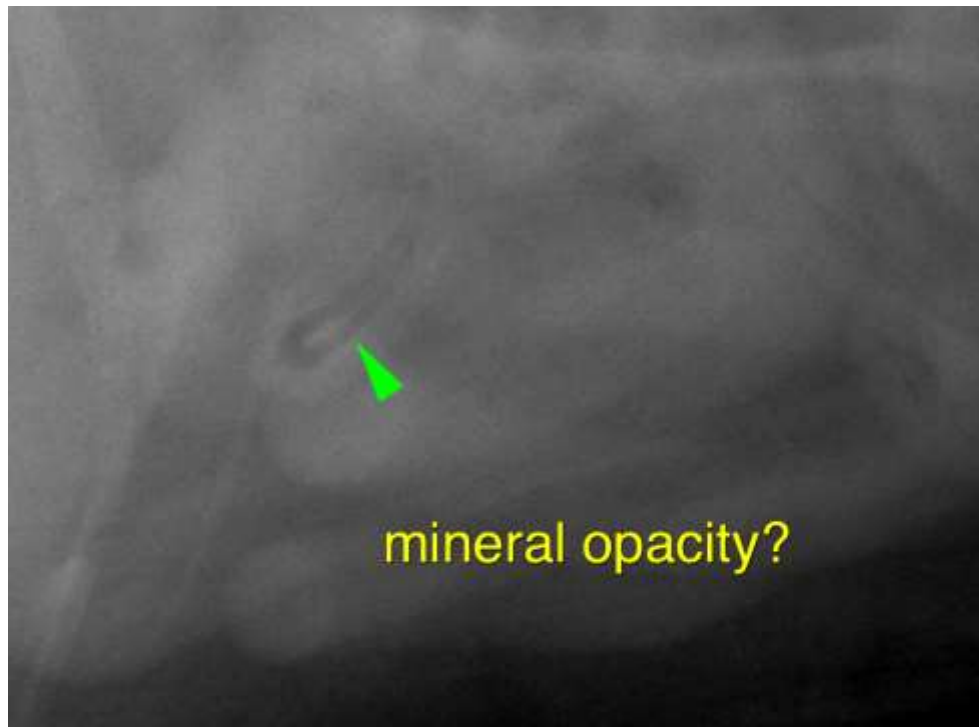
MN

AGE

7 Years, 1 Month

INTERPRETED BY

Nele Eley, DVM
Dr. med. Vet. DipECVDI



HOSPITAL NAME

Blairstown Animal
Hospital

The information and recommendations provided are based on the images presented by the referring veterinarian. No evaluation can be communicated regarding pathology that was not visible in the image/video clips provided.

REFERRING VET

Dr. Zeliff

Thank you for this referral. If the clinical or image interpretation does not parallel your findings or if I can be of any further assistance please contact me.

Nele Eley, DVM, Dr. med. vet., DipECVDI
European Specialist in Veterinary Diagnostic Imaging, Cert. Radiology,
Senior lecturer University of Giessen, Germany, Veterinary Faculty, Department of Radiology
Nele.Eley@sonopath.com

INVOICE

49575

DATE

1-13-22