



PATIENT PRESENTING CLINICAL SIGNS

Bama Mintz Shoulder US to eval for BB tenosynovitis RTL Hx SUP remodeling Jan 2022, hx mild elbow OA, mild mineral biceps groove RTL Chronic RTL lameness
Abnormal PE/Chem/CBC/UA Results: Painful palpation supraspinatus bilaterally Limited flexibility in extension glenohumeral joint R >L due to triceps and stiff infraspinatus RTL + sore INF to palpation) Moderate limited flexibility biceps at end range of stretch largely due to restriction at insertion on radius and ulna

SPECIES

Canine

ULTRASONOGRAPHIC FINDINGS

BREED

Boxer Mix

Right Shoulder

Mild diffuse increase in echogenicity and volume loss of the right infraspinatus muscle are seen. Similar changes appear to affect the teres minor muscle. The echogenicity increase extends up to the level to the musculotendinous junction where the muscular and tendinous background almost blend into each other. Mild periarticular osteophytes are seen. There is mild internal echoarchitectural remodeling of the supraspinatus tendon which measures 8mm in average maximum thickness. No overt biceps impingement or adhesion formation is seen. The biceps tendon presents no echoarchitectural changes. Minimal exostosis is seen within the intertubercular groove and there is minimal swelling of the bicipital synovium.

SEX

FS

AGE

12 Years

Left Shoulder

Mild diffuse volume loss of the left infraspinatus tendon is seen. No echoarchitectural changes of the infraspinatus muscle tissue are appreciated. The left supraspinatus tendon measures 8mm in average maximum thickness and presents mild internal echoarchitectural remodeling. No biceps impingement or adhesion formation is seen. The biceps tendon presents no echoarchitectural changes. The intertubercular groove's bone surface is even and smooth. Mild periarticular bone remodeling is seen. The bicipital synovium presents within normal limits.

INTERPRETED BY

Nele Eley, DVM
 Dr. med. Vet. DipECVDI

ULTRASONOGRAPHIC DIAGNOSIS

- Bilateral infraspinatus myopathy with right teres minor myopathy.
- Mild bilateral supraspinatus tendinopathy with no evidence of biceps impingement.
- Minimal right biceps tenosynovitis.
- Suspect bilateral early degenerative joint disease of the shoulders.

HOSPITAL NAME

Animal Care Center of
 Castle Pines

INTERPRETATION OF THE FINDINGS & FURTHER RECOMMENDATIONS

REFERRING VET

Bartling

The ultrasonographic findings suggest presence of bilateral infraspinatus myopathy. Differential diagnosis includes atrophy of the muscles with fatty replacement versus early stage of fibrosing myopathy. Clinical correlation is required. The changes are more advanced on the right when compared with the left side.

INVOICE

56158

Mild signs of degenerative joint disease are seen within both shoulders.

DATE

1-12-23

There is evidence of bilateral supraspinatus tendinopathy. Clinical significance of which is uncertain. Mild signs of biceps tenosynovitis are noted in the right shoulder concurrently.



PATIENT

Bama Mintz

SPECIES

Canine

BREED

Boxer Mix

SEX

FS

AGE

12 Years

INTERPRETED BY

Nele Eley, DVM
Dr. med. Vet. DipECVDI

HOSPITAL NAME

Animal Care Center of
Castle Pines

REFERRING VET

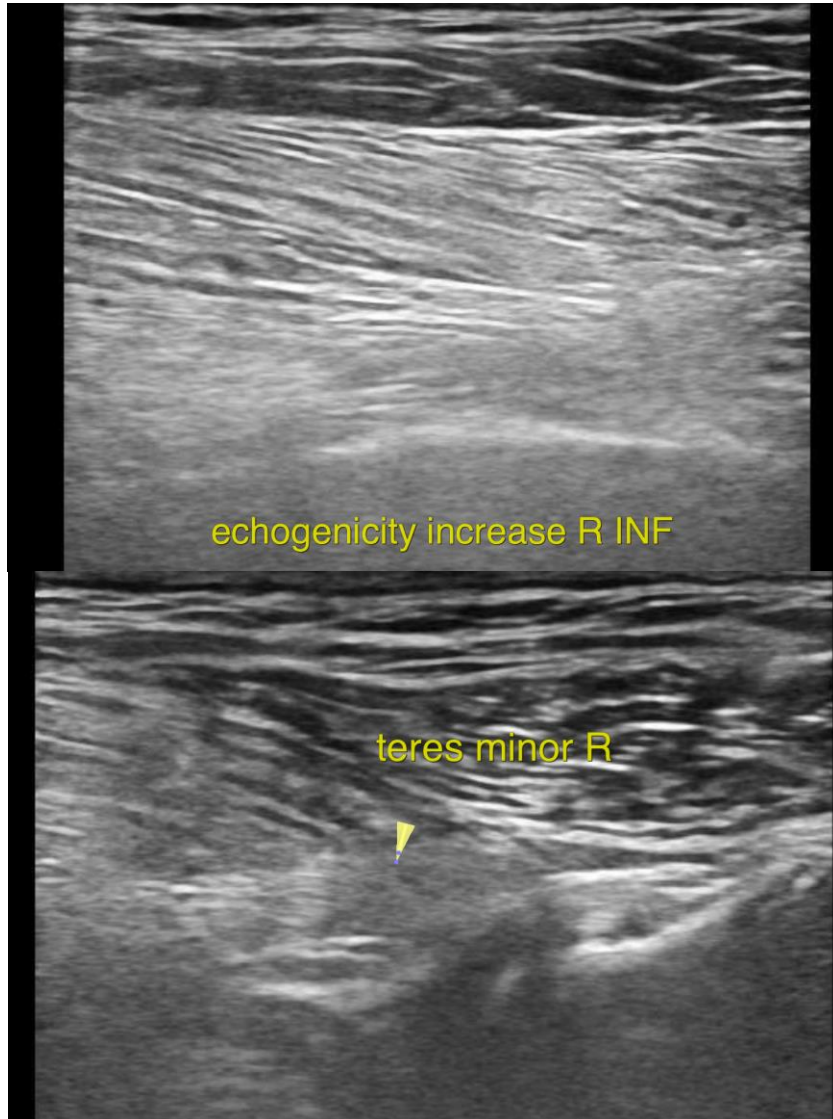
Bartling

INVOICE

56158

DATE

1-12-23





PATIENT

Bama Mintz

SPECIES

Canine

BREED

Boxer Mix

SEX

FS

AGE

12 Years

INTERPRETED BY

Nele Eley, DVM
Dr. med. Vet. DipECVDI

HOSPITAL NAME

Animal Care Center of
Castle Pines

REFERRING VET

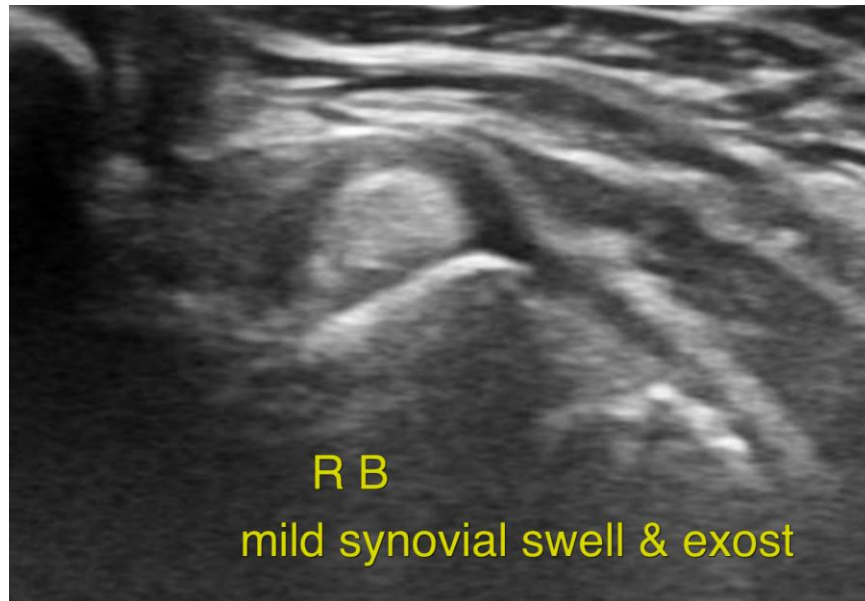Bartling

INVOICE

56158

DATE

1-12-23



The information and recommendations provided are based on the images presented by the referring veterinarian/sonographer. No evaluation can be communicated regarding pathology that was not visible in the image/video clips provided.

Thank you for this referral. If the clinical or image interpretation does not parallel your findings or if I can be of any further assistance please contact me.

Nele Eley, DVM, Dr. med. vet., DipECVDI
European Specialist in Veterinary Diagnostic Imaging, Cert. Radiology,
Senior lecturer University of Giessen, Germany, Veterinary Faculty, Department of Radiology
Nele.Eley@sonopath.com