

**PATIENT**

Johnni Mckerrow

**PRESENTING CLINICAL SIGNS**

History coughing excessively since 3 weeks. He is on vetmedin 1.25 twice daily. Attached to you the previous echocardiograph report on Last April

**SPECIES**

Canine

**RADIOGRAPHIC STUDY OF THE THORAX**

Right/left lateral and dorsoventral views totaling 5 images available for review.

**BREED**

Toy Poodle

**RADIOGRAPHIC FINDINGS**

Course and width of the trachea are considered within normal limits.

The left mainstem bronchus is significantly elevated by the severely enlarged left atrium. Pulmonary veins and left atrium present enlarged. The vertebral heart score is 13. The trachea is elevated. Loss of the caudal cardiac waist is seen. Broadened sternal contact of the right ventricle is noted as well.

**SEX**

Male Neutered

The degree of pulmonary inflation is moderate. A mild generalized bronchointerstitial lung pattern is seen and considered within age related normal limits. No evidence of pulmonary vascular dilation and no evidence of cardiogenic pulmonary edema is noted.

**AGE**

9 Years

The width of the caudal vena cava is within normal limits.

There is no evidence of hepatomegaly or ascites.

**INTERPRETED BY**

Nele Eley, DVM  
Dr. med. Vet. DipECVDI

**RADIOGRAPHIC DIAGNOSIS**

- Severe left sided cardiomegaly without evidence of cardiogenic pulmonary edema.
- Severe left atrial enlargement with mass effect on the left mainstem bronchus.
- Suspect concurrent right sided cardiomegaly.

**HOSPITAL NAME**

Truscott Animal  
Hospital

**INTERPRETATION OF THE FINDINGS & FURTHER RECOMMENDATIONS**

The radiographic findings are compatible with severe left sided cardiomegaly with severe left atrial enlargement. The mass effect on the left mainstem bronchus may contribute to the clinical signs. No evidence of cardiogenic pulmonary edema is seen at this point. The radiographs also indicate presence of right sided cardiomegaly as per the broadened sternal contact. Right sided congestive heart failure is not present radiographically at this point as well.

**REFERRING VET**

Medhat Meawad

**INVOICE**

49541

**DATE**

1-12-22



**PATIENT**

Johnni Mckerrow

**SPECIES**

Canine

**BREED**

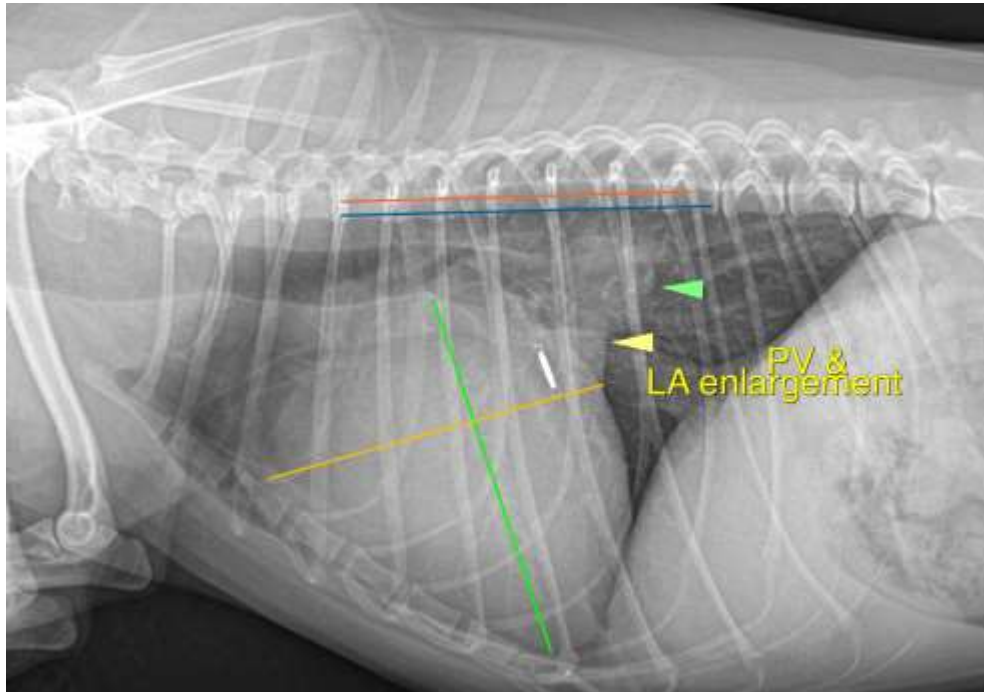
Toy Poodle

**SEX**

Male Neutered

**AGE**

9 Years



**INTERPRETED BY**

Nele Eley, DVM  
Dr. med. Vet. DipECVDI

The information and recommendations provided are based on the images presented by the referring veterinarian. No evaluation can be communicated regarding pathology that was not visible in the image/video clips provided.

Thank you for this referral. If the clinical or image interpretation does not parallel your findings or if I can be of any further assistance please contact me.

**HOSPITAL NAME**

Truscott Animal  
Hospital

**Nele Eley**, DVM, Dr. med. vet., DipECVDI  
European Specialist in Veterinary Diagnostic Imaging, Cert. Radiology,  
Senior lecturer University of Giessen, Germany, Veterinary Faculty, Department of Radiology  
Nele.Eley@sonopath.com

**REFERRING VET**

Medhat Meawad

**INVOICE**

49541

**DATE**

1-12-22