



PATIENT

Bohdi Osceola

PRESENTING CLINICAL SIGNS

Presented to ER last night after being Hit by car. Facial trauma noted and abrasion affecting the front limbs. Seizure episode earlier today
Abnormal PE/Chem/CBC/UA Results: sedated by rDVM prior to CT due to previous seizure activity today

SPECIES

Canine

COMPUTED TOMOGRAPHIC STUDY OF THE HEAD, NECK, & THORAX

Plain and post contrast studies of the head and neck and post contrast study only of the thorax available for review.

BREED

Pitbull

COMPUTED TOMOGRAPHIC FINDINGS

Head/Neck

SEX

Intact Male

The CT study of the head reveals multiple facial bone injury involving the left and right frontal bones, left nasal bone, left bony orbita, and the cribriform plate. Comminuted fractures with ventral displacement and impression are seen allowing for impingement onto the frontal lobes of the brain by a dorsal fragment of the cribriform plate.

AGE

1 Year, 2 Months

The rostradorsal aspect of the orbita is fractured in multiple fragments which blends into a nasal bone fracture and causes deviation and impingement of the left eye.

INTERPRETED BY

Nele Eley, DVM
Dr. med. Vet. DipECVDI

A moderate amount of fluid attenuating material is present within both nasal cavities. The multiple interruptions of the osseous lining of the nasal cavities and frontal sinuses allow for extensive subcutaneous emphysema along the dorsum of the fascial- and neuro-cranium.

No evidence of structural changes of the larynx or trachea are seen.

HOSPITAL NAME

Mobile Pet Imaging

Thorax

Mild bilateral pneumothorax is seen in the ventral aspect of both pleural cavities. No overt pulmonary injury is noted.

The ribcage appears to be intact.

REFERRING VET

Meaux

There is no evidence of osseous injury of the thoracic spine.

The dorsal tip of the 7th cervical dorsal spinous process is isolated.

INVOICE

49528

COMPUTED TOMOGRAPHIC DIAGNOSIS

- Multiple comminuted impression fractures of the facial bones and cribriform plate with nasal and frontal sinus hemorrhage as well as subcutaneous emphysema.
- Impingement of the left eye secondary to left orbital fracture.
- Mild bilateral pneumothorax - presumably due to blunt thoracic trauma or Valsalva maneuver.
- No evidence of relevant spinal injury in the cervical and thoracic spine.

DATE

1-12-22



PATIENT

Bohdi Osceola

SPECIES

Canine

BREED

Pitbull

SEX

Intact Male

AGE

1 Year, 2 Months

INTERPRETED BY

Nele Eley, DVM
Dr. med. Vet. DipECVDI

HOSPITAL NAME

Mobile Pet Imaging

REFERRING VET

Meaux

INVOICE

49528

DATE

1-12-22

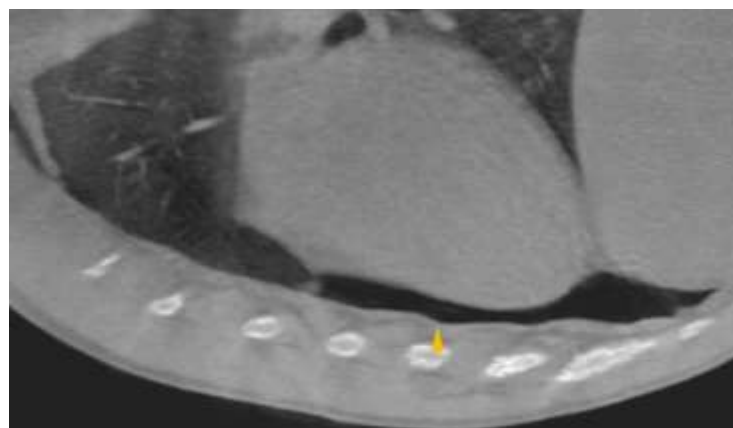
INTERPRETATION OF THE FINDINGS & FURTHER RECOMMENDATIONS

The CT study reveals multiple comminuted impression fractures of the facial bones including the frontal and nasal bones, left orbita, as well as of the cribriform plate. The cribriform plate fragments cause impingement of the frontal lobes of the brain.

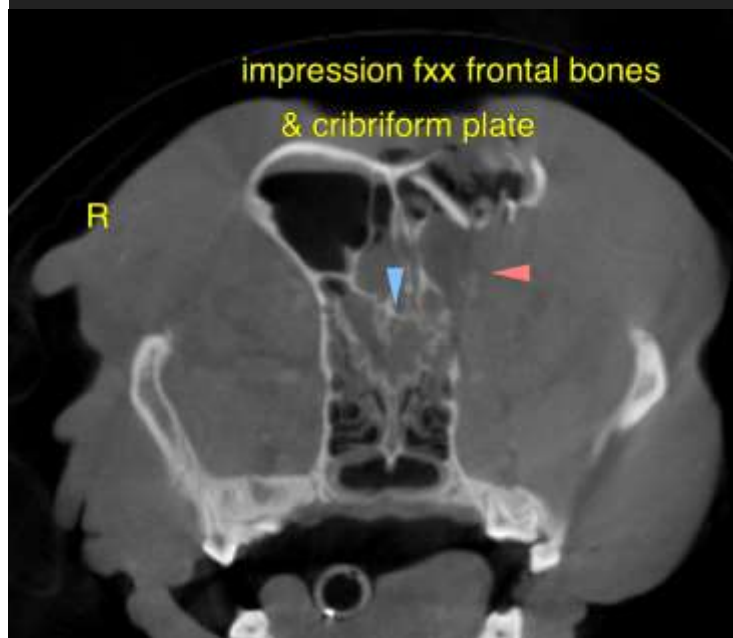
Left eye impingement secondary to fracture of the left orbita is seen.

There is subcutaneous emphysema secondary to fracture of the nasal cavities and frontal sinuses.

The mild pneumothorax is likely secondary to Valsalva maneuver or blunt thoracic trauma. The amount of free pleural air is very mild at this point.



mild pneumothorax



impression fxx frontal bones
& cribriform plate



PATIENT

Bohdi Osceola

SPECIES

Canine

BREED

Pitbull

SEX

Intact Male

AGE

1 Year, 2 Months

INTERPRETED BY

Nele Eley, DVM
Dr. med. Vet. DipECVDI

HOSPITAL NAME

Mobile Pet Imaging

REFERRING VET

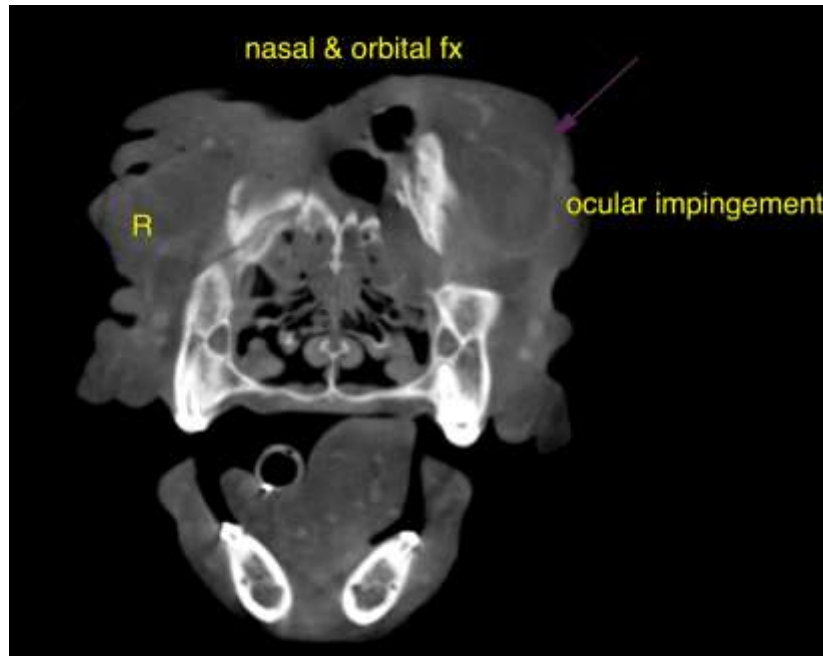
Meaux

INVOICE

49528

DATE

1-12-22



The information and recommendations provided are based on the images presented by the referring veterinarian. No evaluation can be communicated regarding pathology that was not visible in the image/video clips provided.

Thank you for this referral. If the clinical or image interpretation does not parallel your findings or if I can be of any further assistance please contact me.

Nele Eley, DVM, Dr. med. vet., DipECVDI
European Specialist in Veterinary Diagnostic Imaging, Cert. Radiology,
Senior lecturer University of Giessen, Germany, Veterinary Faculty, Department of Radiology
Nele.Eley@sonopath.com