

**PATIENT**

Sydney Dufort

**PRESENTING CLINICAL SIGNS**

coughing mostly when excited but can be when at rest. duration is a couple of months. will gag after often. severe dental disease,  
Abnormal PE/Chem/CBC/UA Results: labs look good except high globulin

**SPECIES**

Canine

**RADIOGRAPHIC STUDY OF THE THORAX**

Right/left lateral and ventrodorsal views totaling 3 images available for review.

**BREED**

Chihuahua Mix

**RADIOGRAPHIC FINDINGS**

The patient is mildly obese.

Moderate dorsoventral collapse of the cervical trachea is seen on the left lateral view.  
Redundancy of the dorsal tracheal ligament is present on the right lateral view.

**SEX**

MN

There is mild esophageal aerophagia.

**AGE**

11 Years

The lung is moderately inflated. A moderate generalized bronchial lung pattern with mild peribronchial cuffing is seen.

No radiographic evidence of cardiovascular pathology is noted.

There is mild generalized hepatomegaly.

**INTERPRETED BY**

Nele Eley, DVM  
Dr. med. Vet. DipECVDI

**RADIOGRAPHIC DIAGNOSIS**

- Dynamic tracheal disease.
- Moderate chronic lower airway pattern.
- Hepatomegaly.

**HOSPITAL NAME**

Boca Park Animal  
Hospital

**INTERPRETATION OF THE FINDINGS & FURTHER RECOMMENDATIONS**

The radiographic findings are compatible with dynamic tracheal disease. The tracheal collapse appears to affect mostly the cervical tracheal. No evidence of concurrent bronchial collapse is seen; however, there appears to be concurrent chronic lower airway disease in terms of irritant/eosinophilic bronchopneumopathy versus infectious bronchitis. Consider further evaluation of the upper and lower airways with lower airway sampling for further definition.

**REFERRING VET**

Ensign

Note the tracheal collapse appears to start immediately caudal of the larynx which may render this patient an unsuitable candidate for stenting.

**INVOICE**

49490

Differential diagnosis for the hepatomegaly includes metabolic/endocrine hepatopathy. Diffuse infiltrate disease or hepatitis cannot be ruled out.

**DATE**

1-11-22



**PATIENT**

Sydney Dufort

**SPECIES**

Canine

**BREED**

Chihuahua Mix

**SEX**

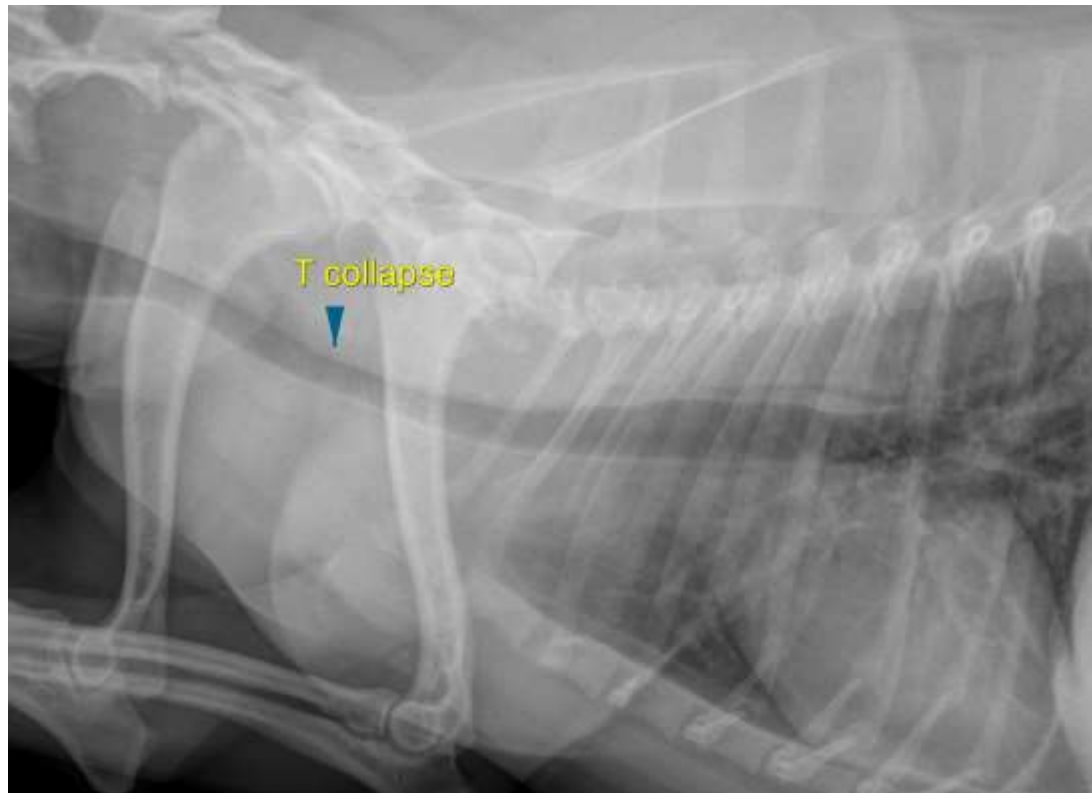
MN

**AGE**

11 Years

**INTERPRETED BY**

Nele Eley, DVM  
Dr. med. Vet. DipECVDI



**HOSPITAL NAME**

Boca Park Animal  
Hospital

**REFERRING VET**

Ensign

**INVOICE**

49490

**DATE**

1-11-22

The information and recommendations provided are based on the images presented by the referring veterinarian. No evaluation can be communicated regarding pathology that was not visible in the image/video clips provided.

Thank you for this referral. If the clinical or image interpretation does not parallel your findings or if I can be of any further assistance please contact me.

**Nele Eley**, DVM, Dr. med. vet., DipECVDI  
European Specialist in Veterinary Diagnostic Imaging, Cert. Radiology,  
Senior lecturer University of Giessen, Germany, Veterinary Faculty, Department of Radiology  
Nele.Eley@sonopath.com