

**PATIENT**

Remi Upton

PRESENTING CLINICAL SIGNS

Hx of dyschezia and intermittent diarrhea. Radiographs yesterday showed gas filled stomach, small intestine, colon. Originally vomited several times. Clinical signs began 1 week ago after being at day care. Has been on metronidazole, cerenia. Still inappetent

SPECIES

Canine

Abnormal PE/Chem/CBC/UA Results: Bloodwork 2 days ago unremarkable T, P, R - WNL

RADIOGRAPHIC STUDY OF THE ABDOMEN

Right lateral and ventrodorsal views totaling 4 images available for review.

BREED

Labrador

RADIOGRAPHIC FINDINGS

The abdominal serosal detail is within normal limits.

SEX

MN

The stomach is empty except for a mild amount of gas.

The small intestinal loops are evenly distributed throughout the ventral abdomen and of even diameter. No radiopaque foreign material is seen. There is no evidence of plication or abnormal dilation of the small intestine.

AGE

4

The colon contains a moderate amount of gas and a mild amount of fecal material.

No organomegaly or mass effect is seen.

INTERPRETED BY

Nele Eley, DVM
Dr. med. Vet. DipECVDI

RADIOGRAPHIC DIAGNOSIS

- No radiographic evidence of mechanical ileus.

INTERPRETATION OF THE FINDINGS & FURTHER RECOMMENDATIONS**HOSPITAL NAME**

Torch Lake
Veterinary Clinic

The radiographic presentation of the gastrointestinal tract parallels the history of maldigestion/diarrhea. No evidence of mechanical ileus is seen radiographically. Functional ileus appears likely. Based on the longer standing clinical history and lacking response to the initiated management, further workup by means of ultrasound appears reasonable at this point, along with laboratory workup and eventual further diagnostics such as endoscopy or other.

REFERRING VET

Adrienne Waffle

INVOICE

49447

DATE

1-11-22



PATIENT

Remi Upton

SPECIES

Canine

BREED

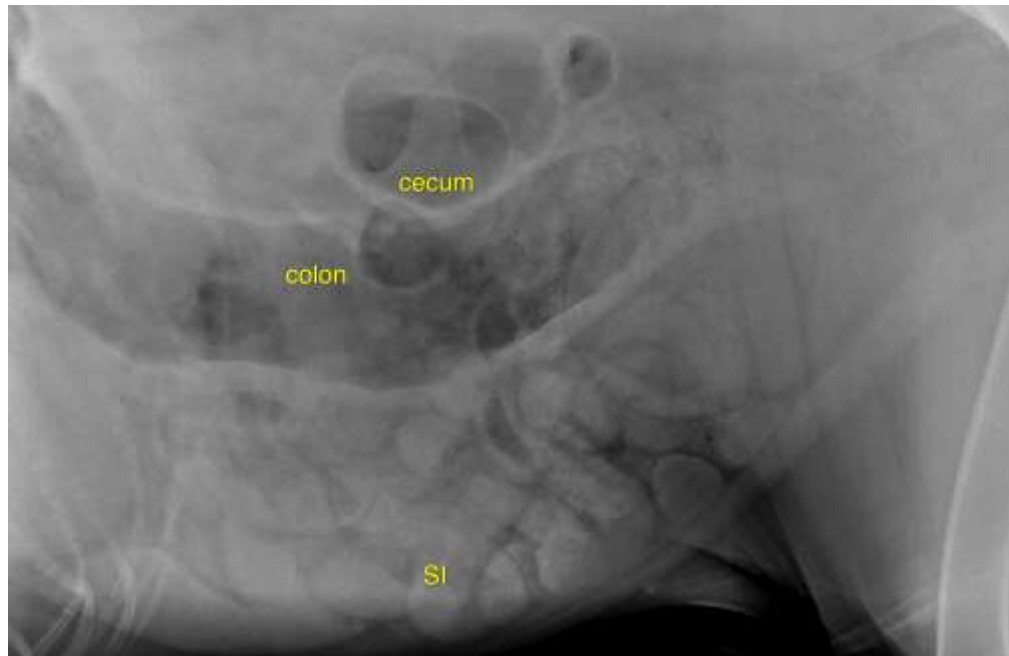
Labrador

SEX

MN

AGE

4



INTERPRETED BY

Nele Eley, DVM
Dr. med. Vet. DipECVDI

HOSPITAL NAME

Torch Lake
Veterinary Clinic

REFERRING VET

Adrienne Waffle

INVOICE

49447

DATE

1-11-22

The information and recommendations provided are based on the images presented by the referring veterinarian. No evaluation can be communicated regarding pathology that was not visible in the image/video clips provided.

Thank you for this referral. If the clinical or image interpretation does not parallel your findings or if I can be of any further assistance please contact me.

Nele Eley, DVM, Dr. med. vet., DipECVDI
European Specialist in Veterinary Diagnostic Imaging, Cert. Radiology,
Senior lecturer University of Giessen, Germany, Veterinary Faculty, Department of Radiology
Nele.Eley@sonopath.com