



PATIENT PRESENTING CLINICAL SIGNS

Winston Knight lethargy since vigorous play at daycare last week; intermittent vomiting (1-2x monthly). Unfasted, eats raw diet. Good appetite, normal stools.
SPECIES Abnormal PE/Chem/CBC/UA Results: Abnormal PE: neck discomfort apparent- neck carriage is stiff. Intermittent fasciculation of neck and shoulder muscles. Decreased cervical ROM in all directions- tense. Left hip clicks with extension/flexion. Mild borborygmi with cranial abdominal palpation. Normal HR, RR, and temp, euhydrated. CPs present x 4. Mentation appropriate Labs: CBC, chemistry both WNL Differentials: muscle strain vs IVDD; also concern for L hip dysplasia Current tx plan: meloxicam SID x 14 days, methocarbamol TID x 5 days, exercise restriction x 14 days then gradual return.
 Canine
BREED

French Bulldog **RADIOGRAPHIC STUDY OF THE ABDOMEN & THORACOLUMBAR SPINE**

Lateral and orthogonal whole body views totaling 5 images available for review.

SEX RADIOGRAPHIC FINDINGS

MN **Abdomen**

AGE A mild amount of gravel is seen in a postprandial stomach.

2 Years Crowding of the small intestine in the center of the abdomen is noted with no evidence of abnormal dilation, plication, or radiopaque foreign material.

INTERPRETED BY The lower esophageal sphincter appears to be in the abdomen in all available images. No hiatal hernia is seen.

Nele Eley, DVM
 Dr. med. Vet. DipECVDI

The kidneys, liver, spleen, and urinary bladder present within the expected limits.

HOSPITAL NAME Subluxation of the left femoral head is seen with a flat acetabular groove and significantly reduced femoral head coverage. The joint space is severely diverging.

Northshore
 Veterinary Hospital

Spine

Multiple congenital vertebral malformations are noted within the thoracic spine with hemivertebrae at T2, T3, T4, T5, T7, T8, T9, T11; kissing spines between T4 and T5, and T9 and T10; kyphosis and stenosis of the caudal thoracic spine centered over T11.

REFERRING VET

Karla Schultz

Spondylosis deformans is noted between T11/12, T12/13, and T6/7.

INVOICE

Chondroid disc degeneration with mineralizations between T13 and L1 and narrowing of the T13/L1 intervertebral disc space are seen.

56088

RADIOGRAPHIC DIAGNOSIS

DATE

1-10-23

- Gastrointestinal maldigestion pattern and gastric gravel without gastric dilation.
- Severe canine hip dysplasia with subluxation of the left coxofemoral joint.
- Multiple congenital vertebral malformations with caudal thoracic kyphosis and stenosis.
- Intervertebral disc disease T13/L1.



PATIENT

Winston Knight

- Multifocal spondyloses between T6/7, T11/12, and T12/13.

INTERPRETATION OF THE FINDINGS & FURTHER RECOMMENDATIONS

The radiographic study reveals no evidence of mechanical ileus. The gastric gravel is likely due to prior intake of mineral material. A true gravel sign is typically associated with gastric dilation. However, impaired gastric outflow cannot be ruled out entirely and further definition by means of abdominal ultrasound should be considered in case of persisting clinical signs.

SPECIES

Canine

BREED

French Bulldog

SEX

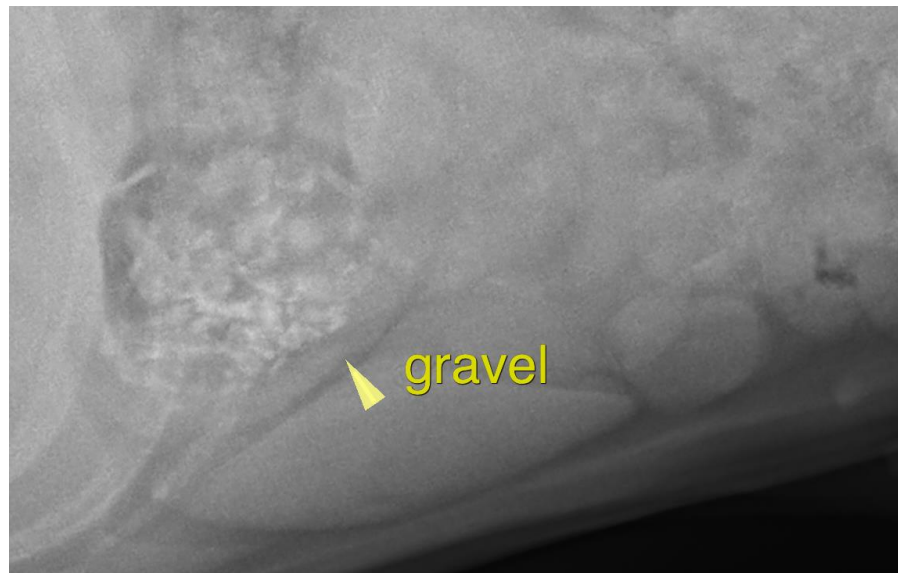
MN

AGE

2 Years

INTERPRETED BY

Nele Eley, DVM
Dr. med. Vet. DipECVDI



HOSPITAL NAME

Northshore
Veterinary Hospital

REFERRING VET

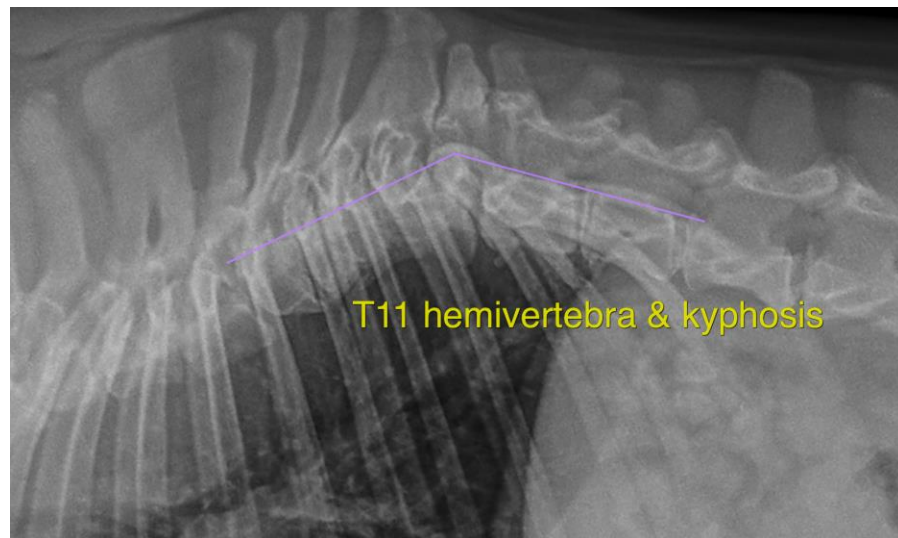
Karla Schultz

INVOICE

56088

DATE

1-10-23





PATIENT

Winston Knight

The information and recommendations provided are based on the images presented by the referring veterinarian/sonographer. No evaluation can be communicated regarding pathology that was not visible in the image/video clips provided.

SPECIES

Canine

Thank you for this referral. If the clinical or image interpretation does not parallel your findings or if I can be of any further assistance please contact me.

BREED

French Bulldog

Nele Eley, DVM, Dr. med. vet., DipECVDI
European Specialist in Veterinary Diagnostic Imaging, Cert. Radiology,
Senior lecturer University of Giessen, Germany, Veterinary Faculty, Department of Radiology
Nele.Eley@sonopath.com

SEX

MN

AGE

2 Years

INTERPRETED BY

Nele Eley, DVM
Dr. med. Vet. DipECVDI

HOSPITAL NAME

Northshore
Veterinary Hospital

REFERRING VET

Karla Schultz

INVOICE

56088

DATE

1-10-23