

**PATIENT**

Maximus Munoz

PRESENTING CLINICAL SIGNS

bloody nasal discharge

SPECIES

Canine

COMPUTED TOMOGRAPHIC STUDY OF THE HEAD

Plain and post contrast studies available for review.

BREED

Boxer Mix

COMPUTED TOMOGRAPHIC FINDINGS

Extensive turbinate destruction is seen within the right nasal cavity. The remaining turbinates present swelling of their mucosal lining. Swelling of the peripheral mucosal lining of the right nasal cavity is seen as well. There is a mild amount of fluid attenuating material within the right nasal cavity and right frontal sinus. The right frontal sinus presents polypoid mucosal proliferation as well as swelling of its mucosal lining and hyperostosis of the osseous lamina externa. The cribriform plate is intact. No evidence of foreign material or a mass is identified.

SEX

Male

The regional lymph nodes present within normal limits.

AGE

9 Years, 6 Months

The triadan 207 is absent. Horizontal wear of the triadans 108, 109, 208, 209, 308, 309, 408, and 409 is seen.

A small otolith is seen within the right tympanic bulla. A mild amount of hypoattenuating material is present within both external auditory meatuses. The epithelial lining of the external auditory meatuses presents moderate generalized thickening with diffusely increased contrast enhancement.

INTERPRETED BYNele Eley, DVM
Dr. med. Vet. DipECVDI**COMPUTED TOMOGRAPHIC DIAGNOSIS**

- Chronic unilateral destructive rhinosinusitis.
- Bilateral otitis externa.

HOSPITAL NAMEAloha Pet & Bird
Hospital**INTERPRETATION OF THE FINDINGS & FURTHER RECOMMENDATIONS**

The CT study reveals unilateral right sided chronic destructive rhinosinusitis. Unilateral fungal rhinosinusitis secondary to aspergillus infection is considered most likely. Other fungal infection and bacterial rhinitis cannot be ruled out entirely but are thought less likely. There is no evidence of foreign material at the time of the examination. Consider further verification by means of rhinoscopy with sampling if not performed already.

REFERRING VET

Dr. Pepen

Otoscopy workup could be considered as well depending on the presence of clinical signs.

INVOICE

49448

DATE

1-10-22



PATIENT

Maximus Munoz

SPECIES

Canine

BREED

Boxer Mix

SEX

Male

AGE

9 Years, 6 Months

INTERPRETED BY

Nele Eley, DVM
Dr. med. Vet. DipECVDI

HOSPITAL NAME

Aloha Pet & Bird
Hospital

REFERRING VET

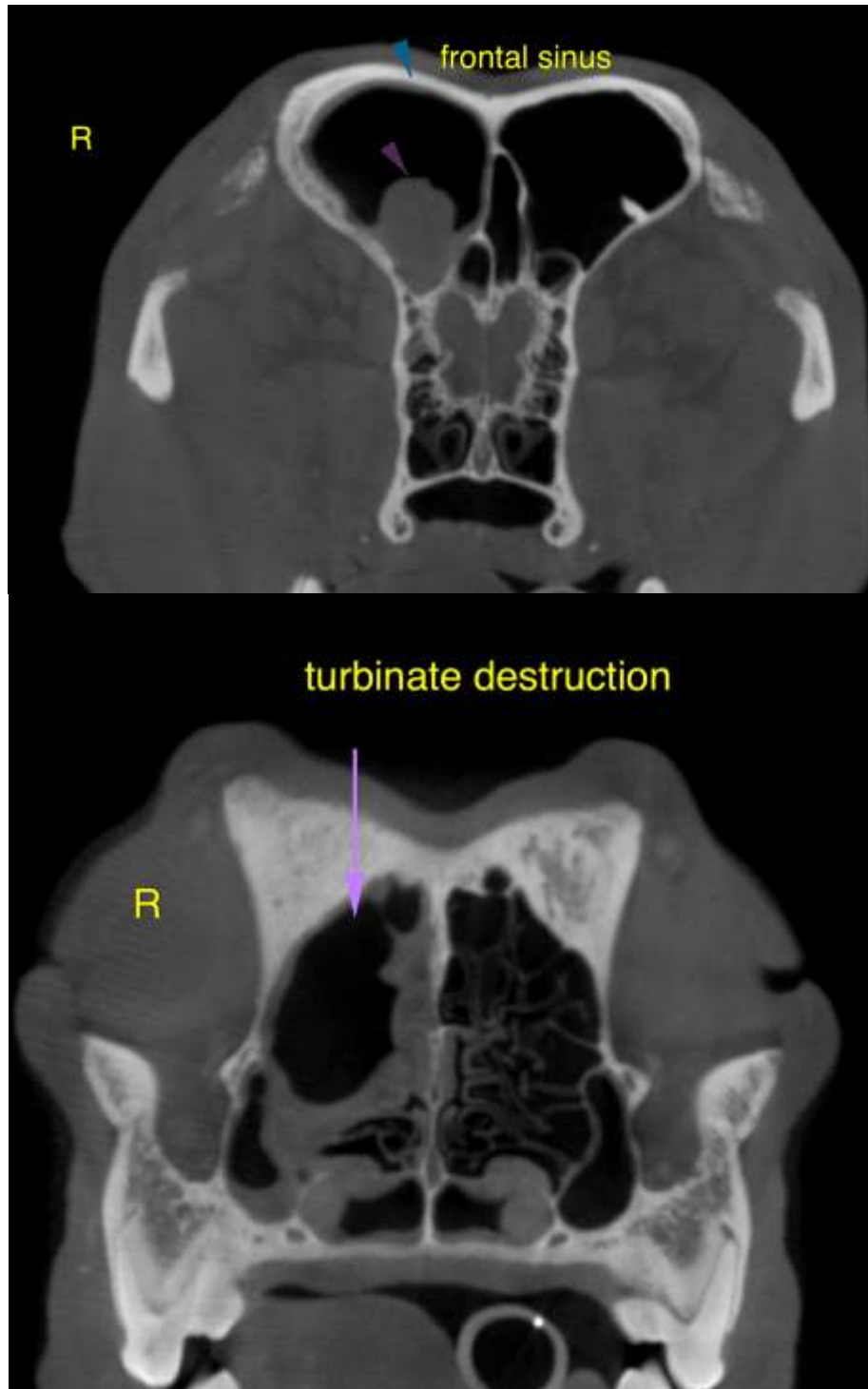
Dr. Pepen

INVOICE

49448

DATE

1-10-22





PATIENT

Maximus Munoz

The information and recommendations provided are based on the images presented by the referring veterinarian. No evaluation can be communicated regarding pathology that was not visible in the image/video clips provided.

SPECIES

Canine

Thank you for this referral. If the clinical or image interpretation does not parallel your findings or if I can be of any further assistance please contact me.

BREED

Boxer Mix

Nele Eley, DVM, Dr. med. vet., DipECVDI
European Specialist in Veterinary Diagnostic Imaging, Cert. Radiology,
Senior lecturer University of Giessen, Germany, Veterinary Faculty, Department of Radiology
Nele.Eley@sonopath.com

SEX

Male

AGE

9 Years, 6 Months

INTERPRETED BY

Nele Eley, DVM
Dr. med. Vet. DipECVDI

HOSPITAL NAME

Aloha Pet & Bird
Hospital

REFERRING VET

Dr. Pepen

INVOICE

49448

DATE

1-10-22