



**PATIENT**

Hoover Wilson

**PRESENTING CLINICAL SIGNS**

On Jan 6th presented to RDVM. for lameness of RF leg. Could move around a little bit but cannot put weight on it. No swelling, no noticeable injury, no heat Radiographs done by RDVM: R shoulder- evidence of ulnar growth plate fracture Looks somewhat old with sclerotic edges but on dorsal aspect small defect. R elbow- Small defect on dorsal aspect of GP repeatable. DV fracture line evident. Markedly different when compared to LF. Suspect ulnar GP fracture. Referred to AHP Sx department Since day of presentation has been using leg more and seems more comfortable.

**SPECIES**

Canine

**BREED**

Basset Hound

**COMPUTED TOMOGRAPHIC STUDY OF THE FOREARMS**

Plain study in bone and soft tissue windows available for review.

**COMPUTED TOMOGRAPHIC FINDINGS**

**SEX**

M

The right distal ulnar growth plate is widened and appears to be completely open. The left distal ulnar growth plate is closed or collapsed. There is a total length difference between the left and right ulnar of 1.0 cm with the left ulnar measuring 10.0 cm and the right ulnar measuring 11.0 cm in length.

**AGE**

10 Months

Bilateral dorsal and medial curvature of the radius is seen with carpus valgus deformity and cubital distraction. The valgus angle is 19 degrees in the right front limb and 24 degrees in the left front limb. The cranial curvature of the radius is 35 degrees in the right front limb and 45 degrees in the left front limb.

**INTERPRETED BY**

Nele Eley, DVM  
Dr. med. Vet. DipECVDI

The humeroulnar joint space is asymmetrically widened in both elbows which is combined with a radioulnar step formation of 2mm on the left and 1mm on the right side.

**COMPUTED TOMOGRAPHIC DIAGNOSIS**

**HOSPITAL NAME**

Animal Health Partners

- Suspect chondrodysplasia or other disturbed endochondral ossification with premature closure of the left distal ulnar growth plate and radius curvus, carpus valgus, and cubital distraction.
- Disturbed endochondral ossification with persistently open right distal ulnar growth plate and radius curvus, carpus valgus, and cubital distraction in the right front limb.

**REFERRING VET**

Dr. Jeffery Biskup

**INTERPRETATION OF THE FINDINGS & FURTHER RECOMMENDATIONS**

The CT study reveals stunted longitudinal growth which is within the breed related limits as well as angular limb deformity in terms of radius curvus, carpus valgus, and cubital distraction in both front limbs. The degree of deformity is more pronounced in the left front limb which is in concordance with the complete and premature closure of the distal left ulnar growth plate. However, disturbed ossification of the right distal ulnar growth plate appears to preclude appropriate closure of the growth plate and is associated with similar angular limb deformity even if slightly milder in degree. The underlying cause of the disturbed endochondral ossification may well be achondroplasia/osteochondrodystrophy or other type of hereditary and disturbed endochondral ossification; however, additional trauma cannot be ruled out. The fact that the right distal ulnar growth plate is still open may be associated with prolonged activity and prolonged longitudinal growth which would explain that the right ulnar is 1.0 cm longer when compared with the left side.

**INVOICE**

49431

**DATE**

1-10-22



**PATIENT**

Hoover Wilson

**SPECIES**

Canine

**BREED**

Basset Hound

**SEX**

M

**AGE**

10 Months

**INTERPRETED BY**

Nele Eley, DVM  
Dr. med. Vet. DipECVDI

**HOSPITAL NAME**

Animal Health  
Partners

**REFERRING VET**

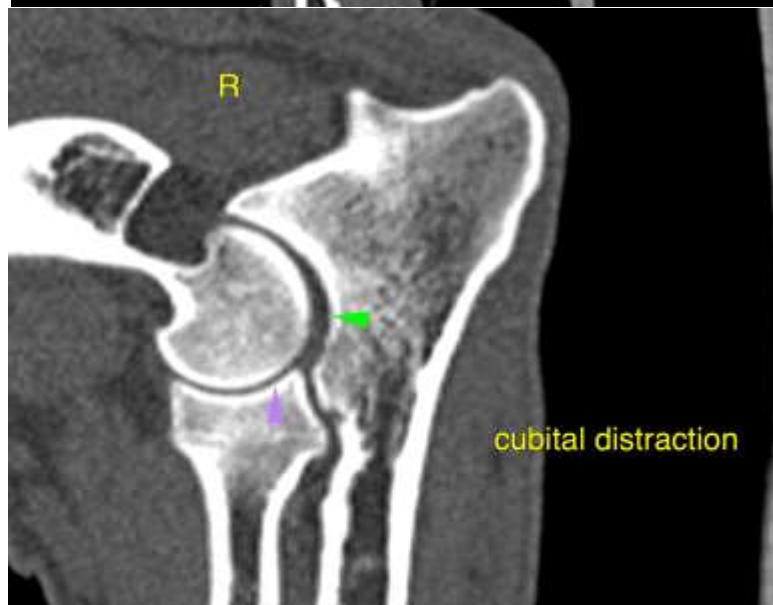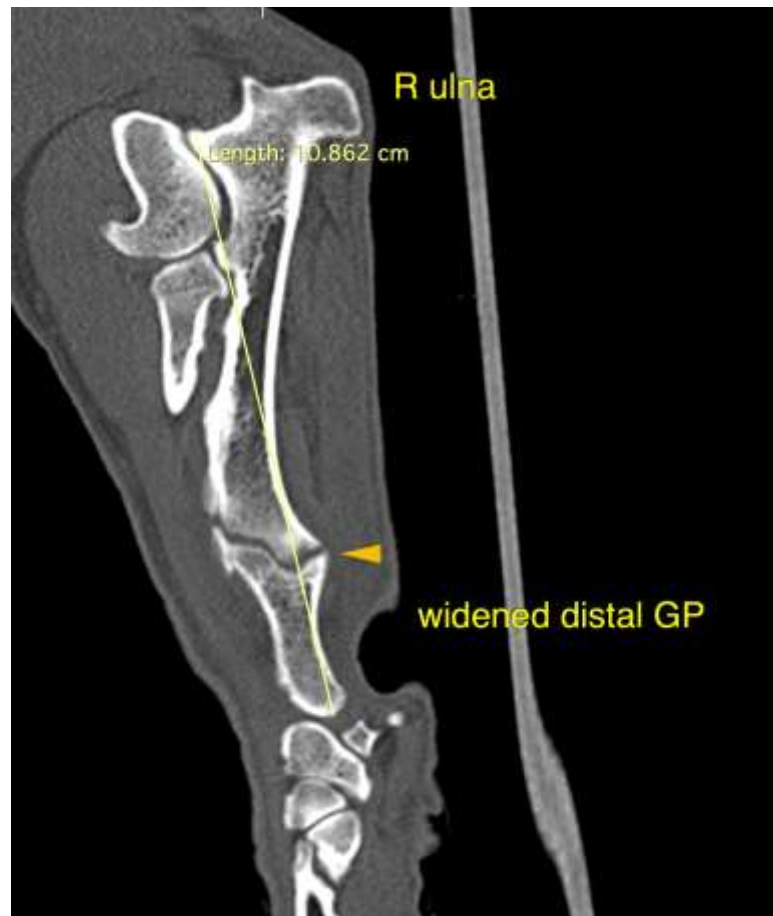
Dr. Jeffery Biskup

**INVOICE**

49431

**DATE**

1-10-22





**PATIENT**

Hoover Wilson

**SPECIES**

Canine

**BREED**

Basset Hound

**SEX**

M

**AGE**

10 Months

**INTERPRETED BY**

Nele Eley, DVM  
Dr. med. Vet. DipECVDI

**HOSPITAL NAME**

Animal Health  
Partners

**REFERRING VET**

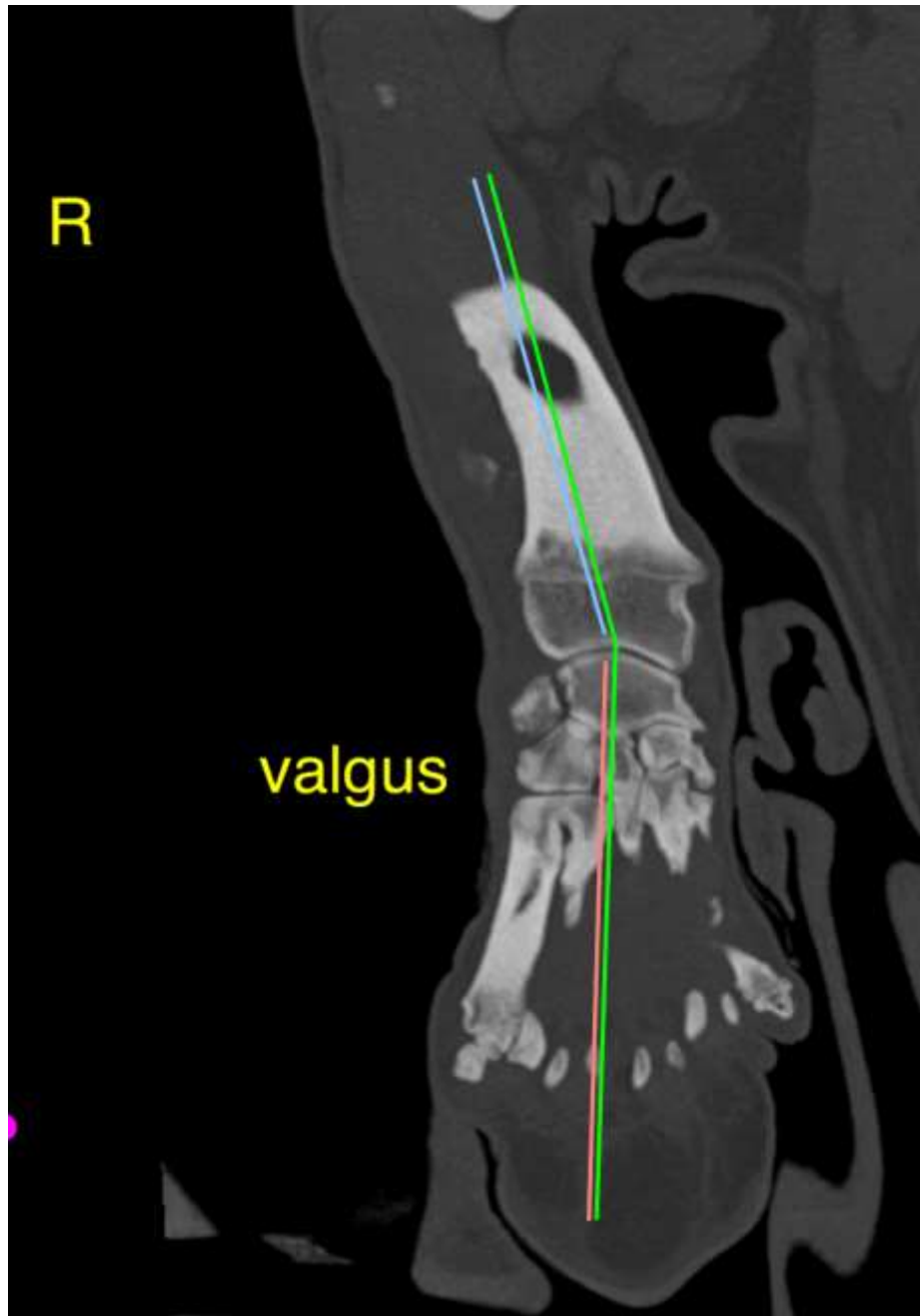
Dr. Jeffery Biskup

**INVOICE**

49431

**DATE**

1-10-22





**PATIENT**

Hoover Wilson

**SPECIES**

Canine

**BREED**

Basset Hound

**SEX**

M

**AGE**

10 Months

**INTERPRETED BY**

Nele Eley, DVM  
Dr. med. Vet. DipECVDI

**HOSPITAL NAME**

Animal Health  
Partners

**REFERRING VET**

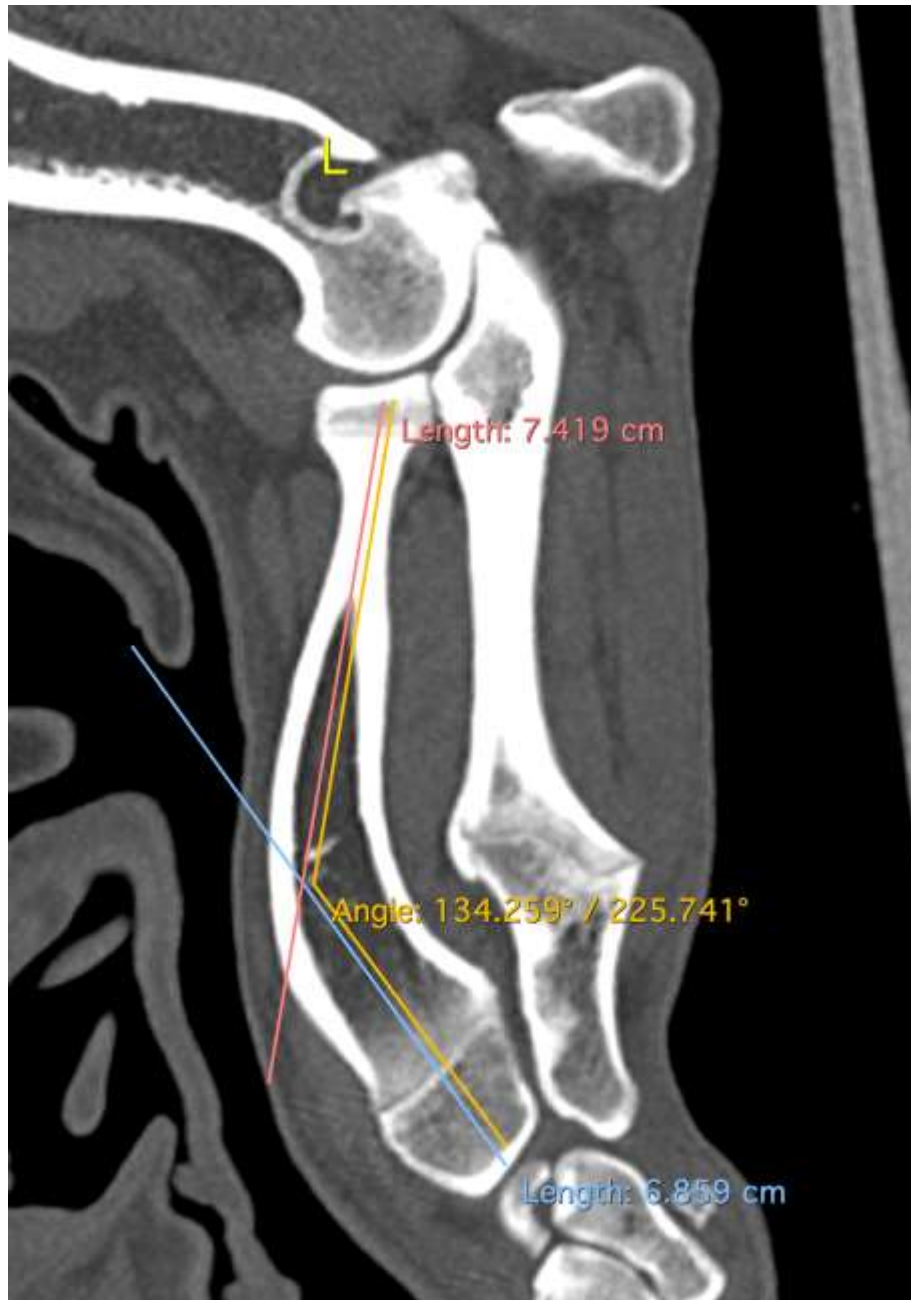
Dr. Jeffery Biskup

**INVOICE**

49431

**DATE**

1-10-22





**PATIENT**

Hoover Wilson

**SPECIES**

Canine

**BREED**

Basset Hound

**SEX**

M

**AGE**

10 Months

**INTERPRETED BY**

Nele Eley, DVM  
Dr. med. Vet. DipECVDI

**HOSPITAL NAME**

Animal Health  
Partners

**REFERRING VET**

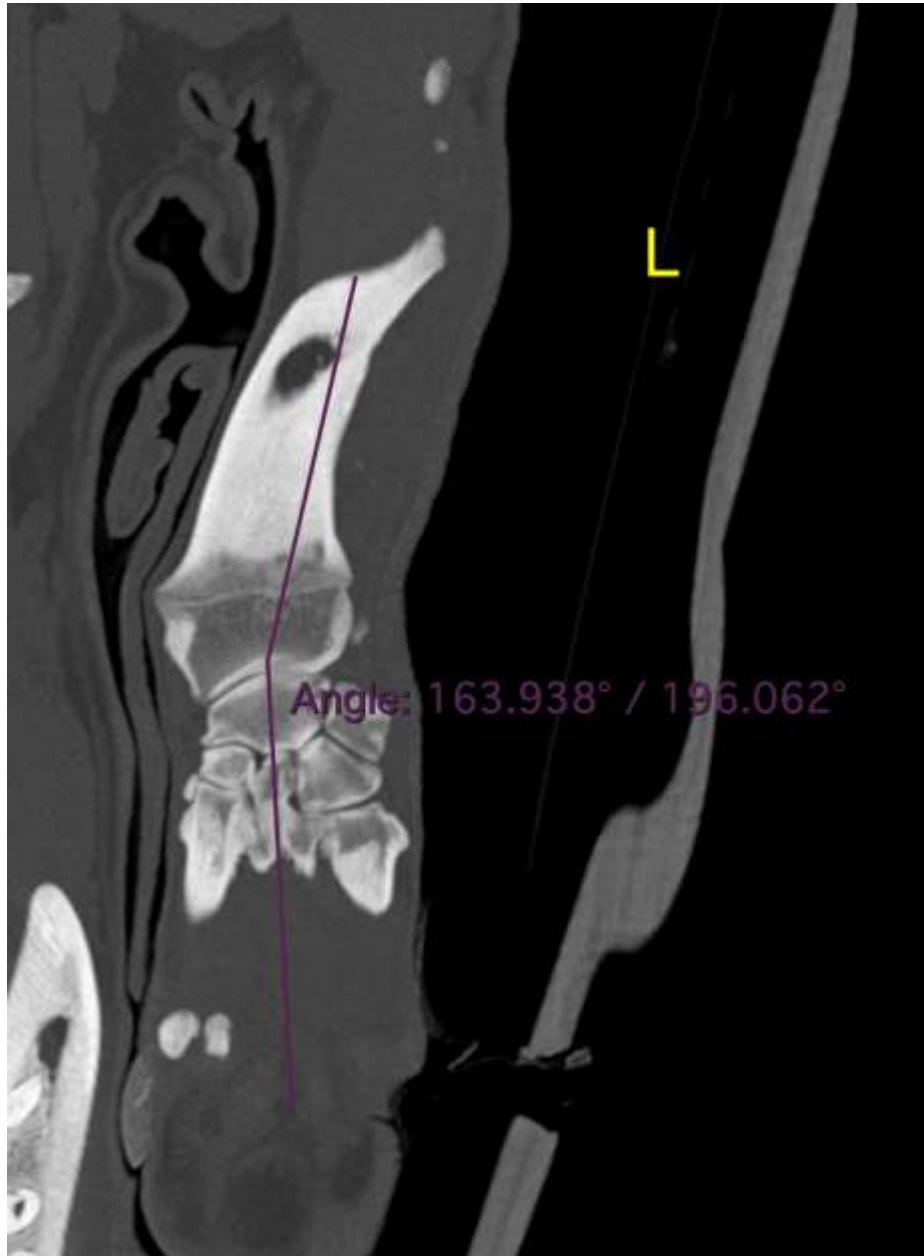Dr. Jeffery Biskup

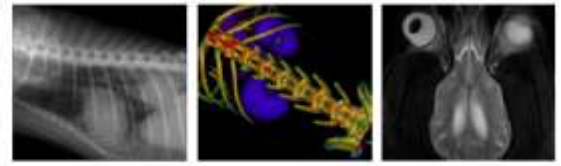
**INVOICE**

49431

**DATE**

1-10-22





**PATIENT**

Hoover Wilson

**SPECIES**

Canine

**BREED**

Basset Hound

**SEX**

M

**AGE**

10 Months

**INTERPRETED BY**

Nele Eley, DVM  
Dr. med. Vet. DipECVDI

**HOSPITAL NAME**

Animal Health  
Partners

**REFERRING VET**

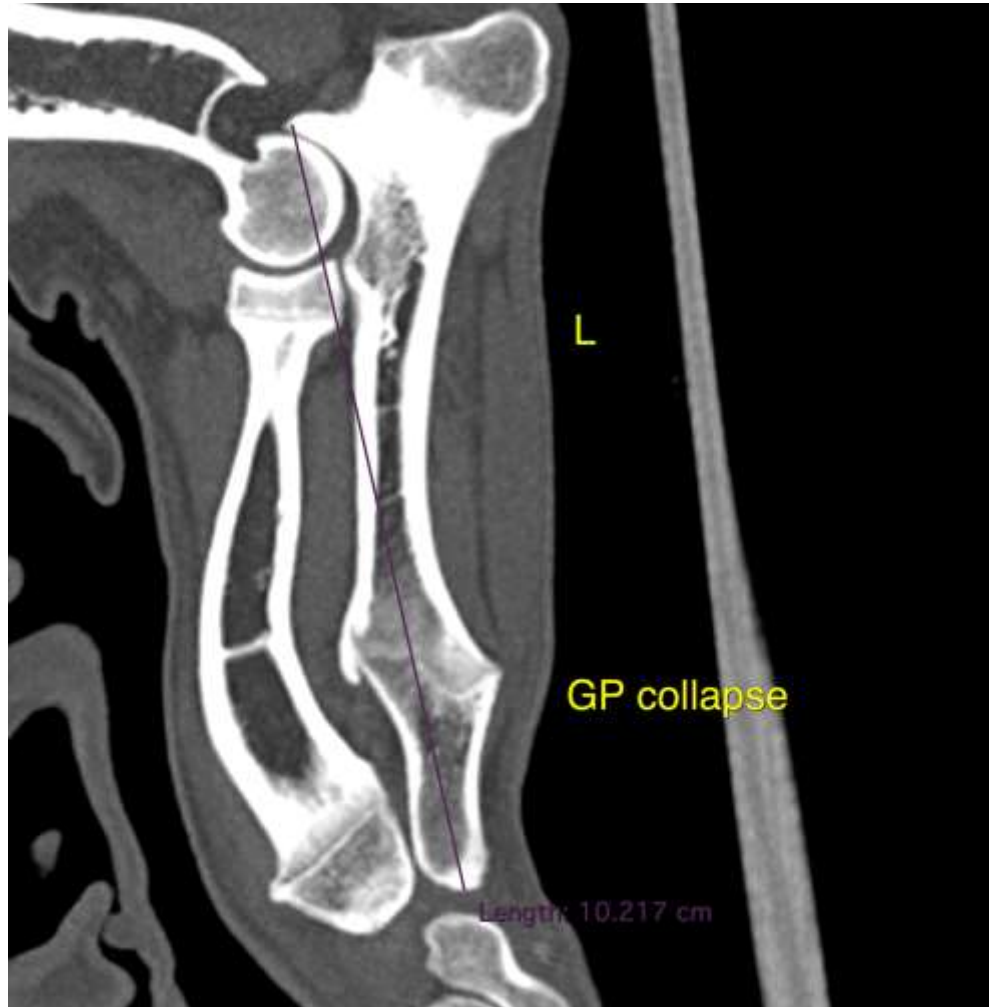Dr. Jeffery Biskup

**INVOICE**

49431

**DATE**

1-10-22



The information and recommendations provided are based on the images presented by the referring veterinarian. No evaluation can be communicated regarding pathology that was not visible in the image/video clips provided.

Thank you for this referral. If the clinical or image interpretation does not parallel your findings or if I can be of any further assistance please contact me.

**Nele Eley**, DVM, Dr. med. vet., DipECVDI  
European Specialist in Veterinary Diagnostic Imaging, Cert. Radiology,  
Senior lecturer University of Giessen, Germany, Veterinary Faculty, Department of Radiology  
Nele.Eley@sonopath.com