



PATIENT

Enzo Jimenez

PRESENTING CLINICAL SIGNS

Patient presents to the emergency room for seizures on Friday, January 7. It was only that episodes of seizure after that she has not presented more episodes.
Abnormal PE/Chem/CBC/UA Results: CBC --- unremarkable CHEM --- unremarkable

SPECIES

Canine

COMPUTED TOMOGRAPHIC STUDY OF THE HEAD

Plain and post contrast studies available for review.

BREED

Lab Mix

COMPUTED TOMOGRAPHIC FINDINGS

The brain presents no deviation from normal anatomy and symmetry. The grey and white matter distinction and the neuroparenchymal attenuation are as expected. The distribution of contrast enhancement is within normal limits throughout the parenchyma and meninges. The ventricular system is non-dilated and within the limits of the expected volume and symmetry.

SEX

NM

Thin and smoothly folded conchae and turbinates with even smooth mucosal lining.

AGE

2 Years

Both temporomandibular joints present congruent joint spaces with even subchondral bone surfaces and are considered within normal limits.

A small otolith is seen within the left tympanic bulla. The right tympanic bulla presents within normal limits. The external auditory meatuses present within normal limits.

INTERPRETED BY

Nele Eley, DVM
Dr. med. Vet. DipECVDI

The submandibular and medial retropharyngeal lymph nodes are small and elongated with a normal short-to-long-axis-ratio is < 0.5, the attenuation and contrast enhancement pattern is uniform.

The salivary glands present within normal limits.

HOSPITAL NAME

Veterinary Image
Center

The visible dentition is within normal limits.

Both tonsils are enlarged and everted.

COMPUTED TOMOGRAPHIC DIAGNOSIS

REFERRING VET

Dr. F. Ortiz Vidal

- Structurally normal CT study of the brain.
- Mild bilateral tonsillitis.

INTERPRETATION OF THE FINDINGS & FURTHER RECOMMENDATIONS

INVOICE

49440

The CT study of the head reveals no structural evidence of brain injury which increases the potential for primary epilepsy. Complementary csf analysis could be considered for further verification if not performed already.

DATE

1-10-22



PATIENT

Enzo Jimenez

SPECIES

Canine

BREED

Lab Mix

SEX

NM

AGE

2 Years

INTERPRETED BY

Nele Eley, DVM
Dr. med. Vet. DipECVDI

HOSPITAL NAME

Veterinary Image
Center

REFERRING VET

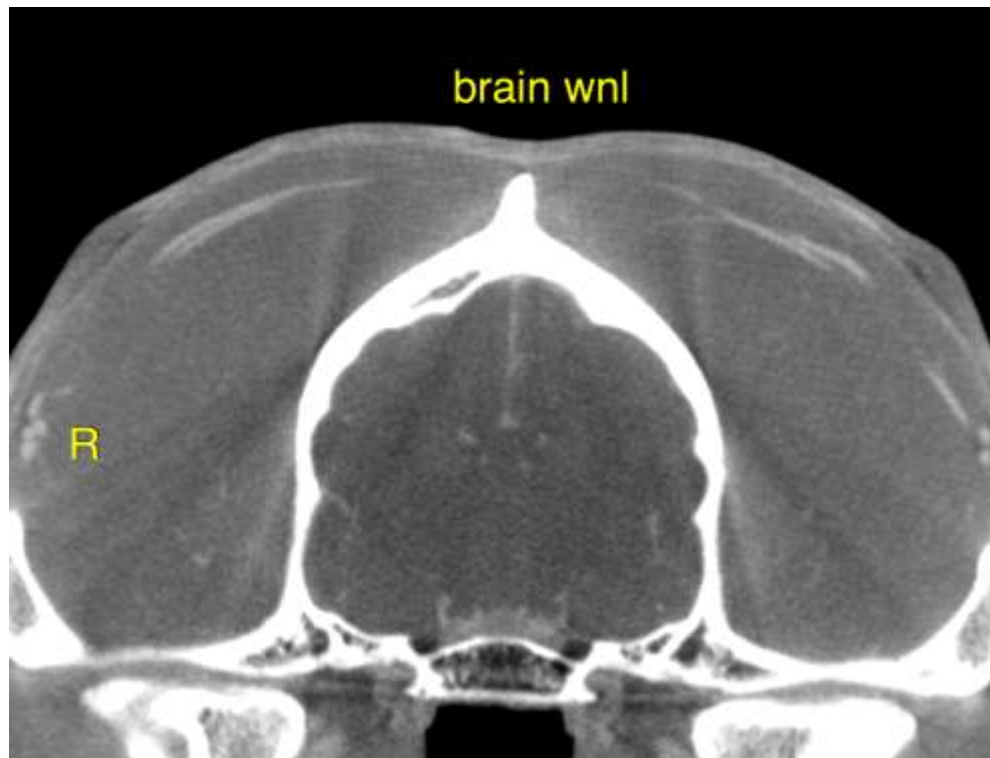
Dr. F. Ortiz Vidal

INVOICE

49440

DATE

1-10-22



The information and recommendations provided are based on the images presented by the referring veterinarian. No evaluation can be communicated regarding pathology that was not visible in the image/video clips provided.

Thank you for this referral. If the clinical or image interpretation does not parallel your findings or if I can be of any further assistance please contact me.

Nele Eley, DVM, Dr. med. vet., DipECVDI
European Specialist in Veterinary Diagnostic Imaging, Cert. Radiology,
Senior lecturer University of Giessen, Germany, Veterinary Faculty, Department of Radiology
Nele.Eley@sonopath.com