

**PATIENT**

Casper Swofford

PRESENTING CLINICAL SIGNS

Hx of feline asthma. Owners drive a semi and went from Florida to Texas, back to Colorado. Abdominal breathing over the weekend. Owners have been using a prednisone inhaler 8-10 times daily and Casper has been on 3L flow by oxygen. DVM: No murmur or arrhythmia. Crackles appreciated on auscultation with increased lung sounds.

SPECIES

Feline

RADIOGRAPHIC STUDY OF THE THORAX

Right/left lateral and ventrodorsal views totaling 3 images available for review.

BREED

DMH

RADIOGRAPHIC FINDINGS

The lungs are deeply inflated. The ribcage is mildly expanded.

SEX

NM

There is a moderate generalized bronchial lung pattern with marked peribronchial cuffing. The pulmonary opacity appears to be slightly increased in the left lung which, however, may be a result of consecutive positional atelectasis.

The radiographic presentation of the cardiac silhouette is within normal limits.

AGE

5

No evidence of mediastinal lymphadenomegaly is noted.

Course and width of the trachea are considered within normal limits.

INTERPRETED BY

Nele Eley, DVM
Dr. med. Vet. DipECVDI

Moderate gastrointestinal aerophagia is noted as a sign of dyspnea.

RADIOGRAPHIC DIAGNOSIS

- Moderate generalized active lower airway pattern.
- Aerophagia.

HOSPITAL NAME

Elizabeth Animal
Hospital

INTERPRETATION OF THE FINDINGS & FURTHER RECOMMENDATIONS

The radiographic changes generally fit the tentative diagnosis of feline asthma / allergic lower airway syndrome with active inflammation; however, infectious bronchitis such as viral, bacterial, parasitic, or less likely protozoal or fungal is a potential differential diagnosis which appears to be valid in this case in particular owing to the travel history of the patient. Should the patient continue to respond to the asthma medication incompletely, a clinical trial of treatment for infectious bronchitis could be considered versus further definition by means of airway sampling and lung worm testing.

REFERRING VET

Carlos Fuentes, DVM/
Leon Anderson, DVM

INVOICE

49452

DATE

1-10-22



PATIENT

Casper Swofford

SPECIES

Feline

BREED

DMH

SEX

NM

AGE

5

INTERPRETED BY

Nele Eley, DVM
Dr. med. Vet. DipECVDI

HOSPITAL NAME

Elizabeth Animal
Hospital

REFERRING VET

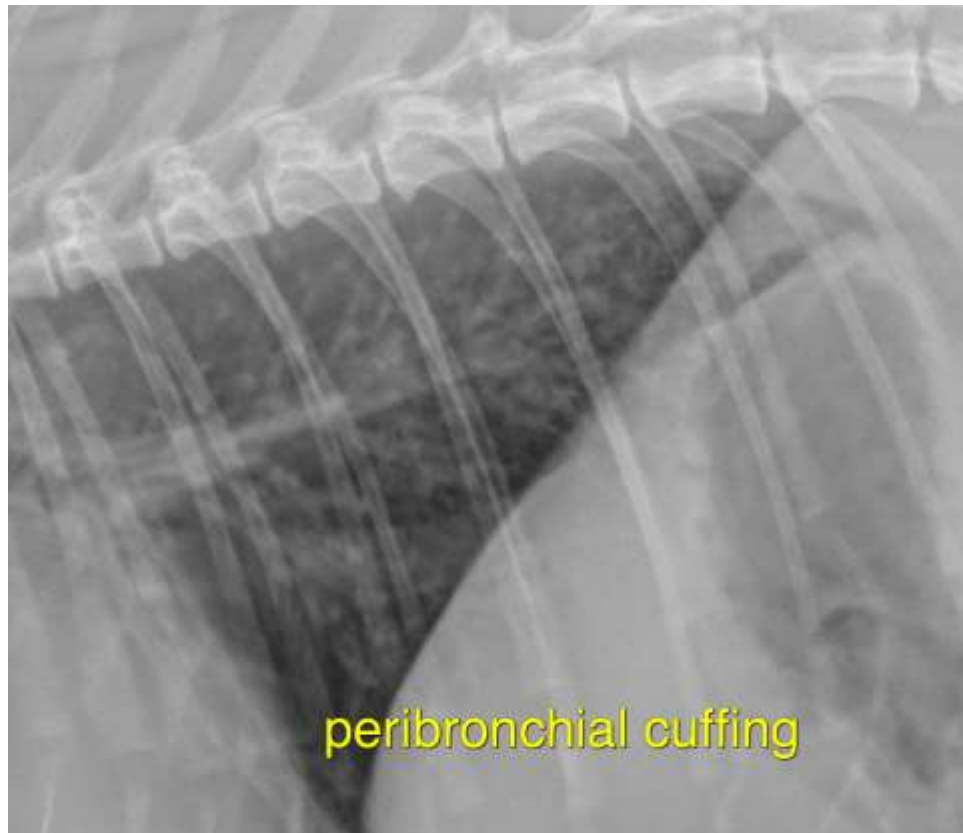
Carlos Fuentes, DVM/
Leon Anderson, DVM

INVOICE

49452

DATE

1-10-22



The information and recommendations provided are based on the images presented by the referring veterinarian. No evaluation can be communicated regarding pathology that was not visible in the image/video clips provided.

Thank you for this referral. If the clinical or image interpretation does not parallel your findings or if I can be of any further assistance please contact me.

Nele Eley, DVM, Dr. med. vet., DipECVDI
European Specialist in Veterinary Diagnostic Imaging, Cert. Radiology,
Senior lecturer University of Giessen, Germany, Veterinary Faculty, Department of Radiology
Nele.Eley@sonopath.com