



PATIENT

Lola Tureck

SPECIES

Canine

BREED

Cockapoo

SEX

FS

AGE

3yr

WEIGHT

7.3kg

INTERPRETED BY

R. McKenzie Daniel,
DVM, DABVP
(Canine and Feline)

IMAGING PERFORMED BY

Dr Belan

HOSPITAL NAME

Glamorgan Animal
Clinic

REFERRING VET

Dr Hill

INVOICE

14591ag

DATE

08/11/2023

PRESENTING CLINICAL SIGNS

Was sent to the neurologist to peruse a seizure episode. Follow up to eliminate vascular hepato portal disease

Abnormal PE/Chem/CBC/UA Results: Chemistry unremarkable Bile Acids Preprandial 16.3 (range 0-14) Post prandial 30 (range 0-29)

ULTRASONOGRAPHIC EXAMINATION OF THE ABDOMEN

Urinary System

The urinary bladder, trigone, cystourethral junction, and visible pelvic urethra to a depth of 3 cm exhibited normal thickness and tone. Anechoic urine was present in the lumen with no uroliths, mineral or sediment. The ureteral papillae were normal. The ureters were not visible which is normal. No evidence of inflammatory or neoplastic changes were noted.

Normal size and margination were present in the kidneys. A normal 1:3 cortex / medulla ratio and normal corticomedullary definition were maintained. The echogenicity of the cortex was similar to or slightly less than normal liver parenchyma while the medulla echogenicity was hypoechoic to the cortex with no evidence of pelvic dilation. The left kidney measured 3.9 cm in length. The right kidney measured 4.1 cm in length.

The area of the aortic trifurcation was free of pathology.

Adrenal Glands

The left adrenal gland was uniform in size and contour with a uniformly hypoechoic parenchyma. The left adrenal gland measured 0.35 cm width at the caudal pole and 0.41 cm width at the cranial pole. The right adrenal gland was uniform in size and contour with a uniformly hypoechoic parenchyma. The right adrenal gland measured 0.39 cm width at the caudal pole.

Spleen

The spleen exhibited a finely textured and homogenous parenchyma which was hyperechoic to the liver and renal cortical parenchyma. The capsule was smooth and regular without apparent expansion. The splenic vasculature at the hilus was normal in volume with no evidence of congestion or thrombosis. Acute to chronic inflammatory, neoplastic, or benign parenchyma changes were not noted.

Liver/Gallbladder

The liver was subjectively normal in size, structure, and contour. The liver parenchyma was uniform and hypoechoic to the spleen with a mild coarse echotexture. Normal vascular volume. The hepatic and portal vasculature were normal in appearance without signs of congestion. Subjective ~ 1:1 portal vein to caudal vena cava ratio. The gallbladder was non-distended in size with thin walls and primarily anechoic luminal content. The cystic and common bile ducts were normal.

Gastrointestinal

The stomach presented intact wall layering with a normal wall layer ratio. The lumen of the stomach was empty with no signs of ileus, obstruction or foreign material.



PATIENT

Lola Tureck

The small intestine presented intact wall layering with 1:3 muscularis/mucosa ratio. The lumen of the small intestine was empty with no signs of ileus, obstruction or foreign material.

Normal visible colon wall layers were present with apparent formed feces in lumen.

SPECIES

Canine

Pancreas

The parenchyma of the left limb, body and right limb of the pancreas presented isoechoic to the adjacent omental fat. A normal curvilinear capsule contour of the pancreas was present. The visible pancreatic duct was normal. No signs of active inflammation or neoplastic disease was evident.

BREED

Cockapoo

Free Abdomen

No omental masses, overt lymphadenopathy or peritoneal effusion was present.

SEX

FS

ULTRASONOGRAPHIC FINDINGS

- Normal volume liver.
- Normal bilateral kidneys/urinary bladder-no evidence of renal or cystic mineral/calculi.

AGE

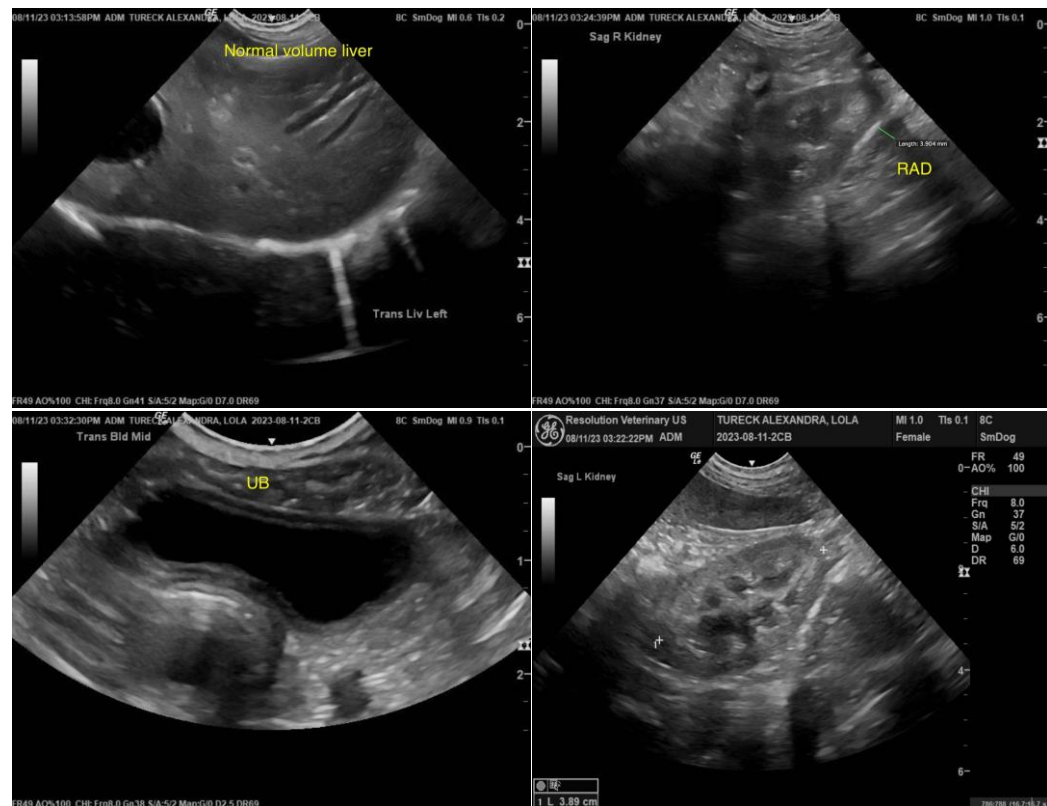
3yr

INTERPRETATION OF THE FINDINGS & FURTHER RECOMMENDATIONS

No evidence of intrahepatic or extrahepatic macroscopic shunt was visualized.

WEIGHT

7.3kg



INTERPRETED BY

R. McKenzie Daniel,
DVM, DABVP
(Canine and Feline)

IMAGING PERFORMED BY

Dr Belan

HOSPITAL NAME

Glamorgan Animal
Clinic

REFERRING VET

Dr Hill

INVOICE

14591ag

DATE

08/11/2023



PATIENT

Lola Tureck

SPECIES

Canine

BREED

Cockapoo

SEX

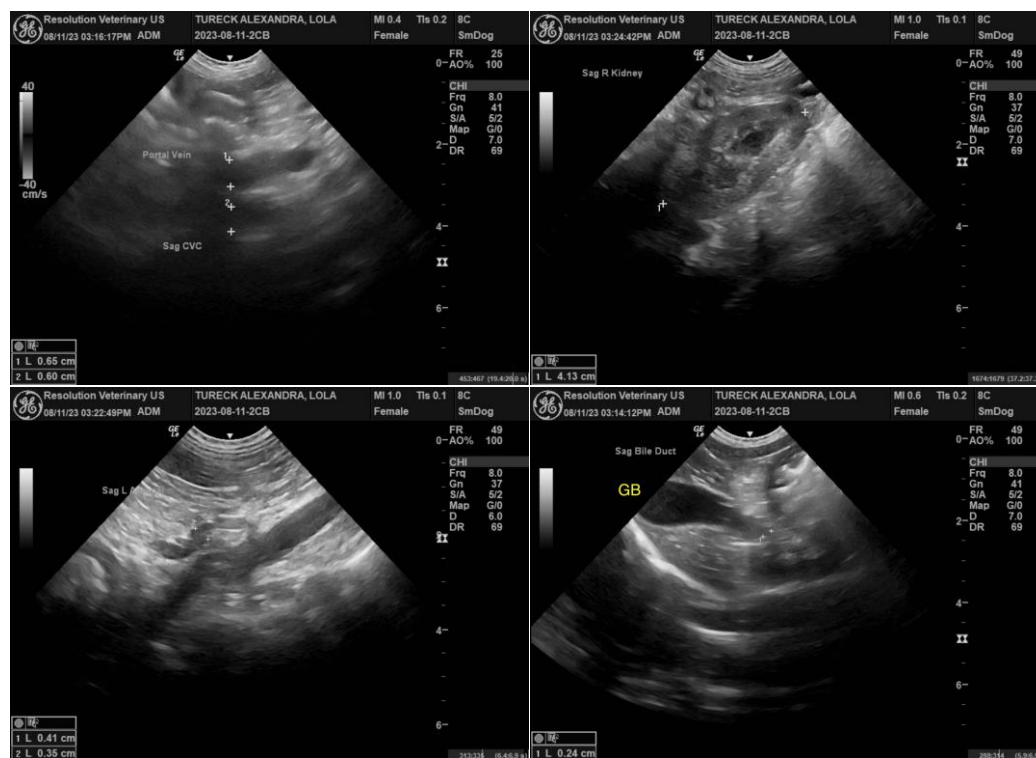
FS

AGE

3yr

WEIGHT

7.3kg



The information and recommendations provided are based on the images presented by the referring veterinarian/sonographer. No evaluation can be communicated regarding pathology that was not visible in the image/video clips provided.

INTERPRETED BY

R. McKenzie Daniel,
DVM, DABVP
(Canine and Feline)

Thank you for this referral. If the clinical or image interpretation does not parallel your findings or if I can be of any further assistance, please contact me.

IMAGING PERFORMED BY

Dr Belan

R. McKenzie Daniel, DVM, DABVP (Canine/Feline Practice)
info@sonopath.com

HOSPITAL NAME

Glamorgan Animal
Clinic

REFERRING VET

Dr Hill

INVOICE

14591ag

DATE

08/11/2023