

**PATIENT**

Winston Smith

SPECIES

Canine

BREED

Lab

SEX

MN

AGE

2yr

WEIGHT

71.4lb

INTERPRETED BYR. McKenzie Daniel,
DVM, DABVP
(Canine and Feline)**IMAGING
PERFORMED BY**

Amy Mayhew LVT

HOSPITAL NAMESVS Imaging
Michigan**REFERRING VET**Rochester
Veterinary Hospital**INVOICE**

11585ag

DATE

09/09/2022

PRESENTING CLINICAL SIGNS

No clinical signs

Abnormal PE/Chem/CBC/UA Results: Palpated today, suspicious for inguinal hernia

ULTRASONOGRAPHIC EXAMINATION OF THE ABDOMEN**Urinary System**

The urinary bladder, trigone, cystourethral junction, and visible pelvic urethra to a depth of 5 cm exhibited normal thickness and tone. Anechoic urine was present in the lumen with no uroliths or sediment. The ureteral papillae were normal. The ureters were not visible which is normal. No evidence of inflammatory or neoplastic changes were noted.

Normal size and margination were present in the kidneys. A normal 1:3 cortex / medulla ratio and normal corticomedullary definition were maintained. The echogenicity of the cortex was similar to or slightly less than normal liver parenchyma while the medulla echogenicity was hypoechoic to the cortex with no evidence of pelvic dilation. The left kidney measured 6.5 cm in length. The right kidney measured 6.5 cm in length.

The area of the aortic trifurcation was free of pathology.

The residual prostate was free of pathology.

A focal, mildly prominent to enlarged iliac node was present. The lymph node was essentially isoechoic to adjacent omentum without evidence of peripheral inflammation and maintaining a normal width: length ratio (<0.5). Not consistent with inflammatory or neoplastic criteria measuring 0.86 cm in width.

Adrenal Glands

The left adrenal gland was uniform in size and contour with a uniformly hypoechoic parenchyma. The left adrenal gland measured 0.52 cm width at the caudal pole and 0.48 cm width at the cranial pole. The right adrenal gland was uniform in size and contour with a uniformly hypoechoic parenchyma. The right adrenal gland measured 0.46 cm width at the caudal pole.

Spleen

The spleen exhibited a finely textured and homogenous parenchyma which was hyperechoic to the liver and renal cortical parenchyma. The capsule was smooth and regular without apparent expansion. The splenic vasculature at the hilus was normal in volume with no evidence of congestion or thrombosis. Acute to chronic inflammatory, neoplastic, or benign parenchyma changes were not noted.

Liver

The liver was subjectively normal in size, structure, and contour. The liver parenchyma was uniform and hypoechoic to the spleen with a mild coarse echotexture. The hepatic and portal vasculature were normal in appearance without signs of congestion. The gallbladder was non-distended in size with thin walls and primarily anechoic luminal content. The cystic and common bile ducts were normal.

Gastrointestinal

The stomach presented intact wall layering with a normal wall layer ratio. The lumen of the stomach was empty with no signs of ileus, obstruction or foreign material.

The small intestine presented intact wall layering with 1:3 muscularis/mucosa ratio. The lumen of the small intestine was empty with no signs of ileus, obstruction or foreign material.



PATIENT

Normal visible colon wall layers were present with apparent formed feces in lumen.

Winston Smith

Pancreas

The parenchyma of the left limb, body and right limb of the pancreas presented isoechoic to the adjacent omental fat. A normal curvilinear capsule contour of the pancreas was present. The visible pancreatic duct was normal. No signs of active inflammation or neoplastic disease was evident.

SPECIES

Canine

Free Abdomen

No overt lymphadenopathy or peritoneal effusion was present.

BREED

Lab

Sonographic assessment in the area of the potential inguinal hernia revealed fat echogenicity without evidence of visualized intestinal segments, free fluid or other pathology. The deep inguinal body wall appeared to be subjectively intact.

SEX

MN

ULTRASONOGRAPHIC FINDINGS

- Sonographically unremarkable abdomen
- Suspect inguinal lipoma

AGE

2yr

INTERPRETATION OF THE FINDINGS & FURTHER RECOMMENDATIONS

Minor potential for inguinal hernia with only mesenteric fat present cannot be definitively excluded given indistinct visualized of the inguinal body wall although considered less likely. Correlation with pending cytology is suggested. Monitoring of the suspected inguinal lipoma for evidence of progression would be reasonable.

WEIGHT

71.4lb

INTERPRETED BY

R. McKenzie Daniel,
DVM, DABVP
(Canine and Feline)

IMAGING PERFORMED BY

Amy Mayhew LVT

HOSPITAL NAME

SVS Imaging
Michigan

REFERRING VET

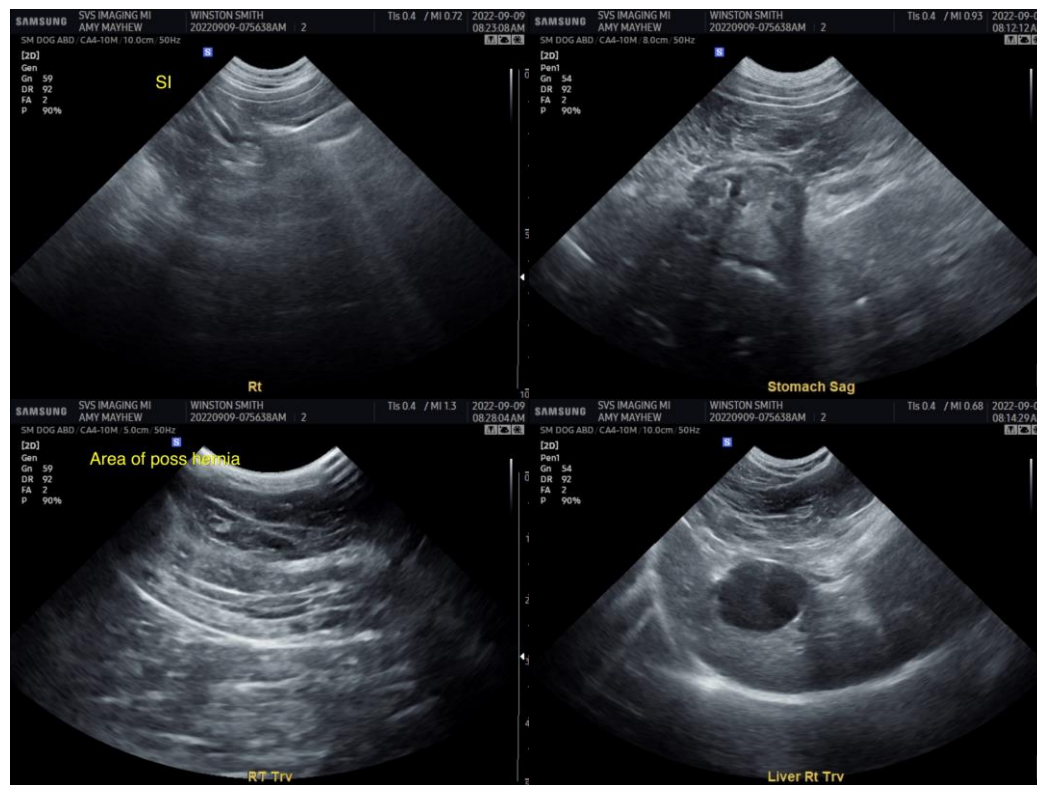
Rochester
Veterinary Hospital

INVOICE

11585ag

DATE

09/09/2022



IMAGING PERFORMED BY

SVS Mobile Imaging MI 734-637-7711
svsimagingmi@gmail.com



PATIENT

Winston Smith

SPECIES

Canine

BREED

Lab

SEX

MN

AGE

2yr

WEIGHT

71.4lb

INTERPRETED BY

R. McKenzie Daniel,
DVM, DABVP
(Canine and Feline)

IMAGING PERFORMED BY

Amy Mayhew LVT

HOSPITAL NAME

SVS Imaging
Michigan

REFERRING VET

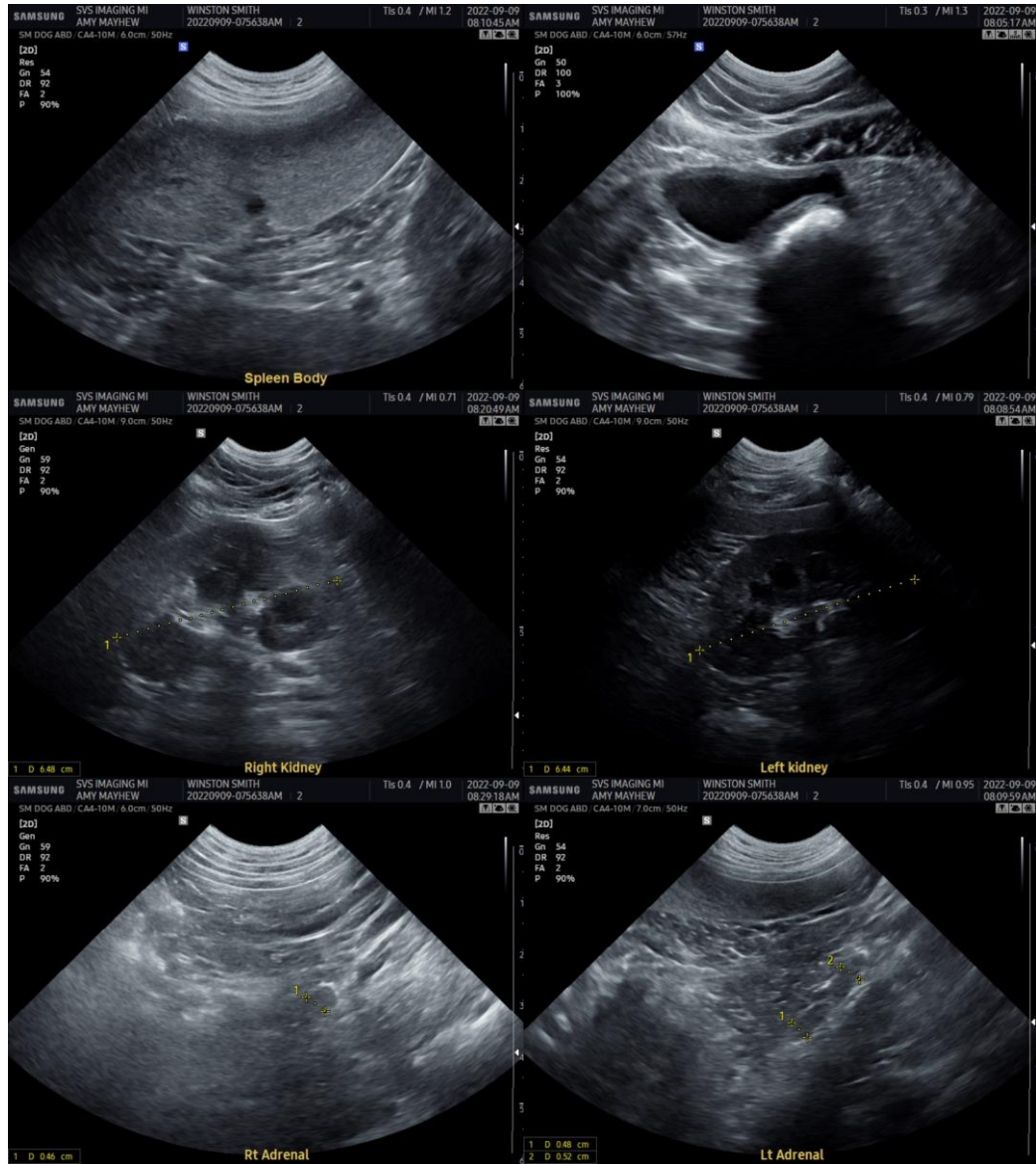
Rochester
Veterinary Hospital

INVOICE

11585ag

DATE

09/09/2022



The information and recommendations provided are based on the images presented by the referring veterinarian/sonographer. No evaluation can be communicated regarding pathology that was not visible in the image/video clips provided.

Thank you for this referral. If the clinical or image interpretation does not parallel your findings or if I can be of any further assistance please contact me.

R. McKenzie Daniel, DVM, DABVP (Canine / Feline Practice)

info@SonoPath.com