


PATIENT

Snowy Bernard

PRESENTING CLINICAL SIGNS

3/6 murmur, coughing when excited. BP 128. r/o CHF vs collapsing trachea. not on any meds.

Abnormal PE/Chem/CBC/UA Results: pending

SPECIES

Canine

ULTRASONOGRAPHIC EXAMINATION OF THE HEART
BREED

Maltese Mix

CANINE CARDIAC PARAMETERS	MR VMAX (m/s)	TR VMAX (m/s)	LA/AO (Boon method)	LA/AO (Heart Base; Swe)	FS (%)	EF (%)	EPSS (cm)
NORMAL PARAMETER	4.5-5.5	<2.7	1.3	<1.3	28-40	40-100	<0.6
PATIENT	5.8		1.4	1.3	38.5	71.3	0.18
CANINE CARDIAC PARAMETERS	HR (BPM)	AV VMAX (m/s)	PV MAX (m/s)	BODY WEIGHT (kg)	LA 2D short axis Base view (cm)	LVIDd Avg; 2D and m-mode short axis (cm)	LVIDs Avg; 2D and m-mode short axis (cm)
NORMAL PARAMETER	50-100	0.7-1.7	0.7-1.6				
PATIENT	221	1.2	1.0		2.4	2.3	

SEX

FS

AGE

9yr

WEIGHT

10.1lb

Cardiac Presentation

The echocardiogram in this patient demonstrated normal left atrial size based on 3 different LA measurement methods. Chamber volumes and echogenicity were normal. The cranial and caudal mitral valve leaflets presented vegetative thickening consistent with endocardiosis. Doppler indicated measurable insufficiency. The left ventricle presented thicknesses with linear contour and was not dilated nor restricted. The myocardium presented normal echogenicity without subjective evidence of significant fibrotic or ischemic disease. Contractility of the ventricular walls was adequate and in normal range for this patient evidenced by the fractional shortening measurement and subjective evaluation of the different regions of the myocardium. The left ventricular outflow tract demonstrated normal laminar flow and subjective structural integrity. The right atrium and auricle revealed normal size, structure and content. No evidence of masses was noted or chamber overload. Tricuspid valvular assessment demonstrated adequate linear morphology. No TR present on Doppler. The right ventricle was of normal size (1/3 diameter of LV), chordae structure, myocardial echogenicity and thickness. Pulmonic tract assessment revealed normal valve structure, laminar flow, and diameter (approx. 1:1 pa/ao ratio). No visible pericardial or free pleura fluid was noted. No echographically detectable evidence of infiltrative disease was visible. The cranial mediastinum and pericardial regions were free of masses in the visible window.

INTERPRETED BY

 R. McKenzie Daniel,
 DVM, DABVP
 (Canine and Feline)

IMAGING PERFORMED BY

Diane McFadden

HOSPITAL NAME

 Parsippany Troy Hills
 AH

REFERRING VET

Dr. Dulude

ULTRASONOGRAPHIC FINDINGS
Primary

- Chronic mitral valve disease (ACVIM B1)

INVOICE

11582ag

DATE

09/09/2022



PATIENT

Snowy Bernard

INTERPRETATION OF THE FINDINGS & FURTHER RECOMMENDATIONS

SPECIES

Canine

The cause of the murmur is chronic degenerative valvular changes with secondary eccentric mitral valve insufficiency. The lack of left atrial enlargement implies that the risk of complication secondary to mitral valve insufficiency is low at this time and, without current clinical signs, indicates that medical therapy is not required. No overt evidence of a cardiogenic component to the patient's cough. Primary upper or lower airway disease is likely.

BREED

Maltese Mix

Serial sonographic monitoring is recommended with a recheck echocardiogram in 6-12 months, sooner if clinical signs suggestive of heart disease develop.

SEX

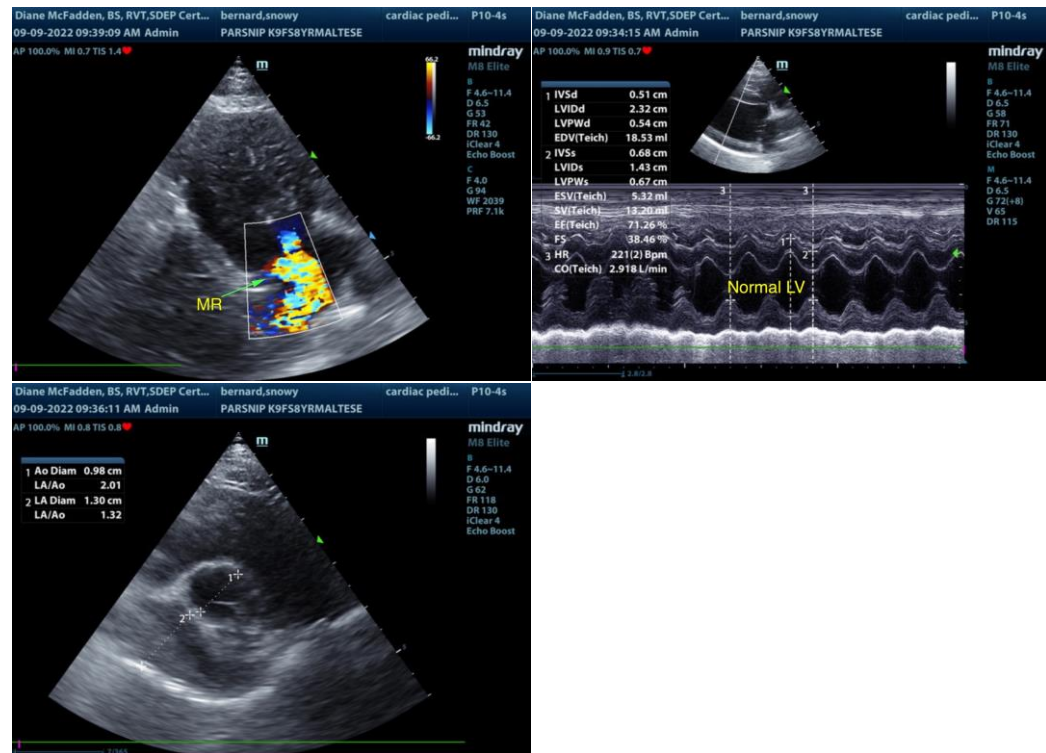
FS

AGE

9yr

WEIGHT

10.1lb



INTERPRETED BY

R. McKenzie Daniel,
DVM, DABVP
(Canine and Feline)

IMAGING PERFORMED BY

Diane McFadden

HOSPITAL NAME

Parsippany Troy Hills
AH

REFERRING VET

Dr. Dulude

The information and recommendations provided are based on the images presented by the referring veterinarian/sonographer. No evaluation can be communicated regarding pathology that was not visible in the image/video clips provided.

Thank you for this referral. If the clinical or image interpretation does not parallel your findings or if I can be of any further assistance please contact me.

R. McKenzie Daniel, DVM, DABVP (Canine / Feline Practice)

info@SonoPath.com

INVOICE

11582ag

DATE

09/09/2022