

**PATIENT**

Sasha Riggins

**PRESENTING CLINICAL SIGNS**

anal tumor

**SPECIES**

Canine

Abnormal PE/Chem/CBC/UA Results: ISU cytology report Interpretation: apocrine gland adenocarcinoma of the anal sac possible enlarged sub lumbar lymph nodes on rads

**ULTRASONOGRAPHIC EXAMINATION OF THE ABDOMEN****BREED**

Lab

**Urinary System**

The urinary bladder, trigone, cystourethral junction, and visible pelvic urethra to a depth of 2 cm exhibited normal thickness and tone. Anechoic urine was present in the lumen with no uroliths or sediment. The ureteral papillae were normal. The ureters were not visible which is normal. No evidence of inflammatory or neoplastic changes were noted.

**SEX**

FS

Normal size and margination was present in the kidneys. A normal 1:3 cortex / medulla ratio was maintained. The medulla and cortices were uniform in texture with some increased echogenicity and mild loss of corticomedullary symmetry and definition expected for the age of the patient. No evidence of pelvic dilation was present. Bilateral pinpoint medullary mineral was present. The left kidney measured 7.4 cm in length. The right kidney measured 7.6 cm in length.

**AGE**

9yr

The area of the aortic trifurcation was free of pathology.

**WEIGHT**

64lb

No evidence of masses in the sublumbar space dorsal to the urinary bladder.

**Adrenal Glands**

The left adrenal gland was normal in size. Mild parenchyma heterogeneity and mild capsule asymmetry was present without suspicion for overt neoplasia. The left adrenal gland measured 3.0 cm length and 0.60 cm width in the caudal pole.

**INTERPRETED BY**

R. McKenzie Daniel,  
DVM, DABVP  
(Canine and Feline)

A well-defined, hyperechoic nodule was present in the cranial pole of the right adrenal gland with mild associated symmetrical capsule expansion. The nodule did not exhibit signs of mineralization or vascular invasion. The nodule measured 1.3 cm x 1.1 cm. The right adrenal gland measured 0.62 cm width at the caudal pole and 1.17 cm width at the cranial pole.

**IMAGING PERFORMED BY**

Sarah Pender CVT

**Spleen**

A mass involving the spleen with secondary capsule expansion and disruption was present and measured 7.3 cm in diameter. The parenchyma of the mass was heterogeneous to mixed echogenic without areas of cavitation. The non-affected spleen exhibited primarily finely textured and homogenous parenchyma which was hyperechoic to the liver and renal cortical parenchyma. The splenic vasculature at the hilus was normal in volume with no evidence of congestion or thrombosis.

**HOSPITAL NAME**

SVS Imaging CT

**REFERRING VET**

Dr. Schermer

**Liver**

The liver was subjectively normal in size, structure, and contour. The liver parenchyma was uniform and hypoechoic to the spleen with a mild coarse echotexture. The hepatic and portal vasculature were normal in appearance without signs of congestion. The gallbladder was non-distended in size with thin walls and primarily anechoic luminal content with very minor luminal debris. The cystic and common bile ducts were normal.

**INVOICE**

11596ag

**Gastrointestinal****DATE**

09/09/2022

The stomach presented intact wall layering with a normal wall layer ratio. The lumen of the stomach was empty with no signs of ileus, obstruction or foreign material.

**PATIENT**

Sasha Riggins

The small intestine presented intact wall layering with 1:3 muscularis/mucosa ratio. The lumen of the small intestine was empty with no signs of ileus, obstruction or foreign material.

Normal visible colon wall layers were present with apparent formed feces in lumen.

**SPECIES*****Pancreas***

Canine

The parenchyma of the left limb, body and right limb of the pancreas presented isoechoic to the adjacent omental fat. A normal curvilinear capsule contour of the pancreas was present. The visible pancreatic duct was normal. No signs of active inflammation or neoplastic disease was evident.

**BREED**

Lab

***Free Abdomen***

No omental masses or peritoneal effusion was present.

**SEX**

FS

Focal, mildly prominent to enlarged medial iliac lymph nodes were present adjacent to the iliac trifurcation. The lymph nodes were essentially isoechoic to adjacent omentum without evidence of peripheral inflammation and maintaining a normal width: length ratio (<0.5). The lymph node measured 2.4 cm x 1.1 cm.

**AGE**

9yr

Rapid view of the heart revealed no evidence of pericardial masses or effusion in the visible window.

**ULTRASONOGRAPHIC FINDINGS**

- Mild medial iliac lymphadenopathy without evidence of perilymphatic inflammation
- Cranial splenic mass
- Non-specific right adrenal nodule

**WEIGHT**

64lb

**Secondary finding**

- Mild chronic renal changes

**INTERPRETED BY**

R. McKenzie Daniel,  
DVM, DABVP  
(Canine and Feline)

**INTERPRETATION OF THE FINDINGS & FURTHER RECOMMENDATIONS**

The medial iliac lymphadenopathy was non-specific with considerations including incidental hyperplasia, minor reactive lymphadenitis with the possibility of emerging neoplastic lymphadenopathy is of concern. Accessibility of these lymph nodes for FNA may be precluded. Sonographic monitoring of the lymph nodes with potential future FNA for cytology is suggested.

The splenic mass is nonspecific with considerations including hyperplasia, hematopoiesis, granuloma, splenitis, or neoplasia (sarcoma, round cell neoplasia, other). Assuming normal clotting status and using a 25g needle a splenic mass FNA is recommended for screening cytology.

Right adrenal nodule-functional vs non-functional adenoma, benign hyperplasia, granuloma or emerging neoplasia such as pheochromocytoma, adenocarcinoma or other is possible.

Screening BP to assess for evidence of hypertension which may allude to a right adrenal pheochromocytoma is recommended. Sonographic monitoring of the nodule for evidence of progression with initial recheck in 4-6 weeks would be ideal.

**IMAGING PERFORMED BY**

Sarah Pender CVT

**HOSPITAL NAME**

SVS Imaging CT

**REFERRING VET**


Dr. Schermer

**INVOICE**

11596ag

**DATE**

09/09/2022



PATIENT

Sasha Riggins

SPECIES

Canine

BREED

Lab

SEX

FS

AGE

9yr

WEIGHT

64lb

INTERPRETED BY

R. McKenzie Daniel, DVM, DABVP (Canine and Feline)

IMAGING PERFORMED BY

Sarah Pender CVT

HOSPITAL NAME

SVS Imaging CT

REFERRING VET

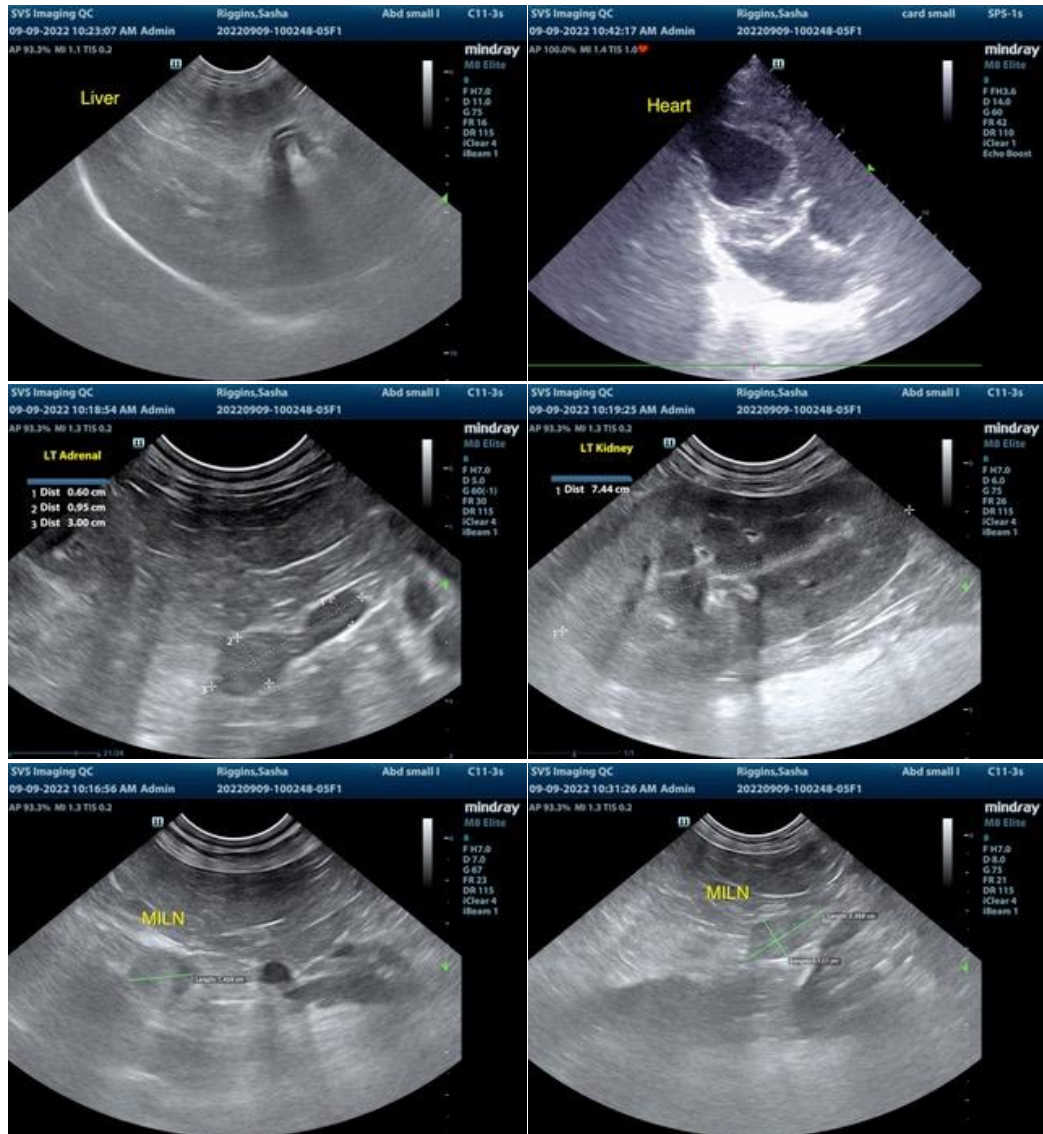
Dr. Schermer

INVOICE

11596ag

DATE

09/09/2022





**PATIENT**

Sasha Riggins

**SPECIES**

Canine

**BREED**

Lab

**SEX**

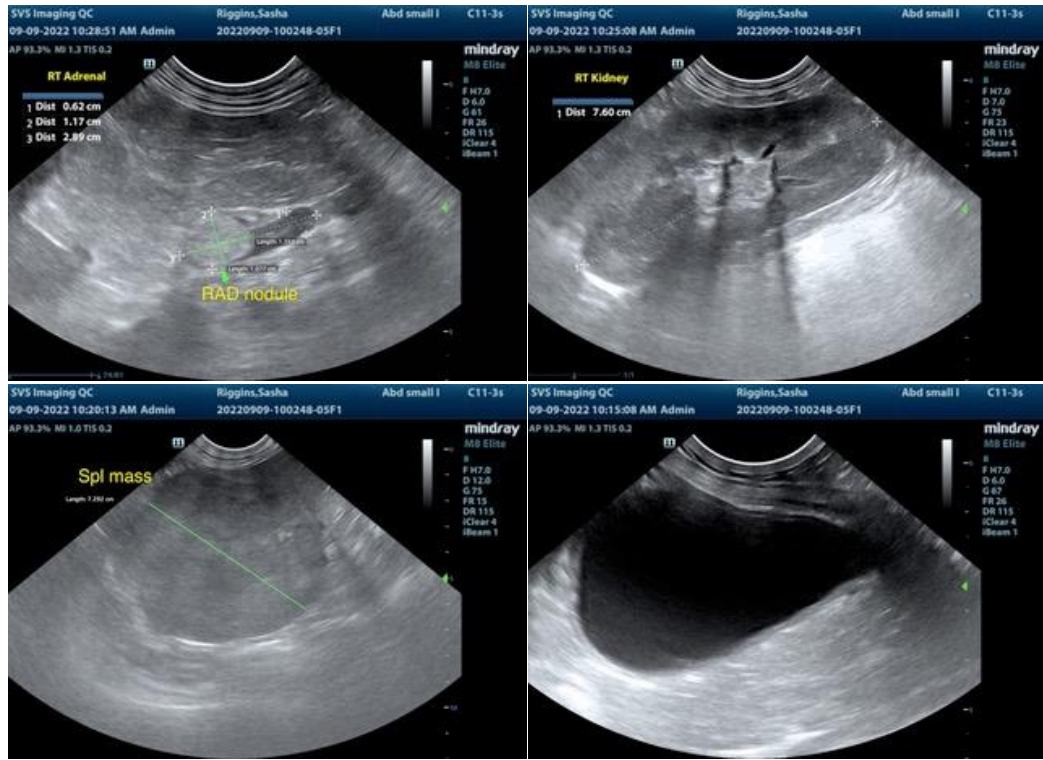
FS

**AGE**

9yr

**WEIGHT**

64lb



The information and recommendations provided are based on the images presented by the referring veterinarian/sonographer. No evaluation can be communicated regarding pathology that was not visible in the image/video clips provided.

**INTERPRETED BY**

R. McKenzie Daniel,  
DVM, DABVP  
(Canine and Feline)

Thank you for this referral. If the clinical or image interpretation does not parallel your findings or if I can be of any further assistance please contact me.

R. McKenzie Daniel, DVM, DABVP (Canine / Feline Practice)

info@SonoPath.com

**IMAGING PERFORMED BY**

Sarah Pender CVT

**HOSPITAL NAME**

SVS Imaging CT

**REFERRING VET**

Dr. Schermer

**INVOICE**

11596ag

**DATE**

09/09/2022