



PATIENT PRESENTING CLINICAL SIGNS

Nova Meier S/P laparotomy (2020) - Removed wooden skewer. Now presents with very firm swelling at area of laparotomy. Foaming at the mouth after short walks, increased drinking. Radiographs show opacity along midline adjacent to midline laparotomy incision. ? Scar tissue.
SPECIES Abnormal PE/Chem/CBC/UA Results:

Canine
ULTRASONOGRAPHIC EXAMINATION OF THE ABDOMEN

BREED *Urinary System*

Spaniel Mix The urinary bladder, trigone, cystourethral junction, and visible pelvic urethra exhibited normal thickness and tone. Anechoic urine was present in the lumen with no uroliths or sediment. The ureteral papillae were normal. The ureters were not visible which is normal. No evidence of inflammatory or neoplastic changes were noted.

SEX

FS

Normal size and margination was present in the kidneys. A normal 1:3 cortex / medulla ratio and normal corticomedullary definition were maintained. The echogenicity of the cortex was similar to or slightly less than normal liver parenchyma while the medulla echogenicity was hypoechoic to the cortex. Very scant likely incidental bilateral pyelectasia was present. The left kidney measured 7.9 cm in length. The right kidney measured 7.7 cm in length.

AGE

4.5yr

The area of the aortic trifurcation was free of pathology.

WEIGHT

67.4lb

A solitary mildly prominent to enlarged medial iliac node was present. The lymph node was essentially isoechoic to adjacent omentum without evidence of peripheral inflammation and maintaining a normal width: length ratio (<0.5). The lymph node measured 1.9 x 0.51 cm.

Adrenal Glands

The left adrenal gland was uniform in size and contour with a uniformly hypoechoic parenchyma. The left adrenal gland measured 0.48 cm width at the caudal pole and 0.38 cm width at the cranial pole. The right adrenal gland was uniform in size and contour with a uniformly hypoechoic parenchyma. The right adrenal gland measured 0.52 cm width at the caudal pole and 0.48 cm width at the cranial pole.

INTERPRETED BY

R. McKenzie Daniel, DVM, DABVP (Canine and Feline)

IMAGING PERFORMED BY

Pamela Harrigan, RDCS

HOSPITAL NAME

Rhode Island Animal Medical Center

REFERRING VET

Dr. White

Spleen

The spleen exhibited a finely textured and homogenous parenchyma which was hyperechoic to the liver and renal cortical parenchyma. The capsule was smooth and regular without apparent expansion. The splenic vasculature at the hilus was normal in volume with no evidence of congestion or thrombosis. Acute to chronic inflammatory, neoplastic, or benign parenchyma changes were not noted.

Liver

The liver was subjectively normal in size, structure, and contour. The liver parenchyma was uniform and hypoechoic to the spleen with a mild coarse echotexture. The hepatic and portal vasculature were normal in appearance without signs of congestion. The gallbladder was non-distended in size with thin walls and primarily anechoic luminal content. The cystic and common bile ducts were normal.

INVOICE

11598ag

Gastrointestinal

The stomach presented intact wall layering with a normal wall layer ratio. The lumen of the stomach was primarily empty with no signs of ileus, obstruction or foreign material.

DATE

09/09/2022

The small intestine presented intact wall layering with 1:3 muscularis/mucosa ratio. The lumen of the small intestine was empty with no signs of ileus, obstruction or foreign material. The duodenum wall measured 0.51 cm in width. The jejunum wall measured 0.47 cm in width.



PATIENT

Normal visible colon wall layers were present with apparent formed feces in lumen.

Nova Meier

Pancreas

SPECIES

The parenchyma of the left limb, body and right limb of the pancreas presented isoechoic to the adjacent omental fat. A normal curvilinear capsule contour of the pancreas was present. The visible pancreatic duct was normal. No signs of active inflammation or neoplastic disease was evident.

Canine

Free Abdomen

BREED

No omental masses were present.

Spaniel Mix

The intra-abdominal omentum exhibited overall normal echogenicity; no evidence of peritonitis was observed. Intermittent small pocket of peritoneal free fluid was noted, potentially a physiologic finding assuming normal ALB levels.

SEX

A moderately sized ventral midline lesion/swelling containing non-specific mixed echogenic tissue was present measuring ~ 8-9 cm. No evidence of fluid cavitation or abscess within the swelling. The swelling/lesion appeared to extend to the level of the body wall without overt connection to the intra-abdominal cavity.

FS

AGE

4.5yr

ULTRASONOGRAPHIC FINDINGS

- Ventral midline swelling/lesion containing mixed echogenic tissue
- Otherwise sonographically unremarkable GI tract
- Intermittent small pocket of scant free fluid

WEIGHT

67.4lb

INTERPRETATION OF THE FINDINGS & FURTHER RECOMMENDATIONS

INTERPRETED BY

The ventral midline swelling/lesion was non-specific with considerations including mixed echogenic scar tissue/fibrosis or potential for non-obvious inguinal hernia with entrapped mesenteric fat. No evidence of intestinal segments within the ventral midline swelling, no evidence of GI ileus. Neoplastic criteria for the ventral midline swelling/lesion is considered less likely.

R. McKenzie Daniel, DVM,
 DABVP (Canine and Feline)

IMAGING PERFORMED BY

Correlation with pending FNA cytology recommended. Incisional exploration of the swelling to the level of the body wall with potential for biopsies +/- C/S if clinically indicated could be considered.

Pamela Harrigan, RDCS

HOSPITAL NAME

Rhode Island Animal
 Medical Center

REFERRING VET

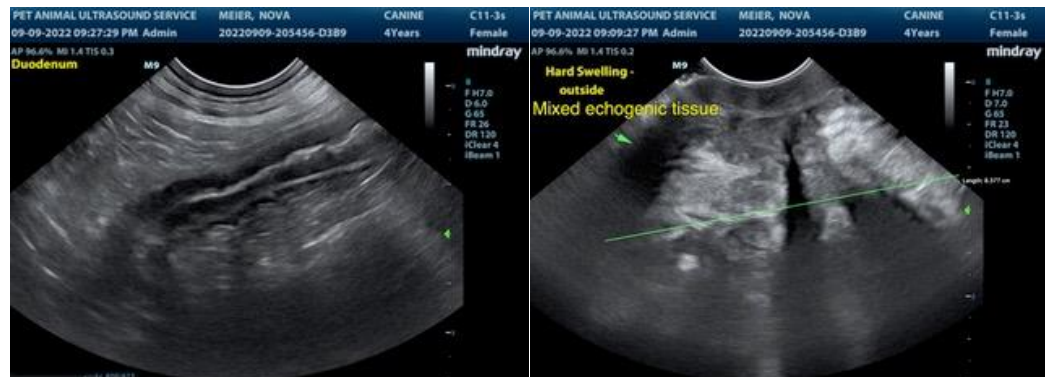
Dr. White

INVOICE

11598ag

DATE

09/09/2022





PATIENT

Nova Meier

SPECIES

Canine

BREED

Spaniel Mix

SEX

FS

AGE

4.5yr

WEIGHT

67.4lb

INTERPRETED BY

R. McKenzie Daniel, DVM,
 DABVP (Canine and Feline)

IMAGING PERFORMED BY

Pamela Harrigan, RDCS

HOSPITAL NAME

Rhode Island Animal
 Medical Center

REFERRING VET

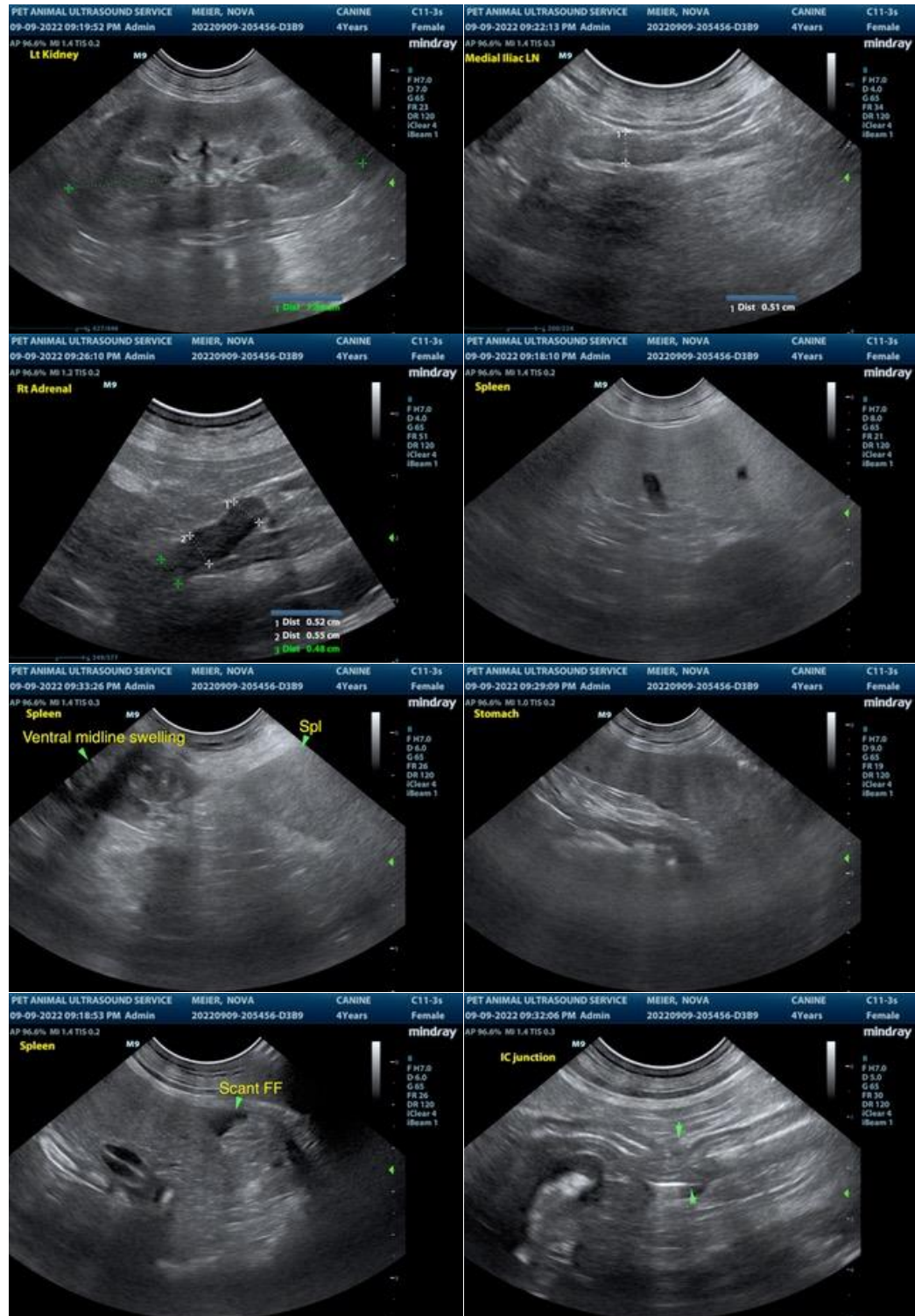
Dr. White

INVOICE

11598ag

DATE

09/09/2022





PATIENT

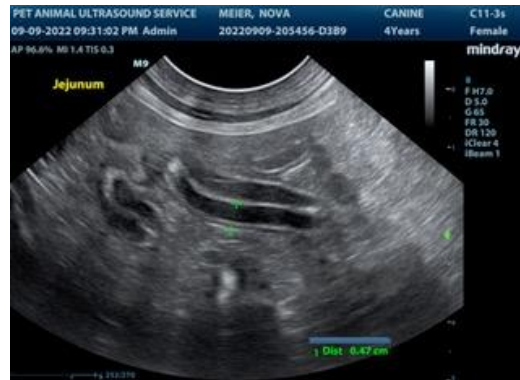Nova Meier

SPECIES

Canine

BREED

Spaniel Mix



SEX

FS

AGE

4.5yr

WEIGHT

67.4lb

INTERPRETED BY

R. McKenzie Daniel, DVM,
DABVP (Canine and Feline)

**IMAGING
PERFORMED BY**

Pamela Harrigan, RDCS

HOSPITAL NAME

Rhode Island Animal
Medical Center

REFERRING VET

Dr. White

INVOICE

11598ag

DATE

09/09/2022

The information and recommendations provided are based on the images presented by the referring veterinarian. No evaluation can be communicated regarding pathology that was not visible in the image/video clips provided.

Thank you for this referral. If the clinical or image interpretation does not parallel your findings or if I can be of any further assistance please contact me.

R. McKenzie Daniel, DVM, DABVP (Canine / Feline Practice)
info@SonoPath.com