


PATIENT

Bella Oscamoa

PRESENTING CLINICAL SIGNS

pre-anesthetic echo prior to dental; please comment on anesthesia to use. currently on no meds

SPECIES

Canine

ULTRASONOGRAPHIC EXAMINATION OF THE HEART
BREED

Chihuahua

SEX

FS

AGE

13yr

WEIGHT

6.2lb

CANINE CARDIAC PARAMETERS	MR VMAX (m/s)	TR VMAX (m/s)	LA/AO (Boon method)	LA/AO (Heart Base; Swe)	FS (%)	EF (%)	EPSS (cm)
NORMAL PARAMETER	4.5-5.5	<2.7	1.3	<1.3	28-40	40-100	<0.6
PATIENT	6.5			1.45	37.5	71	0.1
CANINE CARDIAC PARAMETERS	HR (BPM)	AV VMAX (m/s)	PV MAX (m/s)	BODY WEIGHT (kg)	LA 2D short axis Base view (cm)	LVIDd Avg; 2D and m-mode short axis (cm)	LVIDs Avg; 2D and m-mode short axis (cm)
NORMAL PARAMETER	50-100	0.7-1.7	0.7-1.6				
PATIENT	133	1.4	0.8		2.4	2.4	

Cardiac Presentation

The echocardiogram in this patient demonstrated normal left atrial size based on 3 different LA measurement methods. Chamber volumes and echogenicity were normal. The cranial and caudal mitral valve leaflets presented vegetative thickening consistent with endocardiosis. Doppler indicated measurable eccentric insufficiency. The left ventricle presented thicknesses with linear contour and was not dilated nor restricted. The myocardium presented normal echogenicity without subjective evidence of significant fibrotic or ischemic disease. Contractility of the ventricular walls was adequate and in normal range for this patient evidenced by the fractional shortening measurement and subjective evaluation of the different regions of the myocardium. The left ventricular outflow tract demonstrated normal laminar flow and subjective structural integrity. The right atrium and auricle revealed normal size, structure and content. No evidence of masses was noted or chamber overload. Tricuspid valvular assessment demonstrated mild thickening with mild TR on Doppler. The right ventricle was of normal size (1/3 diameter of LV), chordae structure, myocardial echogenicity and thickness. Pulmonic tract assessment revealed normal valve structure, laminar flow, and diameter (approx. 1:1 pa/ao ratio). No visible pericardial or free pleura fluid was noted. No echographically detectable evidence of infiltrative disease was visible. The cranial mediastinum and pericardial regions were free of masses in the visible window.

INTERPRETED BY

 R. McKenzie Daniel,
 DVM, DABVP
 (Canine and Feline)

IMAGING PERFORMED BY

Diane McFadden

HOSPITAL NAME

 Legacy Animal
 Hospital

REFERRING VET

Dr. Potenzzone

ULTRASONOGRAPHIC FINDINGS
Primary

- Chronic mitral valve disease (ACVIM B1)
- Mild elevated MR velocity
- Mild TR – no evidence of clinical pulmonary hypertension

INVOICE

11587ag

DATE

09/09/2022



PATIENT

Bella Oscamoa

INTERPRETATION OF THE FINDINGS & FURTHER RECOMMENDATIONS

SPECIES

Canine

The cause of the murmur is chronic degenerative valvular changes with secondary eccentric MR and mild TR. The lack of left atrial enlargement implies that the risk of complication secondary to mitral valve insufficiency is low at this time and, without current clinical signs, indicates that medical therapy is not required. Conservative monitoring is recommended with a recheck echocardiogram in 6 months, sooner if clinical signs suggestive of heart disease develop. Assessment of systemic BP recommended given the increased MR velocity.

BREED

Chihuahua

Assuming normal BP, no overt anesthetic contraindications.

SEX

Suggested anesthetic protocol may include opioid or Benzodiazepine pre-med, induction with Propofol or Alfaxalone, and appropriate gas anesthesia with avoidance of alpha 2 agonists.

FS

AGE

13yr

WEIGHT

6.2lb

INTERPRETED BY

R. McKenzie Daniel,
DVM, DABVP
(Canine and Feline)

IMAGING PERFORMED BY

Diane McFadden

HOSPITAL NAME

Legacy Animal Hospital

REFERRING VET

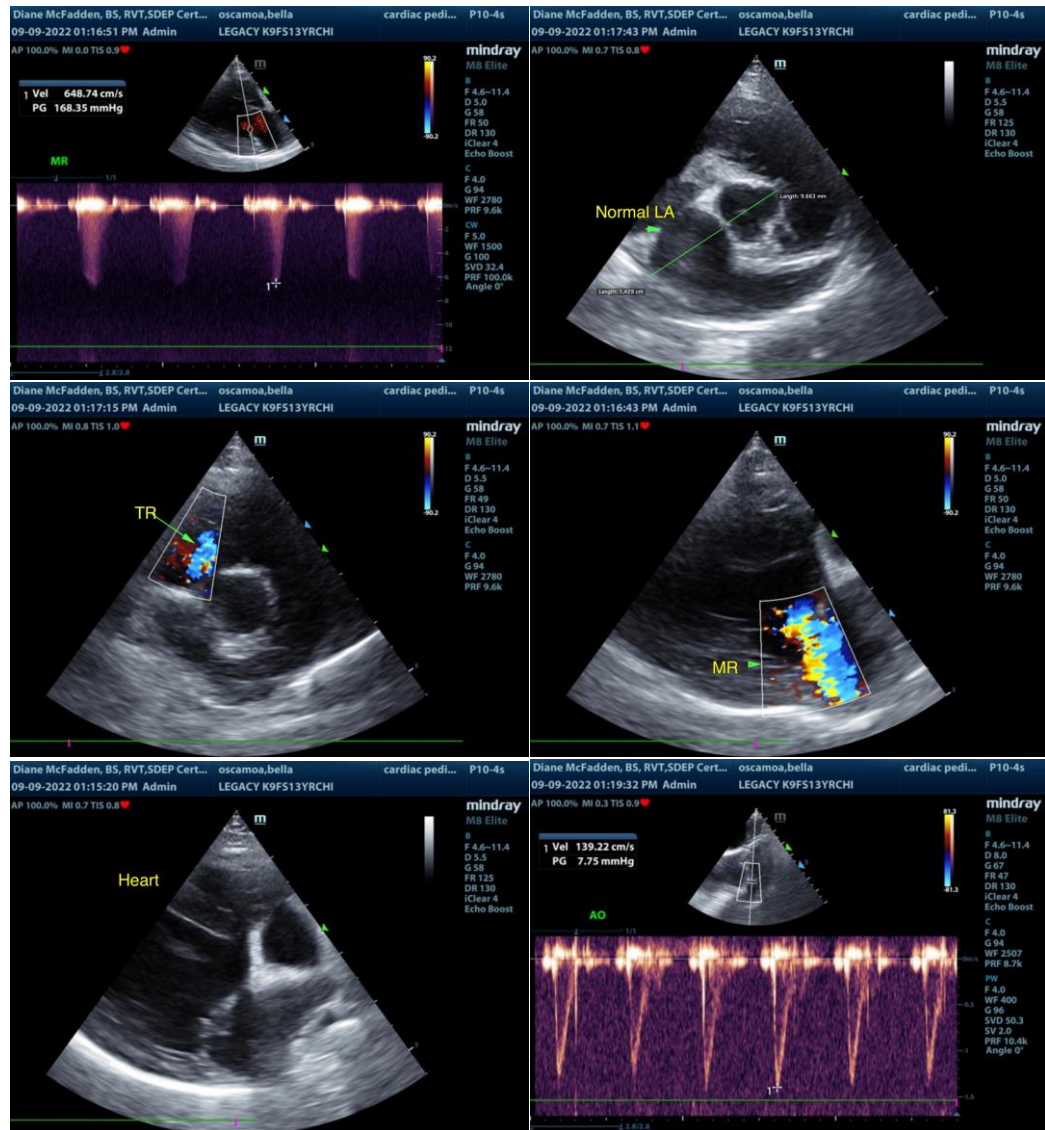
Dr. Potenzone

INVOICE

11587ag

DATE

09/09/2022



The information and recommendations provided are based on the images presented by the referring



PATIENT

Bella Oscamoa

veterinarian/sonographer. No evaluation can be communicated regarding pathology that was not visible in the image/video clips provided.

Thank you for this referral. If the clinical or image interpretation does not parallel your findings or if I can be of any further assistance please contact me.

SPECIES

Canine

R. McKenzie Daniel, DVM, DABVP (Canine / Feline Practice)

info@SonoPath.com

BREED

Chihuahua

SEX

FS

AGE

13yr

WEIGHT

6.2lb

INTERPRETED BY

R. McKenzie Daniel,
DVM, DABVP
(Canine and Feline)

**IMAGING
PERFORMED BY**

Diane McFadden

HOSPITAL NAME

Legacy Animal
Hospital

REFERRING VET

Dr. Potenzzone

INVOICE

11587ag

DATE

09/09/2022