



PATIENT

Sabrina Hall

SPECIES

Feline

BREED

DMH

SEX

Female (not specified if spayed)

AGE

2 years

WEIGHT

8.6 lbs.

INTERPRETED BY

R. McKenzie Daniel,
DVM, DABVP
(Canine and Feline)

IMAGING PERFORMED BY

Jessica Miller

HOSPITAL NAME

Ho Ho Kus Vet

REFERRING VET

Dr. Scott

INVOICE

12198

DATE

9/8/21

PRESENTING CLINICAL SIGNS

-Grade II heart murmur, needs dental. Current meds: lactulose, benefiber, miralax

ULTRASONOGRAPHIC EXAMINATION OF THE HEART

FELINE CARDIAC PARAMETERS	BODY WEIGHT (kg)	HR (BPM)	IVSd (cm)	LVIDd (cm)	LVWd (cm)	FS (%)	EF (%)
NORMAL PARAMETER	-----	150-240	0.3-0.6	1.0-2.1	0.25-0.6	35-67	80-100
PATIENT		237	0.41	1.34	0.41	53.7	88.6
FELINE CARDIAC PARAMETERS	LA/AO (Boon)	LA/AO HEART BASE (Sisson)	LA 2D 4-chamber long axis AS to FW (Sisson) (cm)	LVOT VEL. (m/s)	RVOT VEL. (m/s)	IVRT (m/)	
NORMAL PARAMETER	<1.5	0.88-1.79	0.7-1.7	<1.6	<1.3	40-60	
PATIENT		1.2	1.1	1.1	0.9	NM	
Adapted from June Boon, Veterinary Echocardiography, 1998 Sisson D et al. JVIM 1991; 5: 232, Jacobs et al. Am J Vet Res 1985; 46:1705							

Cardiac Presentation

The echocardiogram in this patient demonstrated normal **left atrial** size based on 3 separate LA measurements. The cranial and caudal **mitral** valve leaflets presented normal linear structure and kinetics. The **left ventricle** presented normal thicknesses with linear contour and was not dilated nor restricted. The **myocardium** presented normal echogenicity without subjective evidence of significant fibrotic or ischemic disease. **Contractility** of the ventricular walls was adequate and in normal range for this patient evidenced by the fractional shortening measurement and subjective evaluation of the different regions and angles of the myocardium. The **left ventricular outflow** tract demonstrated normal laminar flow and subjective structural integrity. The **right atrium** and auricle revealed normal size, structure and content. No evidence of masses was noted or chamber overload. **Tricuspid** valvular assessment demonstrated adequate linear morphology and kinetics. The **right ventricle** was of normal size (1/3 diameter of LV), chordae structure, myocardial echogenicity and thickness. **Pulmonic** tract assessment revealed normal valve structure, laminar flow, and diameter (approx. 1:1 pa/ao ratio). No visible **pericardial** or free pleura fluid was noted or extra cardiac pathology in the visible planes. The cranial **mediastinum and pericardial regions** were free of masses in the visible window.

ULTRASONOGRAPHIC FINDINGS

Primary Findings

- Overtly normal cardiac structure and function



PATIENT

Sabrina Hall

SPECIES

Feline

BREED

DMH

SEX

Female (not specified if spayed)

AGE

2 years

WEIGHT

8.6 lbs.

INTERPRETED BY

R. McKenzie Daniel, DVM, DABVP (Canine and Feline)

IMAGING PERFORMED BY

Jessica Miller

HOSPITAL NAME

Ho Ho Kus Vet

REFERRING VET

Dr. Scott

INVOICE

12198

DATE

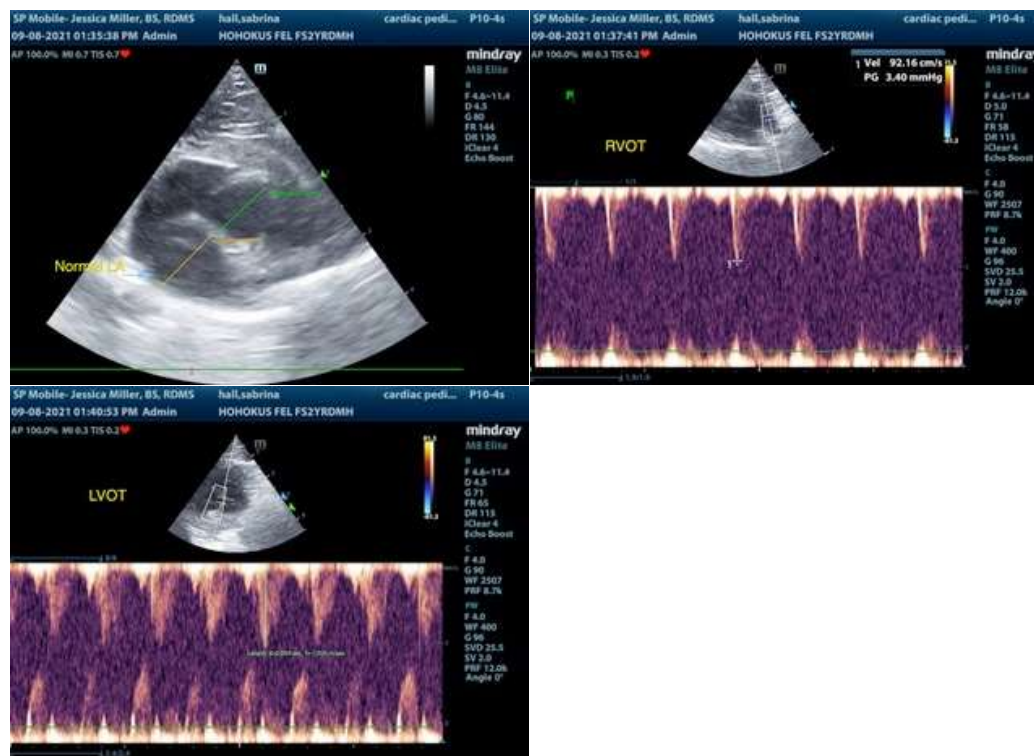
9/8/21

INTERPRETATION OF THE FINDINGS & FURTHER RECOMMENDATIONS

An obvious cause of the murmur was not definitively evident in this study. In the absence of structural or functional cardiomyopathy and assuming no significant volume changes i.e., dehydration or anemia, suspected benign physiologic / flow murmur is likely. However, the possibility of a very small flow abnormality such as small VSD not seen here cannot be definitively excluded yet is considered less likely. No evidence of a large shunt, significant valvular insufficiencies or stenosis were noted.

Given these findings, no indication for cardiac medications, nor anesthetic contraindications.

Continued monitoring of the murmur would be appropriate at this time with recheck echocardiogram suggested in 9-12 months if the murmur persists, sooner if the murmur increased in intensity.



The information and recommendations provided are based on the images presented by the referring veterinarian. No evaluation can be communicated regarding pathology that was not visible in the image/video clips provided.

Thank you for this referral. If the clinical or image interpretation does not parallel your findings or if I can be of any further assistance please contact me.

R. McKenzie Daniel, DVM, DABVP (Canine / Feline Practice)
info@SonoPath.com