



PATIENT PRESENTING CLINICAL SIGNS

Puma Williams History: congested and vomiting

SPECIES Abnormal PE/Chem/CBC/UA Results:

Feline

BREED

Bengal

SEX

Spayed Female

AGE

2 Years

WEIGHT

11 Pounds

ULTRASONOGRAPHIC EXAMINATION OF THE HEART & ABDOMEN

FELINE CARDIAC PARAMETERS	BODY WEIGHT (kg)	HR (BPM)	IVSd (cm)	LVIDd (cm)	LVWd (cm)	FS (%)	EF (%)
NORMAL PARAMETER	-----	150-240	0.3-0.6	1.0-2.1	0.25-0.6	35-67	80-100
PATIENT	--	NM	0.46	1.68	0.38	54.2	89
FELINE CARDIAC PARAMETERS	LA/AO (Boon)	LA/AO HEART BASE (Sisson)	LA 2D 4-chamber long axis AS to FW (Sisson) (cm)	LVOT VEL. (m/s)	RVOT VEL. (m/s)	IVRT (m/)	
NORMAL PARAMETER	<1.5	0.88-1.79	0.7-1.7	<1.6	<1.3	40-60	
PATIENT	--	1.1	1.4	1.0	0.8	NM	

Adapted from June Boon, Veterinary Echocardiography, 1998
Sisson D et al. JVIM 1991; 5: 232, Jacobs et al. Am J Vet Res 1985; 46:1705

INTERPRETED BY *Cardiac Presentation*

R. McKenzie Daniel,
DVM, DABVP
(Canine and Feline)

IMAGING PERFORMED BY

Jenn

HOSPITAL NAME

Rockaway AH

REFERRING VET

Dr. Maniar

INVOICE

12950

DATE

9/8/21

The echocardiogram in this patient demonstrated normal **left atrial** size based on 3 separate LA measurements. The cranial and caudal **mitral** valve leaflets presented normal linear structure and kinetics. The **left ventricle** presented normal thicknesses with linear contour and was not dilated nor restricted. The **myocardium** presented normal echogenicity without subjective evidence of significant fibrotic or ischemic disease. **Contractility** of the ventricular walls was adequate and in normal range for this patient evidenced by the fractional shortening measurement and subjective evaluation of the different regions and angles of the myocardium. The **left ventricular outflow** tract demonstrated normal laminar flow and subjective structural integrity. The **right atrium** and auricle revealed normal size, structure and content. No evidence of masses was noted or chamber overload. **Tricuspid** valvular assessment demonstrated adequate linear morphology and kinetics. The **right ventricle** was of normal size (1/3 diameter of LV), chordae structure, myocardial echogenicity and thickness. **Pulmonic** tract assessment revealed normal valve structure, laminar flow, and diameter (approx. 1:1 pa/ao ratio). No visible **pericardial** or free pleura fluid was noted or extra cardiac pathology in the visible planes. The cranial **mediastinum and pericardial regions** were free of masses in the visible window.

Urinary System

The urinary bladder, trigone, cystourethral junction, and visible pelvic urethra to a depth of 2.0 cm exhibited normal thickness and tone. Primarily anechoic urine was present in the lumen. Minor non-dependent particulate sediment was present without evidence of calculus formation. The ureteral papillae were normal. The ureters were not visible which is normal. No evidence of inflammatory or neoplastic mural changes were noted. Aortic trifurcation was normal.



PATIENT	Normal size and margination were present in the kidneys. A normal 1:3 cortex / medulla ratio and normal corticomedullary definition were maintained. The echogenicity of the cortex was similar to or slightly less than normal liver parenchyma while the medulla echogenicity was hypoechoic to the cortex with no evidence of pelvic dilation. The left kidney measured 3.6 cm in length. The right kidney measured 3.6 cm in length.
Puma Williams	
SPECIES	Adrenal Glands
Feline	No overt pathology in the area of the right adrenal gland.
BREED	The left adrenal gland was uniform in size and contour with a uniformly hypoechoic parenchyma. The left adrenal gland measured 0.38 cm.
Bengal	
SEX	Spleen
Spayed Female	The spleen exhibited a finely textured and homogenous parenchyma which was hyperechoic to the liver and renal cortical parenchyma. The capsule was smooth and regular without apparent expansion. The splenic vasculature at the hilus was normal in volume with no evidence of congestion or thrombosis. Acute to chronic inflammatory, neoplastic, or benign parenchyma changes were not noted. The spleen measured 0.90 cm.
AGE	Liver
2 Years	The liver was subjectively normal in size, structure, and contour. The liver parenchyma was uniform and hypoechoic to the spleen with a mild coarse echotexture. The hepatic and portal vasculature were normal in appearance without signs of congestion. The gallbladder was non-distended in size with thin walls and primarily anechoic luminal content. The cystic and common bile ducts were normal.
WEIGHT	
11 Pounds	
INTERPRETED BY	Gastrointestinal
R. McKenzie Daniel, DVM, DABVP (Canine and Feline)	The stomach presented intact wall layering with a normal wall layer ratio. The lumen of the stomach was empty with no signs of ileus, obstruction or foreign material. The gastric body wall measured 0.24 cm.
IMAGING PERFORMED BY	The small intestine presented intact wall layering with 1:3 muscularis/mucosa ratio. The lumen of the small intestine was empty with no signs of ileus, obstruction or foreign material. The jejunum wall measured 0.25 cm.
Jenn	Normal visible colon wall layers were present with apparent formed feces in lumen.
HOSPITAL NAME	Pancreas
Rockaway AH	The parenchyma of the left limb, body and right limb of the pancreas presented isoechoic to the adjacent omental fat. A normal curvilinear capsule contour of the pancreas was present. The visible pancreatic duct was normal. No signs of active inflammation or neoplastic disease was evident.
REFERRING VET	Free Abdomen
Dr. Maniar	No evidence of intrabdominal masses, lymphadenopathy or effusion.
INVOICE	ULTRASONOGRAPHIC FINDINGS
12950	<ul style="list-style-type: none"> • Normal echocardiogram • Sonographically unremarkable abdomen
DATE	
9/8/21	



PATIENT

- Minor particulate urinary bladder sediment- likely minor cellular or crystalline debris

Puma Williams

INTERPRETATION OF THE FINDINGS & FURTHER RECOMMENDATIONS

SPECIES

No evidence of cardiac or abdominal visceral pathology. Dietary indiscretion/food intolerance, parasitism or underlying inflammatory gastrointestinal process without evidence of mural changes possible in light of the vomiting. Potential for low grade pancreatic inflammation, which may present sonographically normal, is considered unlikely yet cannot be definitively excluded. Further assessment may include a GI panel to include PLI/TLI cobalamin/folate, especially if evidence of weight loss.

Feline

BREED

Limited antigen or hydrolyzed diet trial, broad spectrum deworming +/- heart worm antibody/antigen test may be considered. 3 view chest radiographs suggested to rule out thoracic or esophageal pathology as potential cause of the vomiting.

Bengal

SEX

Spayed Female

AGE

2 Years

WEIGHT

11 Pounds

INTERPRETED BY

R. McKenzie Daniel,
DVM, DABVP
(Canine and Feline)

IMAGING PERFORMED BY

Jenn

HOSPITAL NAME

Rockaway AH

REFERRING VET

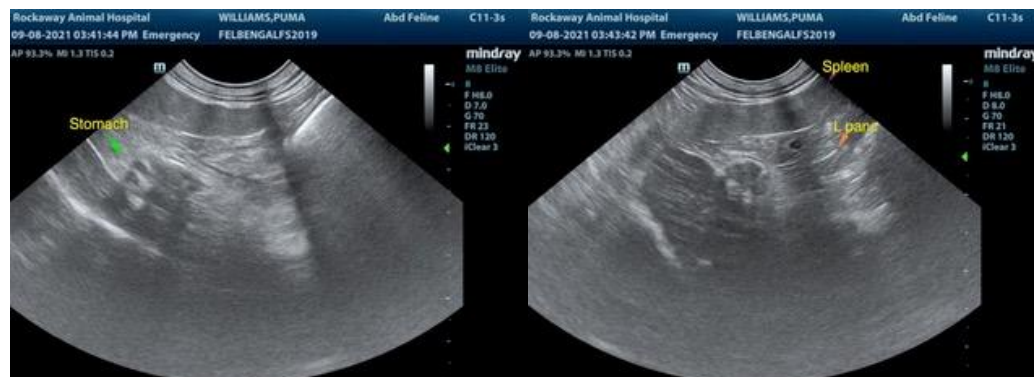
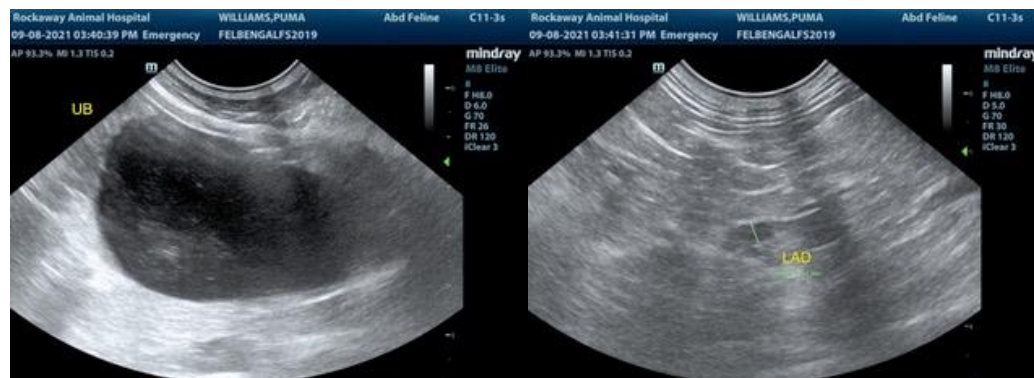
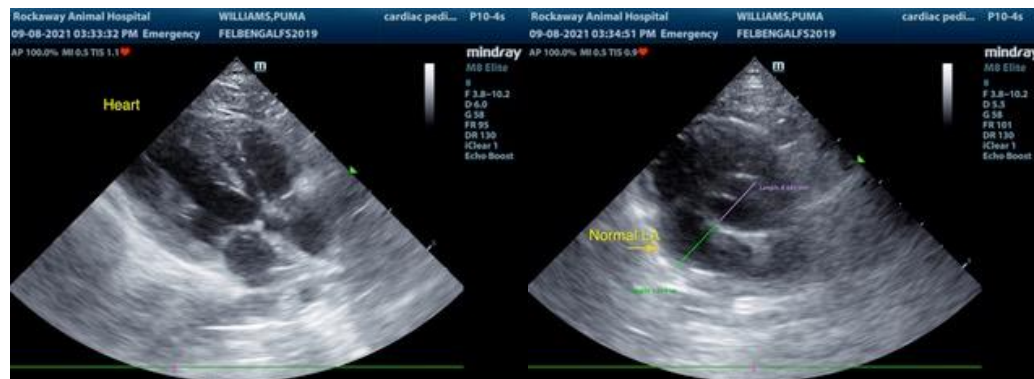
Dr. Maniar

INVOICE

12950

DATE

9/8/21





PATIENT

Puma Williams

SPECIES

Feline

BREED

Bengal

SEX

Spayed Female

AGE

2 Years

WEIGHT

11 Pounds

INTERPRETED BY

R. McKenzie Daniel,
DVM, DABVP
(Canine and Feline)

IMAGING PERFORMED BY

Jenn

HOSPITAL NAME

Rockaway AH

REFERRING VET

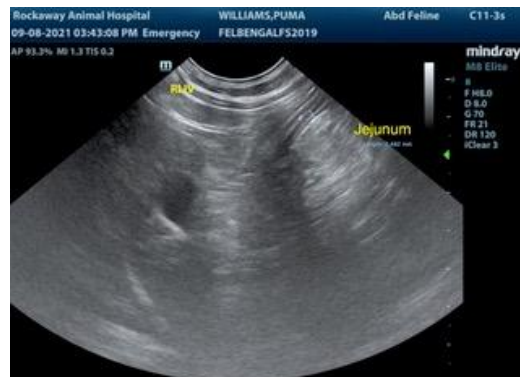Dr. Maniar

INVOICE

12950

DATE

9/8/21



The information and recommendations provided are based on the images presented by the referring veterinarian. No evaluation can be communicated regarding pathology that was not visible in the image/video clips provided.

Thank you for this referral. If the clinical or image interpretation does not parallel your findings or if I can be of any further assistance please contact me.

R. McKenzie Daniel, DVM, DABVP (Canine / Feline Practice)
info@SonoPath.com