



**PATIENT PRESENTING CLINICAL SIGNS**

**Kizer Lewis** 6/5/21: having trouble urinating and foul-smelling urine. Diarrhea. Rads: bladder very large, can not express it very easily or at all. Voided when picked up. Fecal - whipworms. Tx with drontal. Urine culture showed e-coli, tx w/ Doxycycline, enrofloxacin. Started Denamarin. 8/20/21: BCS 9/9, nsf on rectal exam. Recheck UA- lg amount cocci, protein 2+, pH 6, Sp. Grav. 1.006. RX: enrofloxacin, doxy, Denamarin. Rec. SAME. 9/1/21: owner reporting better with urination, but still urinating in home.

**SPECIES** Canine

**BREED** Dachshund

**SEX** Neutered Male

**AGE** 10 Years

**WEIGHT** 28

Abnormal PE/Chem/CBC/UA Results: 6/5/21: CBC: PLT 516 (170-400), increased monocytes. Chem: ALKP 1555 (5-131), GGT 16 (1-12), PHOS 6.5 (2-6.0), Precision PSL 284 (24-140), T4 1.3 (0.8-3.5).

**ULTRASONOGRAPHIC EXAMINATION OF THE ABDOMEN**

**Urinary System**

The urinary bladder was distended in size. Anechoic urine was present with moderate non-dependent, particulate sediment. No evidence of inflammatory or neoplastic mural criteria, and no evidence of calculi. The residual prostate was normal, measuring 0.76 cm diameter. The visible proximal urethra to a depth of 3.0 cm exhibited normal structure and tone.

Normal size and margination were present in the kidneys. A normal 1:3 cortex / medulla ratio was maintained. The medulla and cortices were uniform in texture with some increased echogenicity and mild loss of corticomedullary symmetry and definition expected for the age of the patient. No evidence of pelvic dilation was present. Pinpoint areas of medullary mineralization noted. No overt pyelonephritis. The right kidney measured 6.8 cm. The left kidney measured 6.4 cm.

The area of the aortic trifurcation was free of pathology.

**Adrenal Glands**

Bilateral symmetrical adrenal gland enlargement with mildly echogenic to non-homogeneous parenchyma. No evidence of mineralization or overt masses. The left adrenal gland measured 2.5 cm length x 0.95 cm at the caudal pole. The right adrenal gland measured 2.2 cm length x 0.79 cm.

**Spleen**

The spleen exhibited primarily finely textured parenchyma which was hyperechoic to the liver and renal cortical parenchyma. Mild generalized parenchyma heterogeneity was present without evidence of nodular changes. The capsule was smooth and regular without apparent expansion. The splenic vasculature at the hilus was normal in volume with no evidence of congestion or thrombosis. The parenchymal heterogeneity is likely consistent with benign changes such as extramedullary hematopoiesis or age related remodeling with minor potential for inflammatory or neoplastic disease.

**Liver**

The liver was mildly enlarged. The parenchyma of the liver presented mild uniform increase in echogenicity compared to the spleen and falciform fat. The echotexture of the liver parenchyma was uniform with a mild coarse echotexture. The capsule of the liver was symmetrical in margination. The hepatic and portal vasculature were normal in appearance without signs of congestion. The gallbladder exhibited subjective mild distention with moderate, non-dependent yet non-organized, echogenic debris was present. No evidence of post-hepatic obstruction. The cystic duct and common bile ducts were normal without evidence of dilation.

**Gastrointestinal**

The stomach presented intact wall layering with a normal wall layer ratio. The lumen of the stomach was empty with no signs of ileus, obstruction or foreign material.

**INTERPRETED BY**

R. McKenzie Daniel,  
DVM, DABVP  
(Canine and Feline)

**IMAGING PERFORMED BY**

Rachel Runnells, RVT

**HOSPITAL NAME**

SVS Imaging  
Kansas City

**REFERRING VET**

Dr. John Lyle

**INVOICE**

25250

**DATE**

9/8/21



**PATIENT**

Kizer Lewis

The small intestine presented intact wall layering with 1:3 muscularis/mucosa ratio. The lumen of the small intestine was empty with no signs of ileus, obstruction or foreign material.

Normal visible colon wall layers were present with apparent formed feces in lumen.

**SPECIES**

Canine

**Pancreas**

The pancreas was normal in size and contour with isoechoic to heterogeneous parenchyma compared to adjacent omentum. No signs of active inflammation or neoplasia.

**BREED**

Dachshund

**Free Abdomen**

No overt lymphadenopathy or peritoneal effusion was present.

**SEX**

Neutered Male

**ULTRASONOGRAPHIC FINDINGS**

- Distended urinary bladder with moderate non-dependent, particulate sediment
- Sonographically unremarkable residual prostate and visible proximal urethra
- Mild chronic renal changes with pinpoint medullary mineralization
- Mild hepatomegaly with mild increased parenchyma echogenicity
- Moderate non-organized gallbladder debris
- Bilateral mild adrenomegaly

**AGE**

10 Years

**WEIGHT**

28

**INTERPRETATION OF THE FINDINGS & FURTHER RECOMMENDATIONS**

The urinary bladder sediment is likely consistent with cellular or crystalline debris. If persistent UTI, a higher dose, shorter frequency antibiotic protocol (ideally based on culture and sensitivity results – i.e., Clavamox or Enrofloxacin 20 mg/kg PO SID for 3-5 days may prove more effective. Thorough neurological examination (if not done) is recommended given the distended urinary bladder and breed.

Vacuolar/steroid hepatopathy and cholestasis is suspected, while the possibility of inflammatory hepatobiliary disease (given the presence of gallbladder debris) is possible. No overt evidence of hepatic neoplasia. Full adrenal workup including LDDST is recommended if clinical suspicion of hyperadrenocorticism (given the sonographic findings) and thrombocytosis. Hepatosupportive medications including current Denamarin as well as Ursodiol are suggested.

**INTERPRETED BY**

R. McKenzie Daniel, DVM, DABVP (Canine and Feline)

**IMAGING PERFORMED BY**

Rachel Runnells, RVT

**HOSPITAL NAME**

SVS Imaging Kansas City

**REFERRING VET**

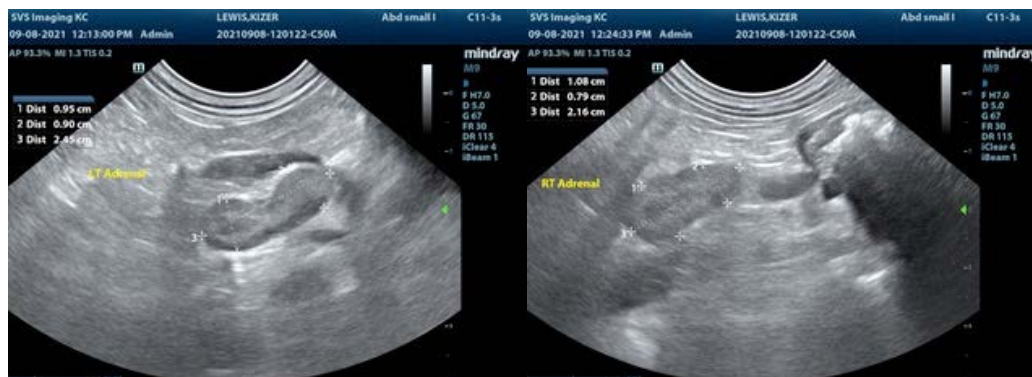Dr. John Lyle

**INVOICE**

25250

**DATE**

9/8/21





**PATIENT**

Kizer Lewis

**SPECIES**

Canine

**BREED**

Dachshund

**SEX**

Neutered Male

**AGE**

10 Years

**WEIGHT**

28

**INTERPRETED BY**

R. McKenzie Daniel,  
DVM, DABVP  
(Canine and Feline)

**IMAGING PERFORMED BY**

Rachel Runnells, RVT

**HOSPITAL NAME**

SVS Imaging  
Kansas City

**REFERRING VET**

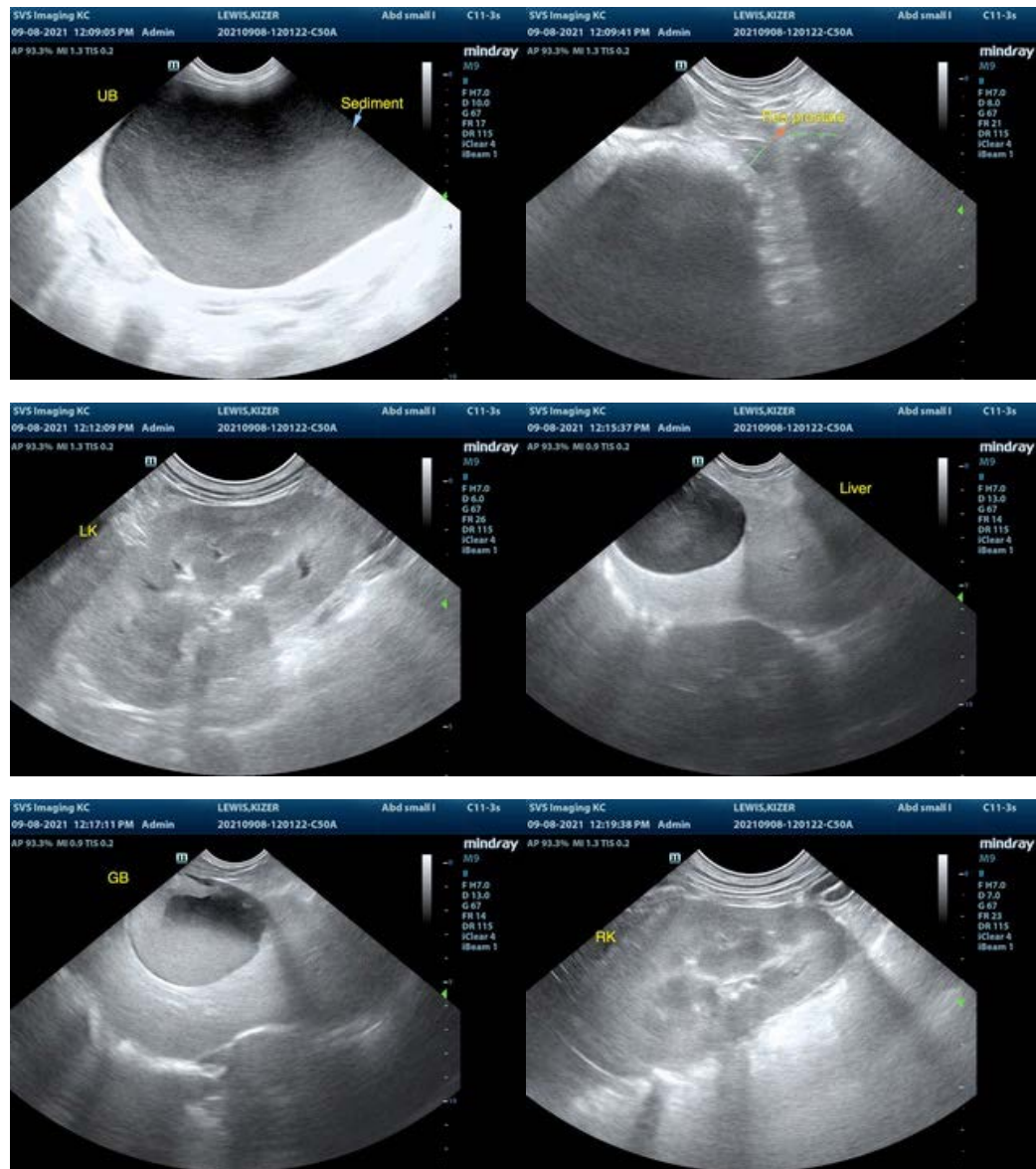
Dr. John Lyle

**INVOICE**

25250

**DATE**

9/8/21



The information and recommendations provided are based on the images presented by the referring veterinarian. No evaluation can be communicated regarding pathology that was not visible in the image/video clips provided.

Thank you for this referral. If the clinical or image interpretation does not parallel your findings or if I can be of any further assistance please contact me.

**R. McKenzie Daniel, DVM, DABVP (Canine / Feline Practice)**  
info@SonoPath.com