



PATIENT	PRESENTING CLINICAL SIGNS
Kitti Treon	Patient presents for ALT ALP elevations, appetite loss, weight loss and newly diagnosed hyperthyroidism.
SPECIES	ULTRASONOGRAPHIC EXAMINATION OF THE ABDOMEN
Feline	Urinary System
BREED	The urinary bladder, trigone, cystourethral junction, and visible pelvic urethra to a depth of - cm exhibited normal thickness and tone. Primarily anechoic urine was present in the lumen. Mild particulate, non-dependent sediment was present without evidence of calculus formation. The ureteral papillae were normal. The ureters were not visible which is normal. No evidence of inflammatory or neoplastic mural changes were noted.
DSH	
SEX	Normal size and margination were present in the kidneys. A normal 1:3 cortex / medulla ratio was maintained. The medulla and cortices were uniform in texture with some increased echogenicity and mild loss of corticomedullary symmetry and definition expected for the age of the patient. No evidence of pelvic dilation was present. The right kidney measured 3.8 cm. The left kidney measured 3.7 cm.
Spayed Female	
AGE	The area of the aortic trifurcation was free of pathology.
10 Years	Adrenal Glands
WEIGHT	The left adrenal gland was uniform in size and contour with a uniformly hypoechoic parenchyma. The left adrenal gland measured 0.27 cm in width. No overt pathology in the area of the right adrenal gland.
9.8 Pounds	Spleen
INTERPRETED BY	The spleen exhibited mild subjective enlargement, measuring 1.1-1.2 cm in width at the level of the mid spleen. Subtle asymmetrical medial capsule contour noted with primarily finely textured parenchyma which was hyperechoic to the liver and renal cortical parenchyma. Mild generalized parenchyma heterogeneity was present without evidence of nodular changes. No distinct masses. The splenic vasculature at the hilus was normal in volume with no evidence of congestion or thrombosis. The parenchymal heterogeneity is likely consistent with benign changes such as extramedullary hematopoiesis or age related remodeling with minor potential for inflammatory or neoplastic disease.
R. McKenzie Daniel, DVM, DABVP (Canine and Feline)	
IMAGING PERFORMED BY	Liver
Kelly Vazquez	The liver was subjectively normal in size, structure, and contour. The liver parenchyma was uniform and hypoechoic to the spleen with a moderate coarse echotexture. The hepatic and portal vasculature were normal in appearance without signs of congestion. The gallbladder was non-distended in size with thin walls and primarily anechoic luminal content. The cystic and common bile ducts were normal.
HOSPITAL NAME	Gastrointestinal
Englewood VC	The stomach presented intact wall layering with a normal wall layer ratio. The lumen of the stomach contained mild echogenic, nonshadowing ingesta most consistent with post prandial presentation without signs of ileus, obstruction or foreign material. Gastric body wall measured 0.25 cm.
REFERRING VET	
Dr. Ezik	
INVOICE	The small intestine presented intact wall layering with 1:3 muscularis/mucosa ratio. The lumen of the small intestine was empty with no signs of ileus, obstruction or foreign material. Duodenum wall measured 0.20 cm. Jejunum wall measured 0.20 cm.
25244	
DATE	Normal visible colon wall layers were present with apparent formed feces in lumen.
9/8/21	



PATIENT

Pancreas

Kitti Treon

The parenchyma of the left limb, body and right limb of the pancreas presented isoechoic to the adjacent omental fat. A normal curvilinear capsule contour of the pancreas was present. The visible pancreatic duct was normal. No signs of active inflammation or neoplastic disease was evident.

SPECIES

Free Abdomen

Feline

Several, mildly prominent to enlarged colic lymph nodes were present. The lymph node was essentially isoechoic to adjacent omentum without evidence of peripheral inflammation and maintaining a normal width: length ratio (<0.5). Example of lymph node measured 0.33 cm in width.

BREED

DSH

No effusion. Overall normal omental echogenicity.

SEX

ULTRASONOGRAPHIC FINDINGS

Spayed Female

- Mild age related kidneys
- Mild non-specific splenomegaly – patient variant, hyperplasia, hematopoiesis, or potential incidental splenitis suspected. Minor potential for emerging splenic neoplasia, although thought less likely.
- Benign hepatopathy
- Gastric ingesta with sonographically unremarkable bowel – post-prandial presentation versus minor potential for gastric hypomotility if documented NPO.
- Minor colic lymphadenopathy – subjectively benign, minor hyperplasia or potential reactive lymphadenitis likely.

AGE

10 Years

WEIGHT

9.8 Pounds

INTERPRETED BY

INTERPRETATION OF THE FINDINGS & FURTHER RECOMMENDATIONS

R. McKenzie Daniel,
DVM, DABVP
(Canine and Feline)

Given the patient's weight loss, ultrasound guided splenic FNA using 25-gauge needle may be considered for screening cytology, primarily to ensure only benign changes were present. The weight loss and elevated liver enzymes may be owing to recently diagnosed hyperthyroidism. Monitoring of weight as well as reassessment of liver enzymes following normalization of T4 levels recommended. Further assessment may include GI panel to include PLI, TLI, cobalamin and folate, and 3-view chest radiographs (if not done) to rule out occult thoracic pathology as potential causes of weight loss.

IMAGING PERFORMED BY

Kelly Vazquez

HOSPITAL NAME

Englewood VC

REFERRING VET

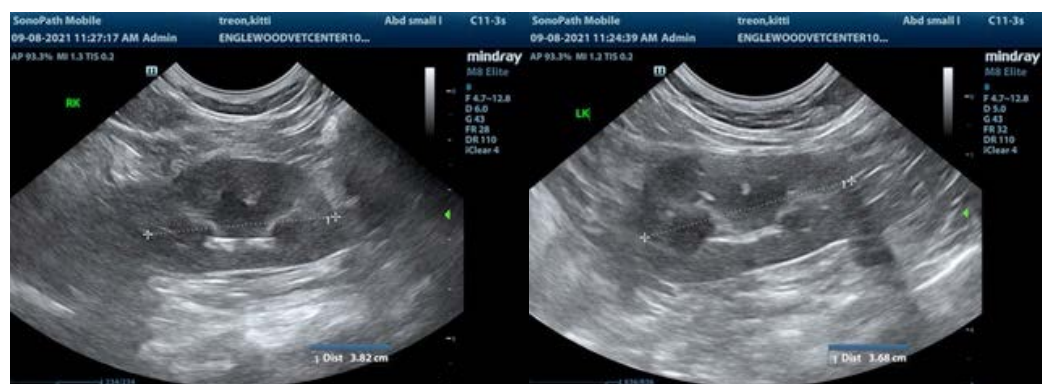
Dr. Ezik

INVOICE

25244

DATE

9/8/21





PATIENT

Kitti Treon

SPECIES

Feline

BREED

DSH

SEX

Spayed Female

AGE

10 Years

WEIGHT

9.8 Pounds

INTERPRETED BY

R. McKenzie Daniel,
DVM, DABVP
(Canine and Feline)

IMAGING PERFORMED BY

Kelly Vazquez

HOSPITAL NAME

Englewood VC

REFERRING VET

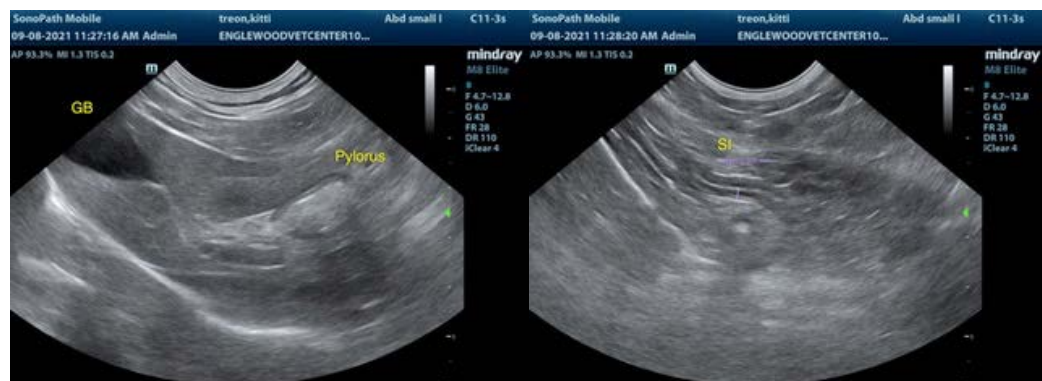
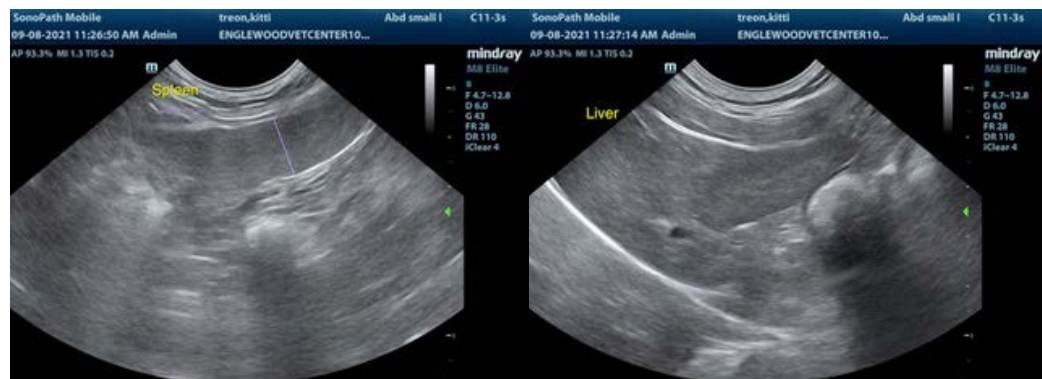
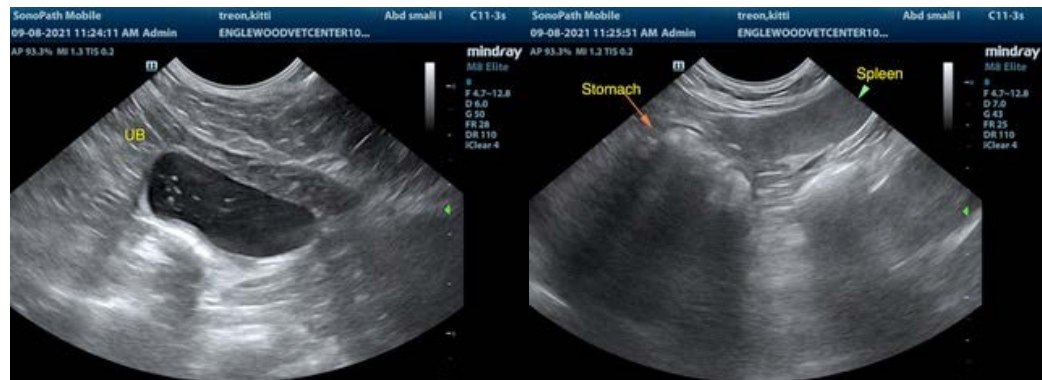
Dr. Ezik

INVOICE

25244

DATE

9/8/21



The information and recommendations provided are based on the images presented by the referring veterinarian. No evaluation can be communicated regarding pathology that was not visible in the image/video clips provided.

Thank you for this referral. If the clinical or image interpretation does not parallel your findings or if I can be of any further assistance please contact me.

R. McKenzie Daniel, DVM, DABVP (Canine / Feline Practice)
info@SonoPath.com