SonoPath
Clinical Sonography & Telecytology
EDUCATIONAL TELECONSULTATION SERVICES™

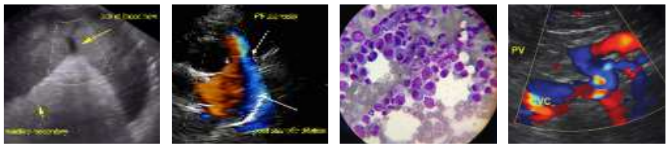

SonoPath.com™
1-800-838-4268 info@sonopath.com

PATIENT
Dash Albers

SPECIES
Canine

BREED
Poodle Mix

SEX
Neutered Male

AGE
4 years

WEIGHT
37 lbs.

INTERPRETED BY
R. McKenzie Daniel, DVM, DABVP (Canine and Feline)

IMAGING PERFORMED BY
Rachel Runnells, RVT

HOSPITAL NAME
SVS Imaging Kansas City

REFERRING VET
Dr. Holly Smith

INVOICE
12190

DATE
9/8/21

PRESENTING CLINICAL SIGNS

Has been steadily losing weight for approximately 2-3 months. Appetite has decreased substantially and now is vomiting some water. No diarrhea or coughing seen.

Abnormal PE/Chem/CBC/UA Results: Emaciated. no fever. 9-10% dehydrated. pale MM. heart rate of 180 bpm. Abdomen is doughy and intestines seem dilated. radiographs showed an elevation of the heart due to dehydration, consistent dilation of the small and large intestine. cbc shows a HCT of 31 with all other parameters wnl. chemistry shows a BUN of 111, creat 3.9, phos 9.6, potassium 9.9, alp 15. Placed on fluids overnight. Began cerenia, ampicillin.

ULTRASONOGRAPHIC EXAMINATION OF THE ABDOMEN

Urinary System

The urinary bladder, trigone, cystourethral junction, and visible pelvic urethra to a depth of 2.0 cm exhibited normal thickness and tone. Anechoic urine was present in the lumen with no uroliths or sediment. The ureteral papillae were normal. The ureters were not visible which is normal. No evidence of inflammatory or neoplastic changes was noted.

The residual prostate was symmetrically normal in size with uniform parenchyma and slight coarse echotexture measuring 1.0 cm in diameter.

The area of the aortic trifurcation was free of pathology.

Normal size and margination were present in the kidneys. A normal 1:3 cortex / medulla ratio and normal corticomedullary definition were maintained. The echogenicity of the cortex was similar to or slightly less than normal liver parenchyma while the medulla echogenicity was hypoechoic to the cortex with no evidence of pelvic dilation. The left kidney measured 6.0 cm in length. The right kidney measured 6.2 cm in length.

Adrenal Glands

The left and right adrenal glands exhibited mild subnormal size compared to expected adrenal size in light of body weight. The left adrenal gland measured 0.25 cm width at the caudal pole and 0.38 cm width at the cranial pole. The right adrenal gland measured 0.30 cm width at the caudal pole and 0.30 cm width at the cranial pole.

Spleen

The spleen exhibited a finely textured and homogenous parenchyma which was hyperechoic to the liver and renal cortical parenchyma. The capsule was smooth and regular without apparent expansion. The splenic vasculature at the hilus was normal in volume with no evidence of congestion or thrombosis. Acute to chronic inflammatory, neoplastic, or benign parenchyma changes were not noted.

Liver/ Gallbladder

The liver was subjectively normal in size, structure, and contour. The liver parenchyma was uniform and hypoechoic to the spleen with a mild coarse echotexture. The hepatic and portal vasculature were normal in appearance without signs of congestion. The gallbladder was non-distended in size with thin walls and primarily anechoic luminal content. The cystic and common bile ducts were normal.

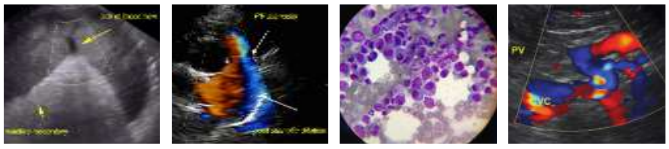

SonoPath.com™
1-800-838-4268 info@sonopath.com

PATIENT

Dash Albers

SPECIES

Canine

BREED

Poodle Mix

SEX

Neutered Male

AGE

4 years

WEIGHT

37 lbs.

INTERPRETED BY

R. McKenzie Daniel, DVM, DABVP (Canine and Feline)

IMAGING PERFORMED BY

Rachel Runnells, RVT

HOSPITAL NAME

SVS Imaging Kansas City

REFERRING VET

Dr. Holly Smith

INVOICE

12190

DATE

9/8/21

Gastrointestinal

The stomach presented intact yet subjective mild prominent wall layering. The stomach was primarily empty with mild luminal gas, primarily in the area of the gastric antrum and pylorus. The gastric body wall width measured 0.60 cm.

The small intestine exhibited intact wall layering and maintained a 1:3 muscularis/mucosa ratio. The small intestine was primarily empty with a segmental nonobstructive gas pattern. The jejunum wall width measured 0.22 cm. The duodenum wall width measured 0.40 cm.

Normal visible colon wall layers were present with apparent formed feces in lumen.

Pancreas

The parenchyma of the left limb, body, and right limb of the pancreas presented isoechoic to the adjacent omental fat. A normal curvilinear capsule contour of the pancreas was present. The visible pancreatic duct was normal. No signs of active inflammation or neoplastic disease were evident.

Free Abdomen

No overt lymphadenopathy or peritoneal effusion was present.

ULTRASONOGRAPHIC FINDINGS

Primary Findings

- Sonographically unremarkable bilateral kidneys
- Intact normal gastrointestinal wall layering with mild gastric and segmental small bowel gas - suspect mild gastroenteritis, no evidence of mechanical gastrointestinal obstruction or foreign material

INTERPRETATION OF THE FINDINGS & FURTHER RECOMMENDATIONS

Given the patient's clinical signs, degree of azotemia in light of sonographically unremarkable kidneys, as well as the degree of hyperkalemia in the face of subjective subnormal adrenal glands, hypoadrenocorticism may be considered a primary differential diagnosis in this case. ACTH stimulation test is recommended for further assessment. Correlation with urinalysis is recommended to assess for prerenal vs. renal azotemia. If hypoadrenocorticism is ruled out, the potential for a nonspecific gastrointestinal or renal disease may be present and additional diagnostics i.e., urine culture and sensitivity, Leptospirosis titers, endoscopic gastrointestinal biopsies, or a GI panel to assess serum cobalamin and folate levels may be indicated. Pending additional diagnostics, continued supportive care is suggested.

SonoPath

Clinical Sonography & Telecytology

EDUCATIONAL TELECONSULTATION SERVICES™

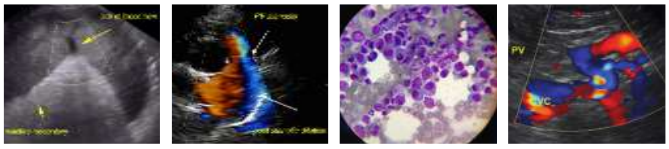

SonoPath.com™

1-800-838-4268 info@sonopath.com

PATIENT

Dash Albers

SPECIES

Canine

BREED

Poodle Mix

SEX

Neutered Male

AGE

4 years

WEIGHT

37 lbs.

INTERPRETED BY

R. McKenzie Daniel, DVM, DABVP (Canine and Feline)

IMAGING PERFORMED BY

Rachel Runnells, RVT

HOSPITAL NAME

SVS Imaging Kansas City

REFERRING VET

Dr. Holly Smith

INVOICE

12190

DATE

9/8/21

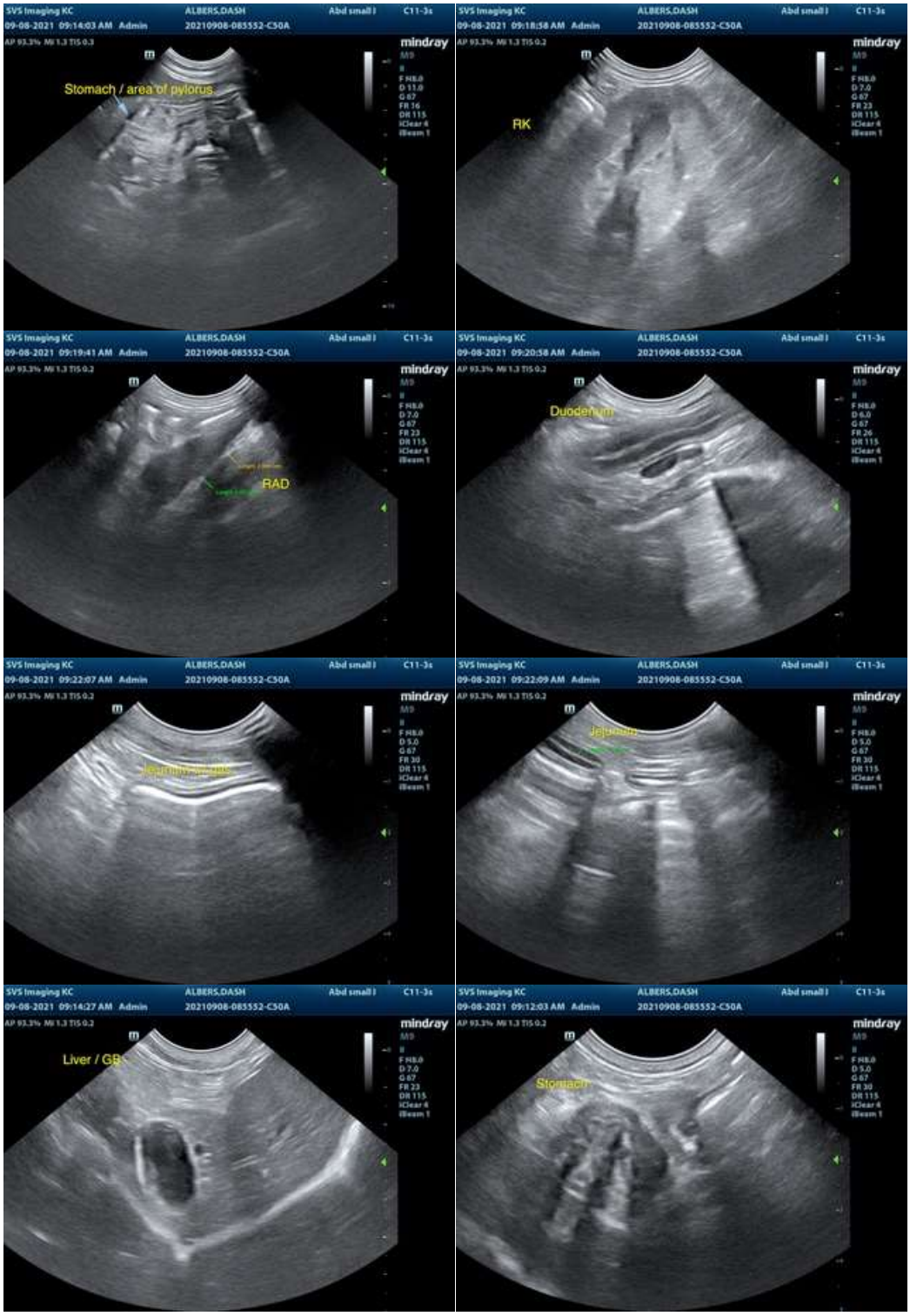

SonoPath

Clinical Sonography & Telecytology

EDUCATIONAL TELECONSULTATION SERVICES™

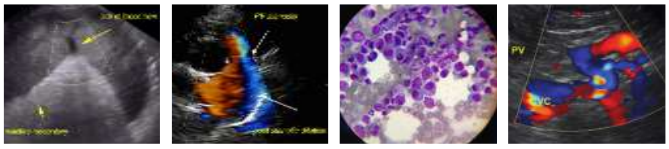

SonoPath.com™
1-800-838-4268 info@sonopath.com

PATIENT

Dash Albers

SPECIES

Canine

BREED

Poodle Mix

SEX

Neutered Male

AGE

4 years

WEIGHT

37 lbs.

INTERPRETED BY

R. McKenzie Daniel, DVM, DABVP (Canine and Feline)

IMAGING PERFORMED BY

Rachel Runnells, RVT

HOSPITAL NAME

SVS Imaging Kansas City

REFERRING VET

Dr. Holly Smith

INVOICE

12190

DATE

9/8/21

The information and recommendations provided are based on the images presented by the referring veterinarian. No evaluation can be communicated regarding pathology that was not visible in the image/video clips provided.

Thank you for this referral. If the clinical or image interpretation does not parallel your findings or if I can be of any further assistance please contact me.

R. McKenzie Daniel, DVM, DABVP (Canine / Feline Practice)
info@SonoPath.com